



## Discover Generics

Cost-Effective CT & MRI Contrast Agents



FRESENIUS  
KABI

WATCH VIDEO

# AJNR

## Odontogenic cysts: improved imaging with a dental CT software program.

J J Abrahams and P J Oliverio

*AJNR Am J Neuroradiol* 1993, 14 (2) 367-374

<http://www.ajnr.org/content/14/2/367>

This information is current as  
of June 23, 2025.

# Odontogenic Cysts: Improved Imaging with a Dental CT Software Program

James J. Abrahams<sup>1</sup> and Patrick J. Oliverio<sup>1</sup>

**PURPOSE:** To evaluate a dental CT software program to determine whether it can provide a better means of assessing odontogenic cysts, lesions of the jaw derived from dental epithelium, than conventional techniques (orthopantomographic, intraoral, and mandibular films), which are of limited usefulness because of the curved configuration of the mandible; and to provide a brief review of these lesions. **METHODS:** Nine odontogenic cysts were studied with conventional radiographs and with the software program, which displays multiple cross-referenced axial, panoramic, and cross-sectional (unique to this program) views of the mandible. The two modalities were compared for delineation of anatomy (inferior alveolar canal, mandibular foramen, mental foramen), detection of neurovascular bundle displacement, detection of cortical bone involvement, and detection of root involvement. **RESULTS:** The software program rated higher regarding all four points. It was found to be superior for delineating anatomy and detecting mandibular canal displacement and cortical and root involvement. **CONCLUSIONS:** This software program should be the study of choice when evaluating odontogenic cysts and other lesions of the mandible.

**Index terms:** Computed tomography, technique; Mandible, cysts; Computed tomography, software

AJNR 14:367–374, Mar/Apr 1993

Odontogenic cysts are lesions of the jaw that are derived from dental epithelium. The classification of these lesions has undergone change in the recent decades. Presently, the most widely accepted and straightforward classification (1) divides these lesions into the following six types: dentigerous cysts, radicular cysts, lateral periodontal cysts, gingival cysts, odontogenic keratocysts, and calcifying odontogenic keratocysts. Although these lesions are histologically benign, some may be locally aggressive or clinically persistent. Achieving a correct diagnosis and a clear radiographic delineation of the cyst's extent can significantly alter the treatment plan and surgical approach. Determining the position of the neurovascular bundle in relation to the lesion is also important. Recent attempts have therefore been made to improve the radiographic assessment of these lesions.

Typically, odontogenic cysts are studied in the dentist's office using orthopantomographic, intraoral, and mandibular films. These screening exams are excellent but fail to provide the detailed information necessary for appropriate management. They do not demonstrate internal anatomy or the position of the lesion in relation to the neurovascular bundle and cortical bone margins. Magnetic resonance, which provides excellent soft-tissue contrast, is suboptimal for assessing osseous changes including cortical margins. It is not surprising then that computed tomography (CT) has been helpful in studying odontogenic cysts (2–4). Axial CT improves tissue contrast and provides better delineation of the cortical margins and internal structure of the mandible. It does not, however, clearly delineate the vertical height of the buccal or lingual surfaces or the neurovascular bundle since these structures run parallel to the plane of the axial scan. Attempts at direct coronal CT have not met with success because of the degree of hyperextension required of the patient and the image degradation created by metallic dental material.

To improve the radiographic assessment of these lesions, we have utilized a dental CT soft-

---

Received October 31, 1991; revision requested February 6, 1992; revision received June 8 and accepted July 21.

<sup>1</sup> Department of Diagnostic Radiology, Yale University School of Medicine, 333 Cedar Street, New Haven, CT 06510. Address reprint requests to James J. Abrahams.

AJNR 14:367–374, Mar/Apr 1993 0195-6108/93/1402-0367  
© American Society of Neuroradiology



TABLE 1: Results: conventional films vs DentaScan

Case No.	Anatomy		Mandibular Canal Displacement		Cortical Involvement		Root Involvement	
	C	DS	C	DS	C	DS	C	DS
1. Calcifying odontogenic cyst	1	4	1	4	2	4	3	4
2. Odontogenic keratocyst	2	4	1	4	1	4	NA <sup>b</sup>	NA <sup>b</sup>
3. Odontogenic keratocyst	2	4	1	4	2	4	3	3
4. Dentigerous cyst	2	4	NA <sup>a</sup>	NA <sup>a</sup>	1	4	2	4
5. Radicular cyst	2	4	2	4	2	4	3	3
6. Dentigerous cyst	2	4	1	4	1	4	1	4
7. Radicular cyst	2	4	NA <sup>a</sup>	NA <sup>a</sup>	2	4	3	3
8. Radicular cyst	3	4	1	4	3	4	3	3
9. Radicular cyst	2	4	2	4	2	4	3	3

Note.—C = conventional films; DS = DentaScan; 1 = poor; 2 = fair; 3 = good; 4 = excellent.

<sup>a</sup> Lesion medial to mandibular canal.

<sup>b</sup> Edentulous in region of lesion.

ware program that was originally developed to evaluate patients considering osseointegrated dental implants (5–8) (metallic screw-like devices that are surgically implanted in the mandible to permit permanent fixation of dentures). The program uses the axial scans to reformat systematically multiple cross-referenced panoramic and cross-sectional images. The panoramic views are reformatted parallel to a curved line superimposed on the axial image of the mandible; the cross-sectional images are reformatted along numbered lines drawn perpendicular to this (see Figs. 2 and 3). In this fashion the mandibular canal and cortical margins are clearly delineated. To assess the value of this program, we imaged nine odontogenic cysts and compared the images with the conventional films. Our findings and a discussion of odontogenic cysts follow.

## Methods

Nine proven odontogenic cysts of the mandible were evaluated with conventional radiographs (orthopantomographic, intraoral, and/or mandibular films) and the dental CT software program (DentaScan, GE Medical, Milwaukee, WI). The images from the two modalities were viewed separately and then simultaneously by a neuroradiologist with expertise in this area. Films were evaluated for delineation of anatomy (inferior alveolar canal, mandibular foramen, mental foramen), detection of neurovascular bundle (inferior alveolar canal) displacement, detection of cortical involvement, and detection of root involvement. A grading scale of 1 through 4 was used in which 1 = poor, 2 = fair, 3 = good, and 4 = excellent.

Image data for the software program was acquired on a GE 9800 CT scanner using a dynamic mode and bone algorithm. Axial sections were acquired parallel to the alveolar ridge of the mandible. One and one half millimeter

sections were obtained every millimeter, resulting in a 0.5-mm overlap.

## Results

The nine lesions studied included one calcifying odontogenic cyst, two odontogenic keratocysts, two dentigerous cysts, and four radicular cysts. When the two modalities were compared, DentaScan was found to be superior for delineating anatomy and detecting mandibular canal displacement, cortical involvement, and root involvement. Results are summarized in Table 1 and described below.

### *Delineation of Anatomy (Mandibular Canal, Mandibular Foramen, and Mental Foramen)*

The mental foramen and inferior alveolar canal were seen on the plain films but they were visualized more clearly on the DentaScan images. This is illustrated by comparing the plane film of the calcifying odontogenic cyst (Fig. 1A) to the DentaScan (Figs. 1C and 1D). Note how the cross-sectional DentaScan images demonstrate the canal and establish its position in relation to the lesion. Mandibular foramina were seen only on the DentaScan images (Fig. 2D).

### *Detection of Neurovascular Bundle (Mandibular Canal) Displacement*

Neurovascular bundle displacement was extremely difficult to visualize on plain films. The plain films also were unable to determine the position of the canal in relation to the lesion (Figs. 1A and 3A). The cross-sectional DentaScan



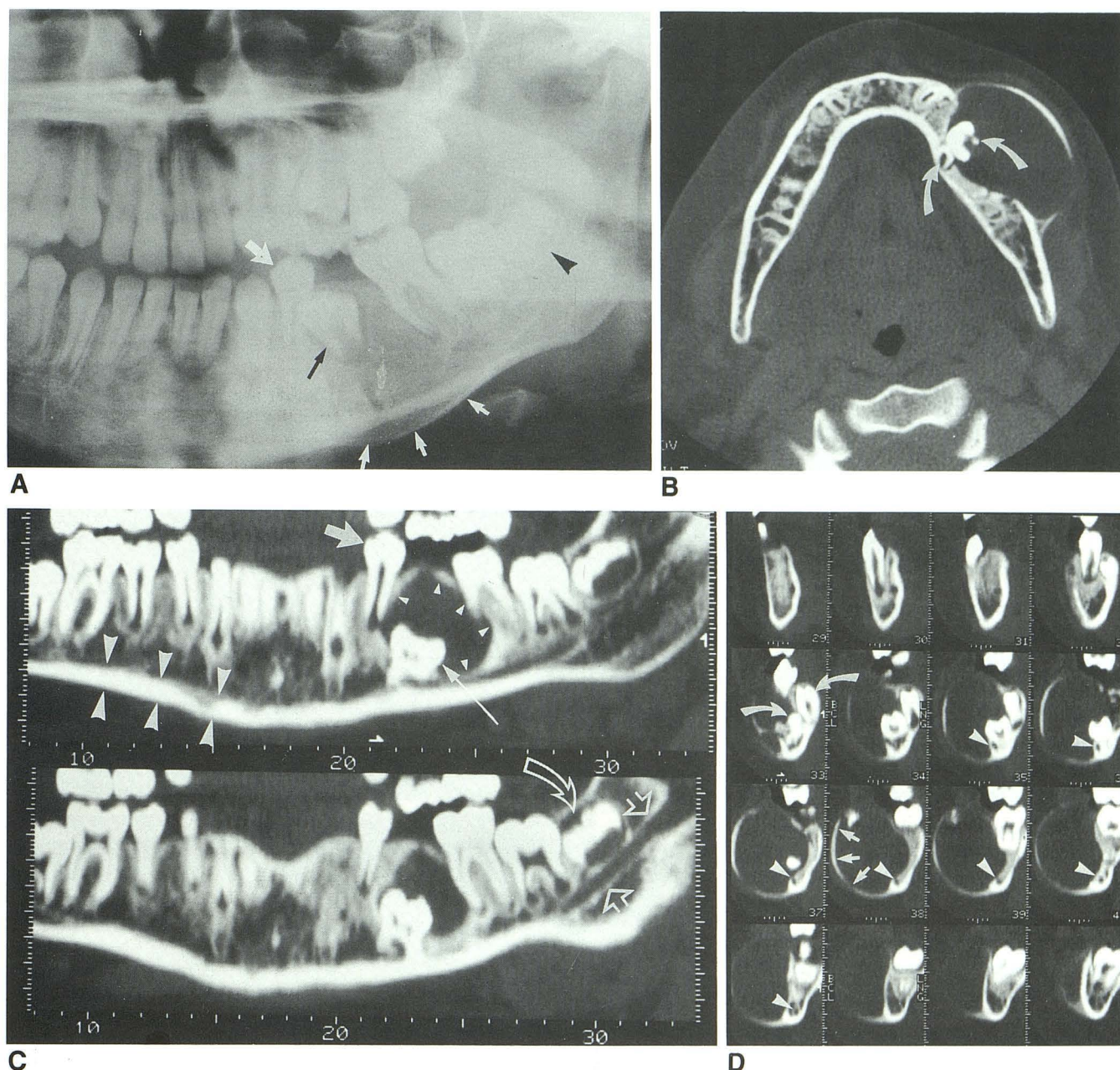


Fig. 1. Calcifying odontogenic cyst. Nine-year-old black girl with 3-month history of mandibular swelling.

A, Orthopantomogram. A double density reveals cortical expansion (*small white arrows*), but one cannot determine whether the buccal or lingual cortex is involved. The margins of the lesion are poorly defined and the neurovascular bundle is not identified. Superimposition of the ectopic tooth (*black arrows*) makes it difficult to determine if resorption of the left first bicuspid root (*large white arrow*) has occurred. Note the normal follicle of the developing molar (*black arrowhead*).

B, Axial CT. What appears to be a single ectopic tooth on the orthopantomogram is actually two teeth (*arrows*). This is more clearly delineated on the cross-sectional images (*D*).

C, Panoramic DentaScan. Increased contrast permits clear delineation of the cortex (*large arrowheads*) and margins of the lesion (*small arrowheads*). Ectopic tooth (*long arrow*); left first bicuspid (*wide arrow*). Inferior alveolar canal (*open straight arrows*); follicle of developing molar (*open curved arrow*).

D, Cross-sectional DentaScan through lesion. Images clearly demonstrate expansion of the buccal cortex (*short arrows*), two teeth within the lesion (*curved arrows*), and displacement of the inferior alveolar canal (*arrowheads*).

images, however, clearly demonstrated the displaced neurovascular bundle (Figs. 1D, 2C, and 3D). DentaScan also established the position of

the canal in relation to the lesion. In Figure 1D, note the displaced canal buccal to the ectopic tooth and adjacent to the cyst.



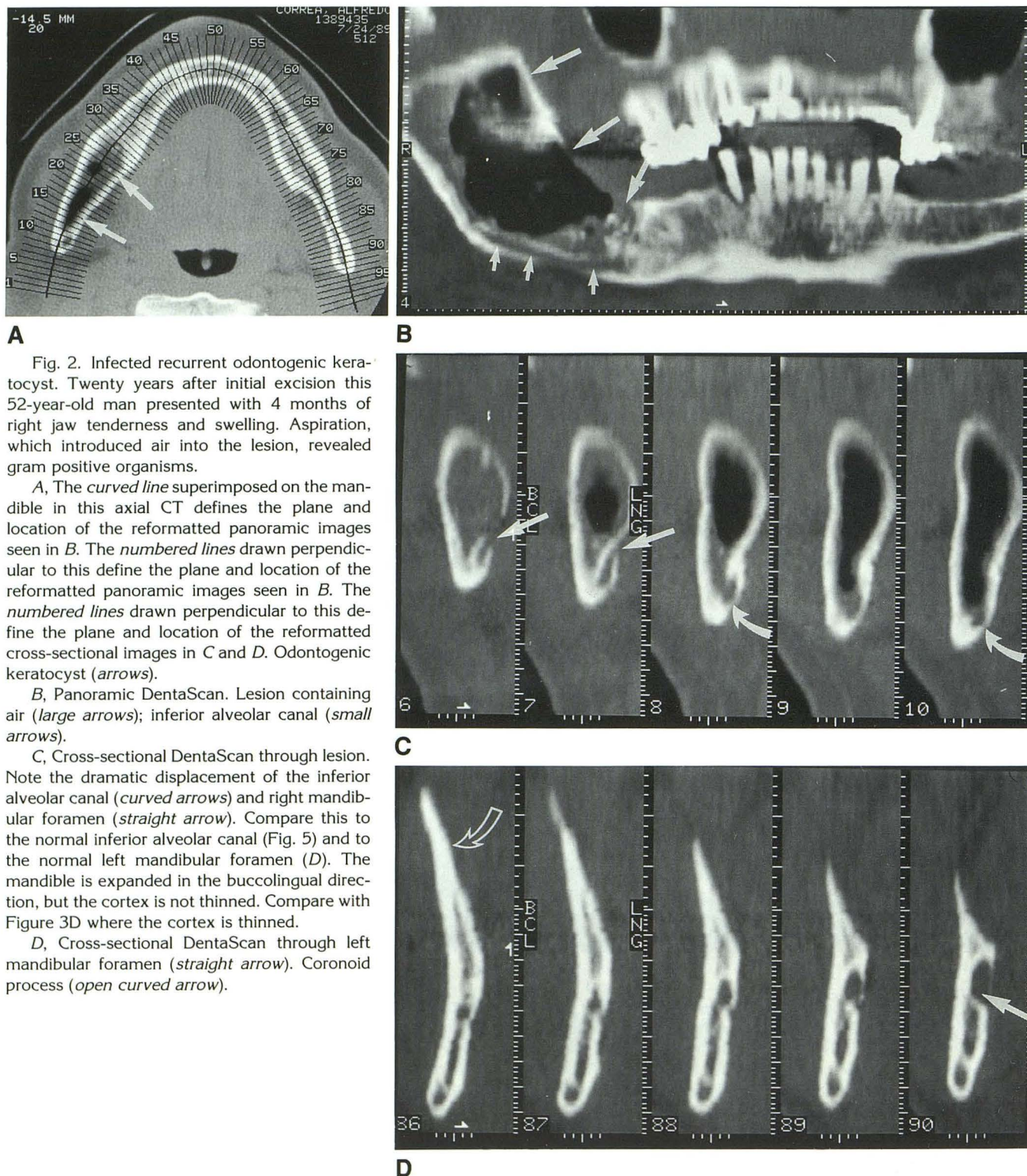


Fig. 2. Infected recurrent odontogenic keratocyst. Twenty years after initial excision this 52-year-old man presented with 4 months of right jaw tenderness and swelling. Aspiration, which introduced air into the lesion, revealed gram positive organisms.

**A**, The curved line superimposed on the mandible in this axial CT defines the plane and location of the reformatted panoramic images seen in **B**. The numbered lines drawn perpendicular to this define the plane and location of the reformatted panoramic images seen in **B**. The numbered lines drawn perpendicular to this define the plane and location of the reformatted cross-sectional images in **C** and **D**. Odontogenic keratocyst (arrows).

**B**, Panoramic DentaScan. Lesion containing air (large arrows); inferior alveolar canal (small arrows).

**C**, Cross-sectional DentaScan through lesion. Note the dramatic displacement of the inferior alveolar canal (curved arrows) and right mandibular foramen (straight arrow). Compare this to the normal inferior alveolar canal (Fig. 5) and to the normal left mandibular foramen (**D**). The mandible is expanded in the buccolingual direction, but the cortex is not thinned. Compare with Figure 3D where the cortex is thinned.

**D**, Cross-sectional DentaScan through left mandibular foramen (straight arrow). Coronoid process (open curved arrow).

### Detection of Cortical Involvement

Cortical involvement was more frequently and clearly delineated on the DentaScan images. In a calcifying odontogenic cyst, the orthopantomogram (Fig. 1A) demonstrates a double density in

the inferior aspect of the mandible consistent with cortical expansion. The degree of expansion, however, could not be appreciated on the plane film. It was also impossible to determine whether the buccal or lingual cortex was involved. On the



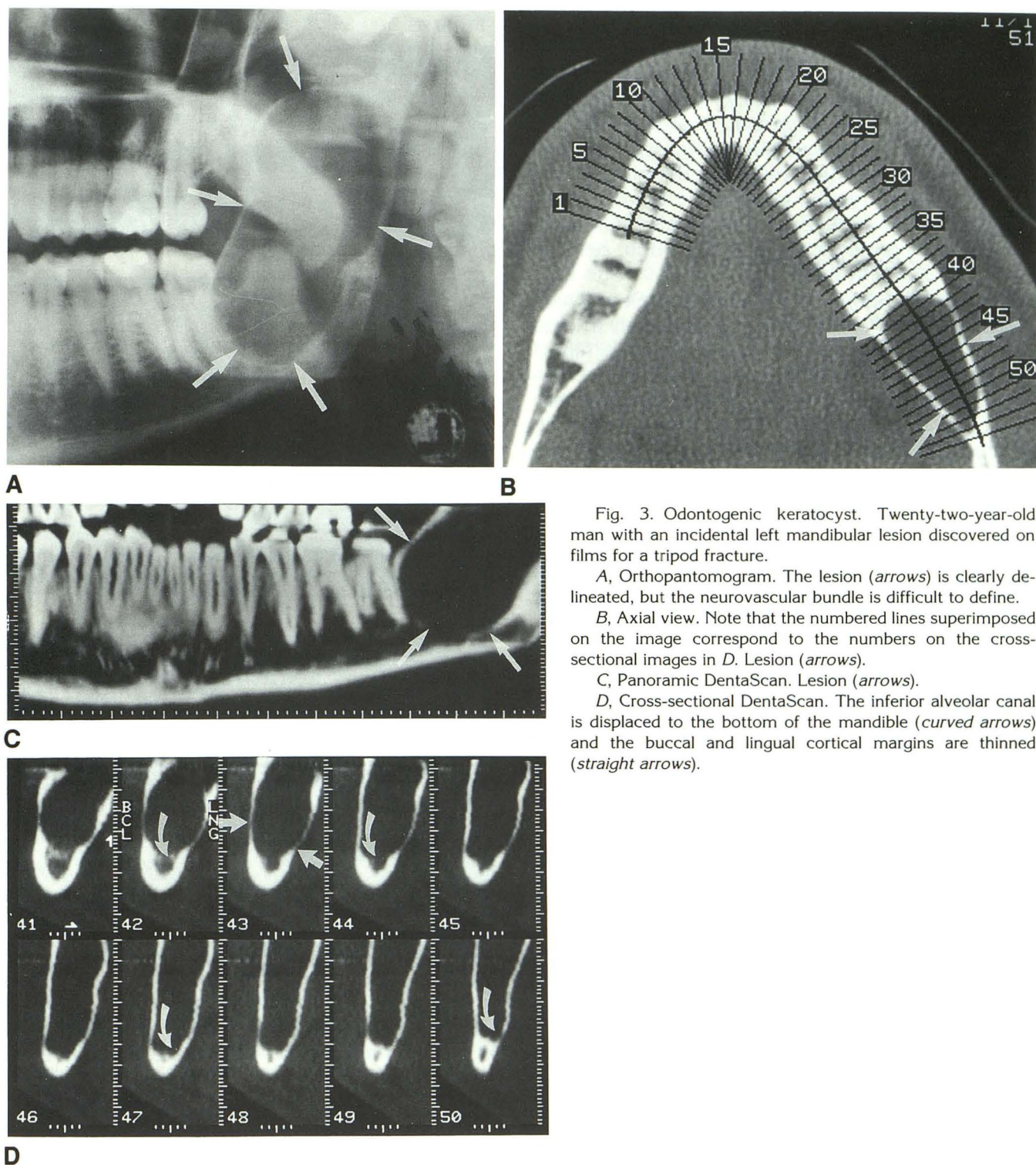


Fig. 3. Odontogenic keratocyst. Twenty-two-year-old man with an incidental left mandibular lesion discovered on films for a tripod fracture.

A, Orthopantomogram. The lesion (arrows) is clearly delineated, but the neurovascular bundle is difficult to define.

B, Axial view. Note that the numbered lines superimposed on the image correspond to the numbers on the cross-sectional images in D. Lesion (arrows).

C, Panoramic DentaScan. Lesion (arrows).

D, Cross-sectional DentaScan. The inferior alveolar canal is displaced to the bottom of the mandible (curved arrows) and the buccal and lingual cortical margins are thinned (straight arrows).

DentaScan (Figs. 1B, 1C, and 1D), it was quite clear that only the buccal cortex was thinned. The degree of thinning and the size of the lesion was also more clearly demonstrated on the DentaScan.

Similarly, in an odontogenic keratocyst, the cross-sectional images were instrumental in de-

tecting buccolingual expansion (Fig. 2C). This is better seen by comparing the images of the unaffected left side (Fig. 2D) with the images of the right side, which contains the lesion (Fig. 2C). In this case, it is of interest that despite the expanded mandible, the cortex is still preserved and not significantly thinned. Compare this with



the odontogenic keratocyst in Figure 3D where the buccal and lingual cortex is thinned. This type of detail is not appreciated on the plain films.

In Figure 4, a dentigerous cyst can be identified on the orthopantomogram but cortical involvement cannot be established. On the cross-sectional DentaScan images (Fig. 4C), the thinning of the buccal cortex is readily visualized.

### Detection of Root Involvement

Both conventional films and DentaScan were rated 'good' for evaluating root involvement. When teeth were superimposed on plain films, however, the DentaScan was superior. For example, on the orthopantomogram of a dentigerous cyst, the unerupted cuspid within the cyst obscures the roots of the incisors (Fig. 4A) and in the case of a calcifying odontogenic cyst the ectopic tooth partially obscures the root of the first bicuspid (Fig. 1A). The multiplanar format of DentaScan alleviated these problems. In the dentigerous cyst case, the cross-sectional images (Fig. 4C) clearly separated the unerupted cuspid from the incisors, and demonstrated that root resorption was not present. The ectopic tooth in the calcifying odontogenic cyst was actually shown by the DentaScan to be two teeth (Fig. 1D). The images also demonstrate that there was no erosion of the first bicuspid root.

In addition to the above points, DentaScan was also judged to be superior because of its higher-contrast resolution. For example, comparing the orthopantomographic image of the calcifying odontogenic cyst (Fig. 1A) with the DentaScan panoramic image (Fig. 1C), the increased contrast of the DentaScan allowed better differentiation of cortical from cancellous bone. This was particularly evident on the cross-sectional DentaScan images (Fig. 1D). In addition, the increased contrast allowed better resolution of the lesion and better definition of its margins, as illustrated by the calcifying odontogenic cyst (Fig. 1) and the dentigerous cyst (Fig. 4). In both of these cases, the margins and internal characteristics of the lesions were noted on the DentaScan but not on the orthopantomogram.

### Discussion

We have demonstrated in this limited study that dental CT software programs are useful for evaluating odontogenic cysts. The cross-sectional image, which is unique to these programs, was

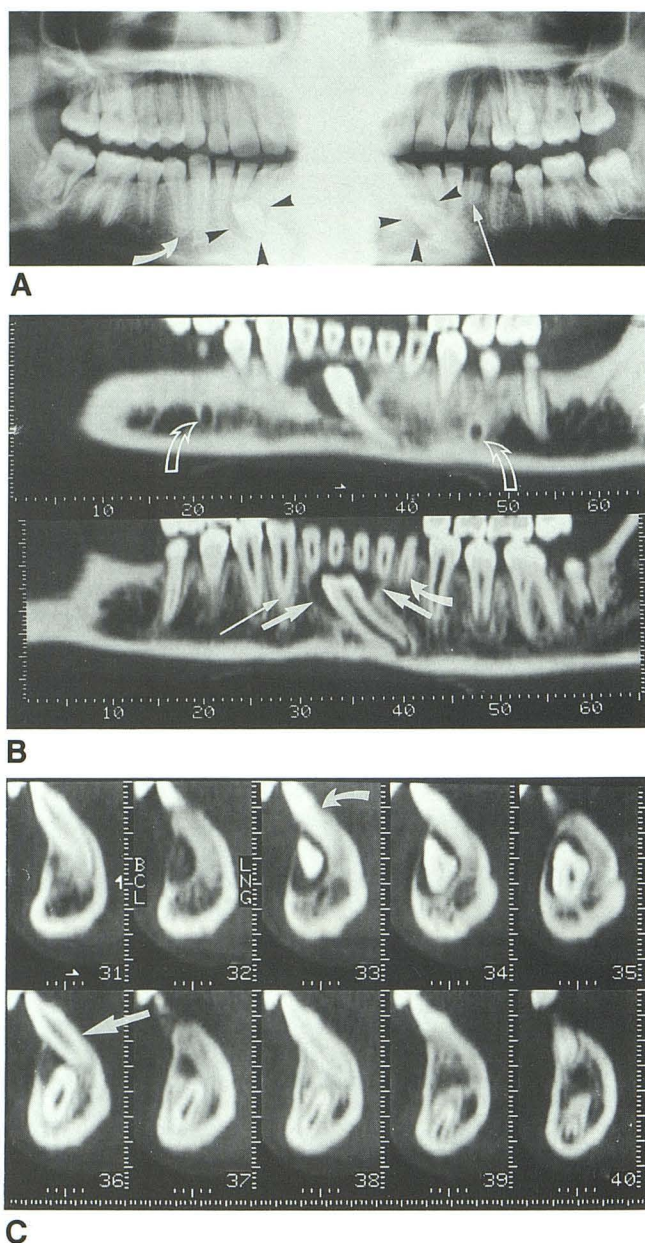


Fig. 4. Dentigerous cyst of left cuspid. Fourteen-year-old boy with lesion discovered on routine dental films.

A, Orthopantomogram. The dentigerous cyst surrounding the unerupted left cuspid is actually seen twice because of distortion near the midline (*arrowheads*). Note that the root of the primary cuspid on the left (*thin arrow*) is much shorter than the root of the permanent cuspid on the right (*curved arrow*).

B, Panoramic DentaScan. The increased contrast permits better delineation between the surrounding tissue and the unerupted left cuspid and dentigerous cyst (*large solid arrows*). Primary left cuspid (*solid curved arrow*); permanent right cuspid (*thin arrow*); mental foramina (*open curved arrows*).

C, Cross-sectional DentaScan. The relation of the lesion to the roots of the right (*curved arrow*) and left (*straight arrow*) central incisors is clearly seen. The inferior alveolar canal is not seen because the lesion is mesial to the mental foramina (see B).



felt to be most valuable. It enables one to differentiate buccal from lingual cortical involvement and to determine the position of the neurovascular bundle in relation to the lesion. It should be pointed out that since these images are acquired using low technique, they are optimal only for evaluating the osseous jaw and its contents. Surrounding soft tissue is better studied with magnetic resonance.

In addition to supplying important diagnostic information, DentaScan was instrumental in surgical management. The cortical margins of odontogenic cysts may be remarkably thin or absent at various points along the cyst. Identifying these areas and planning the surgical approach through them will diminish the chance of postoperative fracture. Identification of the neurovascular bundle will help prevent intraoperative hemorrhage and/or postoperative parathesia.

Since some odontogenic cysts are more aggressive than others, it is important to develop an understanding of their classification and radiographic appearance. In the past, the classification (1, 9, 10) has undergone change, but the following groups are generally accepted today (1): dentigerous cyst, radicular cyst, lateral periodontal cyst, gingival cyst, odontogenic keratocyst, and calcifying odontogenic keratocyst. The gingival cyst is not radiographically apparent and will not be discussed.

Dentigerous cysts (follicular cysts) (1, 9, 10, 11) (Fig. 4) are well-circumscribed radiolucent lesions that develop around the crown of an impacted or unerupted tooth. Common sites are where teeth often impact—the upper and lower third molars and maxillary cuspids. The lesion has a thin sclerotic rim and is typically unilocular, but occasionally multilocular. The enlarging cyst, which is benign, may show aggressive features including expansion of bone, displacement of teeth, and root resorption. A tooth within the cyst helps differentiate it from other cystic lesions of the jaw. It should not be confused with the smaller (less than 3 mm) (11) follicular space, a normal radiolucency that surrounds developing teeth (Figs. 1A and 1C). Treatment consists of removal of the associated tooth and enucleation of the cyst.

Radicular cysts (referring to the root) (1, 9), also known as apical periodontal or periapical cysts, are the most common odontogenic cysts. They appear as small periapical lucencies that arise from preexisting infection. The infection typically enters the pulp chamber and root canal

via a carious tooth. The cyst's proximity to the root apex helps differentiate it from other cystic lesions of the jaw. Treatment consists of extraction of the nonvital tooth and curetting of the cyst. If the cyst is incompletely removed, a "residual cyst" may remain (10).

Lateral periodontal cysts are nonkeratinized, noninflammatory developmental cysts that are intimately related to the lateral root surface of an erupted tooth. The borders are often well marginated and frequently contain a fine sclerotic rim. There is a predilection for the mandibular bicuspid, cuspid, or incisor (12), and there is a male-to-female ratio of 2:1. Since the cysts rarely exceed 10 mm, they usually do not displace teeth and are considered relatively nonaggressive. Surgery is curative, and recurrence is rare.

The odontogenic keratocyst (1, 9-11, 13-15) is a lesion that has stirred much controversy regarding its actual classification and etiology. Initially, the term was used to describe odontogenic cysts containing keratin. This led to confusion because other odontogenic cysts (dentigerous, radicular, and residual) occasionally contain keratin. Odontogenic keratocysts have now been shown to contain a specific type of keratin (parakeratin) and to be histologically and clinically distinct (1). Radiographically, they appear as unilocular or multilocular lucent lesions with sharply demarcated borders. The cyst has propensity for rapid growth and can be locally aggressive with expansion of bone and displacement of teeth. Most occur in the third molar region and often involve the ramus as illustrated in Figures 2 and 3. Odontogenic keratocysts may be difficult to differentiate from other odontogenic cysts, particularly when small. Distinguishing features are their rapid growth, local aggressiveness, and frequent occurrence in the ramus. There is a very high recurrence rate, even years after surgical excision (9, 14, 15) (Fig. 2).

Finally, the calcifying odontogenic cyst (1, 9, 10, 16) (Fig. 1) is a unilocular or multilocular radiolucent lesion containing variable amounts of calcified material. The amount of calcium increases with the age of the lesion. The margins are well defined and about 70% occur in the maxilla (1). Treatment is surgical because of their tendency for continued growth.

In summary, odontogenic cysts form a complex group of lesions that can be locally aggressive as demonstrated by expansion of the mandible, erosion of the cortex, displacement of the neurovascular bundle, and resorption of the roots



of the teeth. Demonstrating these changes radiographically is important for establishing a diagnosis and determining a surgical approach. Traditionally, these lesions have been evaluated in the dentist's office with standard orthopantomographic, intraoral, and mandibular films. We have demonstrated, however, that dental CT software programs are superior for evaluating these cysts. They provide multiplanar images and are able to detect subtle changes such as cortical involvement and neurovascular bundle displacement. Therefore, we believe that this should be the study of choice when evaluating these and other osseous lesions of the mandible.

### Acknowledgments

The authors thank Linda Abrahams for her assistance with editing and Nancy Judd and Phyllis Festa for their assistance in preparing this manuscript.

### References

1. Regezi JA, Scrubbs JJ. *Oral pathology: clinical-pathologic correlations*. Philadelphia: Saunders, 1989:301-336
2. MacKenzie GD, Oatis GW, Mullen MP, Grisius RJ. Computed tomography in the diagnosis of an odontogenic keratocyst. *Oral Surg Oral Med Oral Pathol* 1985;59:302-305
3. DelBalso AM, Wernig JT. The role of computed tomography in the evaluation of cemento-osseous lesions. *Oral Surg Oral Med Oral Pathol* 1986;62:354-357
4. Cohen MA, Hertzom Y, Mendelsohn DB. Computed tomography: the diagnosis and treatment of mandibular ameloblastoma. *J Oral Maxillofac Surg* 1985;43:796-801
5. Abrahams JJ, Levine B. Expanded applications of DentaScan. *Int J Periodontics Restorative Dent* 1990;10:465-471
6. Rothman SLG, Schwarz MS, Chafetz N, et al. CT in the preoperative assessment of the mandible and maxilla for endosseous implant surgery. *Radiology* 1988;168:171-175
7. Schwarz MS, Rothman SLG, Rhodes ML, Chafetz N. Computed tomography. I. Preoperative assessment of the mandible for endosseous implant surgery. *Int J Oral Maxillofac Implant* 1987;2:137-141
8. Schwarz MS, Rothman SLG, Rhodes ML, Chafetz N. Computed tomography. II. Preoperative assessment of the maxilla for endosseous implant surgery. *Int J Oral Maxillofac Implant* 1987;2:143-148
9. Shaffer WG, Hine MK, Levy BM, eds. *A textbook of oral pathology*. 4th ed. Philadelphia: Saunders, 1983:258-317
10. Gibilisco JA, ed. *Stafne's oral radiographic diagnosis*. 5th ed. Philadelphia: Saunders, 1985:159-171
11. Langlalis RP. Radiology of the jaws. In: Dalbalso AM, ed. *Maxillofacial imaging*. Philadelphia: Saunders, 1990:313-373
12. Fantasia JE. Lateral periodontal cyst. *Oral Surg Oral Med Oral Pathol* 1979;48:237-243
13. Toller P. Origin and growth of cysts of the jaws. *Ann R Coll Surg Engl* 1987;40:306-336
14. Brannon MB. The odontogenic keratocyst: a clinicopathologic study of 312 cases. I. Clinical features. *Oral Surg Oral Med Oral Pathol* 1976;42:54-72
15. Payne TF. An analysis of the clinical and histopathologic parameters of the odontogenic keratocyst. *Oral Surg Oral Med Oral Pathol* 1972;33:538-546
16. Gorlin RJ, Pindborg JS, Clausen FP, and Vickers RA. The calcifying odontogenic cyst: the possible analogue of the cutaneous calcifying epithelium of malherbe—an analysis of fifteen cases. *Oral Surg Oral Med Oral Pathol* 1962;15:1235-1243