



Get Clarity On Generics

Cost-Effective CT & MRI Contrast Agents



FRESENIUS
KABI

WATCH VIDEO

AJNR

MR findings in oculocerebrorenal syndrome.

W J Carroll, W W Woodruff and T E Cadman

AJNR Am J Neuroradiol 1993, 14 (2) 449-451

<http://www.ajnr.org/content/14/2/449>

This information is current as
of August 9, 2025.

MR Findings in Oculocerebrorenal Syndrome

William J. Carroll,¹ William W. Woodruff,¹ and Thomas E. Cadman²

Summary: Oculocerebrorenal syndrome is an X-linked recessive disorder characterized by congenital ocular abnormalities, mental retardation, renal disease, and metabolic bone disease. We report a case of oculocerebrorenal syndrome and, using T1-, proton density-, and T2-weighted imaging sequences, are able to characterize two distinct white matter abnormalities: one lesion is punctate and has signal characteristics that parallel that of cerebrospinal fluid; a second lesion, found in association with the first, consists of patchy white matter abnormalities that are hypointense on T1-weighted images but hyperintense on proton density- and T2-weighted images.

Index terms: Familial conditions; White matter, abnormalities; Pediatric neuroradiology; Degenerative brain disease

Oculocerebrorenal syndrome (OCRS), as first described by Lowe et al (1), is an X-linked recessive disorder whose etiology has yet to be determined. Recent gene mapping, however, suggests the probable gene site at Xq24–26 (2, 3). The primary clinical manifestations of OCRS include congenital ocular abnormalities, mental retardation, renal tubular dysfunction (Fanconi syndrome), and metabolic bone disease (1, 4–6). Therapy is supportive and is aimed both at treatment of ophthalmologic sequelae and at nutritional replacement of renal losses. Although the clinical and laboratory findings of OCRS are well documented, there are only a few imaging investigations that have used magnetic resonance (MR) to evaluate these patients (7–9). We present a case of OCRS and describe the cranial MR findings.

Case Report

A 7½-year-old white boy was referred for evaluation and treatment of seizures. Seizure activity was first noted approximately 6 months prior to presentation and consisted of unresponsiveness and clonic movements of the upper extremities followed by generalized hypotonia. The child was born at full term weighing 2.8 kg. A diagnosis of

OCRS was made at age 6 months. Development in all mental spheres was slow. There was no history of regression. The child sat at 3 years and began walking at 5 years. Past medical history included bilateral cataract surgery and glaucoma.

Physical examination revealed a small, thin boy whose height (96 cm) and weight (15.4 kg) were below the 3rd percentile. The child exhibited self-stimulatory activity and was noted to operate in the profoundly retarded range. There was evidence of bilateral eye surgery. Vision was markedly impaired. There was no evidence of glaucoma. Deep tendon reflexes were hypoactive. There was hypotonia of all extremities with bilateral proximal leg weakness. The patient's blood urea nitrogen, creatinine, and electrolytes were normal. Creatinine phosphokinase was elevated (762 IU/L; normal = 24–195). An electroencephalogram was grossly abnormal with slowing of the background activity. Multifocal spike and polyspike activity in addition to generalized spike wave paroxysms were noted.

T1-weighted MR images showed supratentorial white matter abnormalities consisting of multiple, bilateral, well-defined foci isointense to cerebrospinal fluid (Fig. 1A). Subtle regions of decreased signal intensity surrounded many of the lesions (Fig. 1B). Proton density- and T2-weighted images (Figs. 1C–1F) show more extensive confluent foci of increased signal present throughout the white matter extending from the subcortical region to the ventricular surface.

Discussion

The cranial MR findings in our patient consist of diffuse supratentorial white matter abnormalities. T1-, proton density-, and T2-weighted images confirm the presence of two distinct lesions. The first of these is characterized by multiple small spherical foci in deep and subcortical white matter. The signal characteristics of these foci parallel that of cerebrospinal fluid on all three spin-echo sequences. These discrete abnormalities were found in association with the second type of lesion that was characterized by confluent

Received January 27, 1992; revision requested February 20; revision received May 21 and accepted June 26.

¹ Department of Radiology, The Geisinger Medical Center, 100 North Academy Ave., Danville, PA 17822. Address reprint requests to W. W. Woodruff.

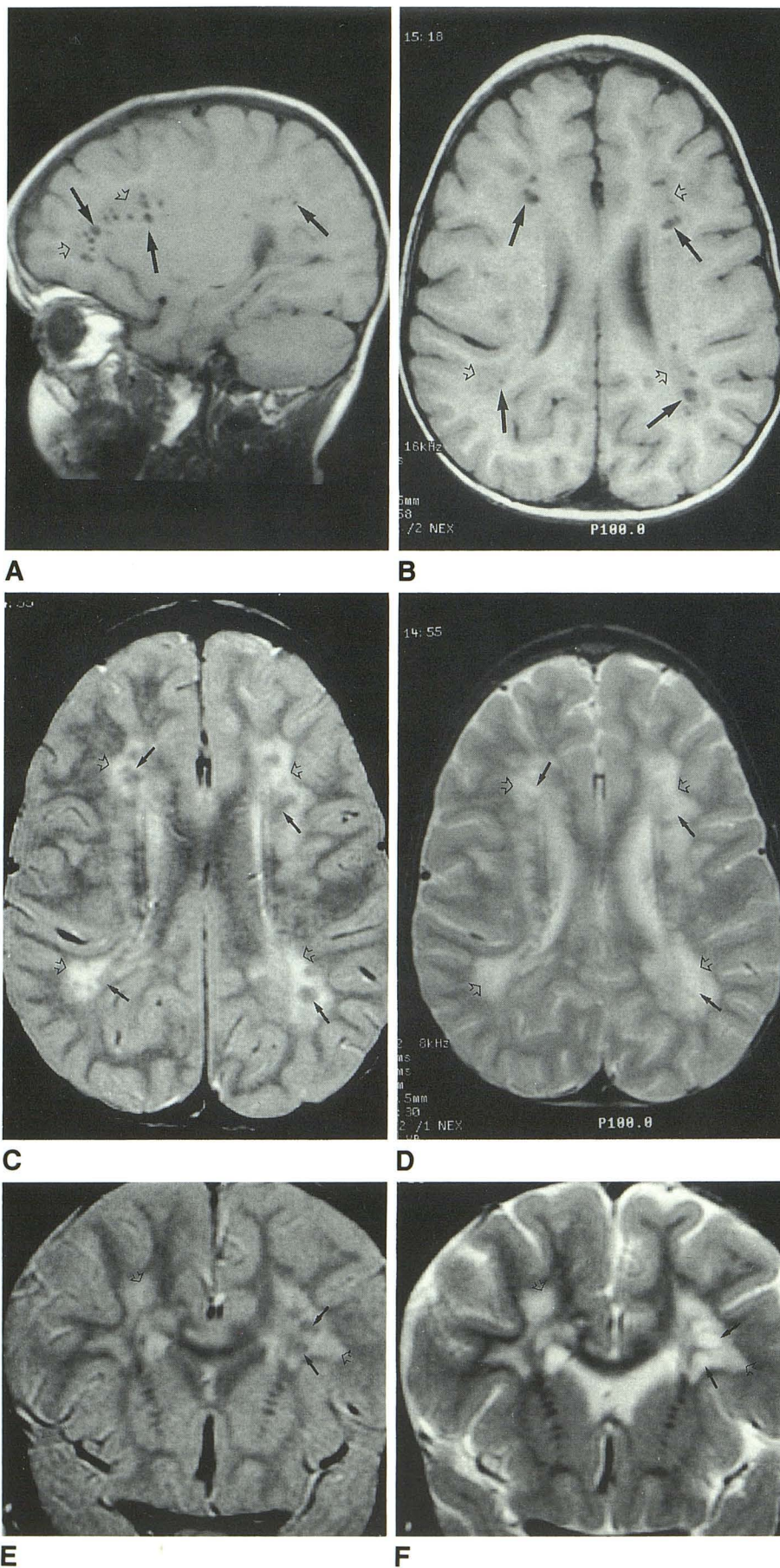
² Department of Pediatric Neurology, The Geisinger Medical Center, 100 North Academy Ave., Danville, PA 17822.

AJNR 14:449–451, Mar/Apr 1993 0195-6108/93/1402-0449 © American Society of Neuroradiology

Fig. 1. *A* and *B*, Parasagittal and axial T1-weighted images (350/15) (TR/TE) demonstrate multiple, well-defined foci isointense to cerebrospinal fluid (arrows) surrounded by regions of decreased signal intensity (open arrows).

C and *D*, Axial proton density- (2500/30) and T2-weighted (2500/90). The punctate lesions (arrows) identified on the T1-weighted sequence remain isointense to cerebrospinal fluid. Confluent high signal (open arrows) surrounded the punctate lesions sparing the subcortical U-fibers.

E and *F*, Coronal proton density- (2500/30) and T2-weighted (2500/90). The punctate high intensity foci (arrows) are surrounded by confluent high signal (open arrows).



areas of abnormal signal intensity. These confluent regions show diffuse involvement of the white matter with extension to the subcortical surface and are slightly hypointense on T1-weighted images and hyperintense on both proton density- and T2-weighted images. Neither lesion was associated with mass effects.

Several recent case reports (7–9) have described similar diffuse confluent white matter hyperintensities OCSR patients. Our manuscript describes both T1- and T2-weighted abnormalities and characterizes two distinct lesions based on their signal characteristics.

Although the focal white matter abnormalities described above point to the presence of two lesions, without histologic confirmation one can only speculate on their morphologic correlates. We believe that both lesions represent chronic processes and that the smaller punctate lesions represent focal areas of encephalomalacia perhaps arising secondary to remote insult. The confluent lesions, however, do not exhibit the signal characteristics of fluid. These white matter hyperintensities probably represent focal areas of gliosis or demyelination. Unfortunately, the neuropathologic data are derived from a limited number of gross and histologic autopsy specimens. These data (10–13) are extremely variable and were obtained prior to the advent of MR.

Habib et al (10) have described a primary demyelinating process involving both the cerebrum and cerebellum that they attribute to a toxic metabolic effect. Matin and Schlote (11) in a review of histologic slides from three patients (including a histologic specimen obtained from a child previously reported by Habib and coworkers) with OCSR also reported abnormalities that primarily involved white matter. However, they noted that the white matter pallor was largely a result of reactive gliosis. Except for several tiny foci in the case reported by Habib et al (10), no active demyelination was noted. Thus, they conclude that, at least in older children, the myelin pallor corresponded to gliosis. Matin and Sylvester (12) found decreased myelin content in white matter tracts of the cerebellum and brain stem and did not comment on any specific abnormalities involving the white matter of the cerebrum. Conversely, Richards et al (13) noted that the most striking abnormalities involved the cortical gray matter, although they too noted gliosis involving the white matter of the cerebrum.

The white matter hyperintensities reported here represent a nonspecific finding. Several of

the leukodystrophies including Alexander disease, Canavan disease, Krabbe disease, Pelizaeus-Merzbacher disease, and metachromatic and adrenoleukodystrophy can produce diffuse white matter abnormalities. Similarly, multiple sclerosis, the mucopolysaccharidoses, and the metabolic amino-acidurias (OCSR is a variant of renal Fanconi syndrome) produce deep and cortical white matter abnormalities. Finally, infectious, hypoxic, and traumatic etiologies can produce extensive white matter changes. Although the cranial MR findings reported here are not specific for OCSR, the constellation of clinical, laboratory, and imaging finds are. Our patient exhibited many of the typical clinical features of a child with OCSR including the characteristic ocular findings, mental retardation, profound developmental delay, seizures, myopathy, and growth retardation.

References

1. Lowe CU, Terrey M, MacLachlan EA. Organic-aciduria, decreased renal ammonia production, hydrophthalmos, and mental retardation: a clinical entity. *Am J Dis Child* 1952;83:164–184
2. Waldelius C, Fagerholm P, Pettersson U, Anneren G. Lowe oculocerebrorenal syndrome: DNA-based linkage of the gene to Zq24–q26, using tightly linked flanking markers as the correlation to lens examination in carrier diagnosis. *Am J Hum Genet* 1989;44:241–247
3. Silver DN, Lewis RA, Nussbaum RL. Mapping the Lowe oculocerebrorenal syndrome to Xq24–q26 by the use of restriction fragment length polymorphisms. *J Clin Invest* 1987;79:282–285
4. Charnas LR, Bernadini I, Rader D, Hoeg JM, Gahl WA. Clinical and laboratory findings in the oculocerebrorenal syndrome of Lowe with special reference to growth and renal function. *N Engl J Med* 1991;324:1318–1325
5. Abbassi V, Lowe CU. Oculo-cerebro-renal syndrome. *Am J Dis Child* 1968;115:145–168
6. Loughhead HL, Mimouni F, Schilling S, Feingold M. Picture of the month. *Am J Dis Child* 1991;145:113–114
7. O'Tauma DA, Lasker DW. Oculocerebrorenal syndrome: case report with CT and MR correlates. *AJNR* 1987;8:555–557
8. Charnas L, Bernar J, Pezeshkpour GH, Dalakas M, Harper GS, Gahl WA. MRI findings and peripheral neuropathy in Lowe's syndrome. *Neuropediatrics* 1988;19:7–9
9. Gabrielli O, Salvolini U, Coppa GV, et al. Magnetic resonance imaging in the malformative syndromes with mental retardation. *Pediatr Radiol* 1990;21:16–19
10. Habib R, Bargetyon E, Brissaud HE, Raynaud J, de Ball JC. Constata-tions anatomiques chez un enfant atteint d'un syndrome de Lowe. *Arch F Pediatr* 1962;19:945–960
11. Matin JJ, Schlote W. Central nervous system lesions in disorders of amino acid metabolism. *J Neurol Sci* 1972;15:26–29
12. Matin MA, Sylvester PE. Clinicopathological studies of oculocerebrorenal syndrome of Lowe, Terry, and MacLachlan. *J Ment Defic Res* 1980;24:1–16
13. Richards W, Donnell GN, Wilson WA, Stowens D, Perry T. The oculo-cerebro-renal syndrome of Lowe. *Am J Dis Child* 1965;109:185–200