



Get Clarity On Generics

Cost-Effective CT & MRI Contrast Agents



FRESENIUS
KABI

WATCH VIDEO

AJNR

The hippocampus.

L P Mark, D L Daniels, T P Naidich, Z Yetkin and J A Borne

AJNR Am J Neuroradiol 1993, 14 (3) 709-712

<http://www.ajnr.org/content/14/3/709.citation>

This information is current as
of August 14, 2025.

The Hippocampus

Leighton P. Mark,¹ David L. Daniels,¹ Thomas P. Naidich,² Zerrin Yetkin,¹ and Jessica A. Borne¹

Hippocampal anatomy and nomenclature (Table 1) are complex and confusing. This anatomic moment will highlight some features of the hippocampus to provide a perspective on this complex area.

When viewed from above (Fig. 1), the hippocampus bulges into the floor of the temporal horn and resembles a sea serpent (to early anatomists) with three parts: 1) The head, the most anterior part, is oriented nearly transversely, has parasagittally oriented digitations, and is separated from the amygdala anteriorly by the uncus recess of the temporal horn of the lateral ventricle. 2) The body is oriented parasagittally and is bordered laterally and superiorly by the temporal horn. The superior surface of the body is covered by the alveus, whose fibers form the medially positioned fimbria, which in turn form the crus of the fornix posteriorly. 3) The tail, the most posterior part, is oriented nearly transversely. It extends around the splenium of the corpus callosum and forms the indusium griseum, which is located just above the corpus callosum.

The complex hippocampal configuration is related to its development. The hippocampus forms from a continuous strip of cortex (Fig. 2) consisting of the more primitive dentate gyrus and Ammon's horn (the latter also called cornu ammonis or hippocampus proper). Ammon's horn is connected to the more developed neocortex by the subiculum, which is a transitional type of cortex. Ammon's horn and the dentate gyrus achieve a convoluted appearance because of cortical in-folding (Figs. 2 and 3) at the site of the hippocampal sulcus. This in-folding results in Ammon's horn and the dentate gyrus forming two interlocking U's, with Ammon's horn forming the more lateral upside-down U when viewing the hippocampal body in the coronal plane. The interlocking relationship of the dentate gyrus and Ammon's horn persists even in the hippocampal head. The medial part of the hippocampal head

forms the posterior half of the uncus, where the dentate gyrus continues as the band of Giacomini.

Ammon's horn can be subdivided into four distinct zones based upon histologic differences of its main cellular layer (1). Progressing from the subiculum to the dentate gyrus, these zones are designated *cornu ammonis 1 to 4* (CA1 to CA4) (Fig. 4). CA1 to CA4 have also been described according to their sensitivity to hypoxia. CA1 (Sommer sector) is also called the *vulnerable sector*. CA2 and CA3 (Spielmeyer sector) have been referred to as the *resistant sector*. CA4 (Bratz sector), nestled adjacent to the dentate gyrus, is also called the *medium vulnerability sector*. Mesial temporal sclerosis typically involves CA1 and perhaps CA4.

The number of visible structures on the medial surface of the temporal lobe differs from the anterior aspect of the hippocampal body to the posterior hippocampal region. Three structures are visible anteriorly, whereas five structures are present posteriorly. The three anterior structures (Figs. 5 and 6) are (from superior to inferior): the fimbria, the margo denticulatus (visible teethlike medial bulging of the dentate gyrus on the cortical surface), and the subiculum. More posteriorly (Fig. 6), the five visible posterior hippocampal structure (from superior to inferior) are: the fimbria, the gyrus fasciolaris, the fasciola cinerea, the gyrus of Andreas Retzius, and the subiculum.

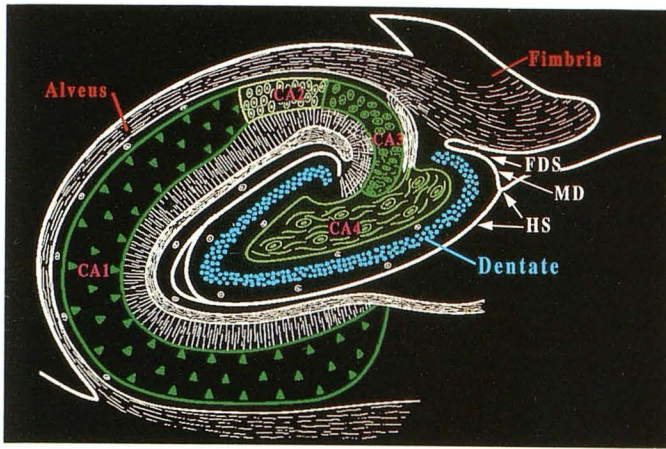
TABLE 1: Meaning of Names

Hippocampus = sea serpent
Amygdala = almond-shaped
Dentate = tooth-like
Margo = margin
Subiculum = bed or cave
Alveus = channel
Fimbria = fringe
Uncus = hook-shaped
Gyrus fasciolaris and fasciola cinerea = both mean a band of gray matter

¹ Department of Radiology, The Medical College of Wisconsin, Milwaukee, WI. Address reprint requests to Leighton P. Mark, MD, Department of Radiology, The Medical College of Wisconsin, Froedtert Memorial Lutheran Hospital, 9200 West Wisconsin Avenue, Milwaukee, WI 53226.

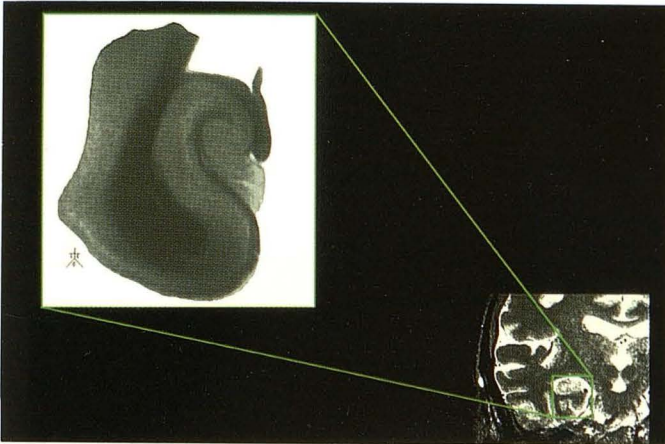
² Department of Radiology, Baptist Hospital of Miami, Miami, FL.

Index terms: Hippocampus; Brain, anatomy; Anatomic moments

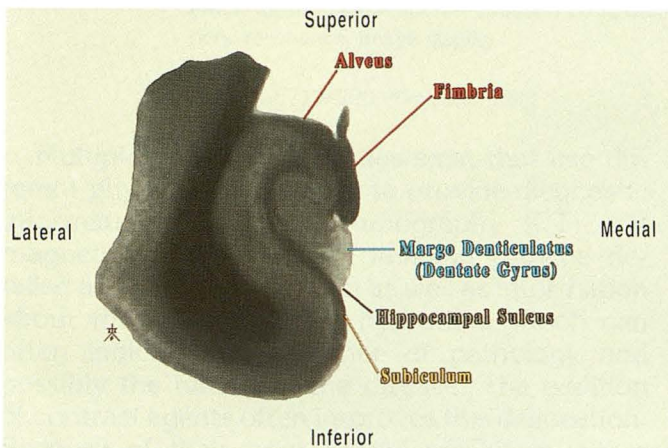


4

Fig. 4. Coronal schematic showing the four distinct histologic areas of Ammon's horn (green): CA1, CA2, CA3, and CA4. CA1 lies adjacent to the subiculum; CA4 is next to the dentate gyrus (blue). Ammon's horn and the dentate gyrus appear as two interlocking U's in this plane. The fimbriodentate sulcus (FDS) separates the fimbria from the dentate gyrus. The hippocampal sulcus (HS) forms the inferior border of the dentate gyrus. The alveus (red) covers the intraventricular surface of the hippocampus and forms the fimbria (red) medially (reprinted and modified from Duvernoy (5) with permission).



5A

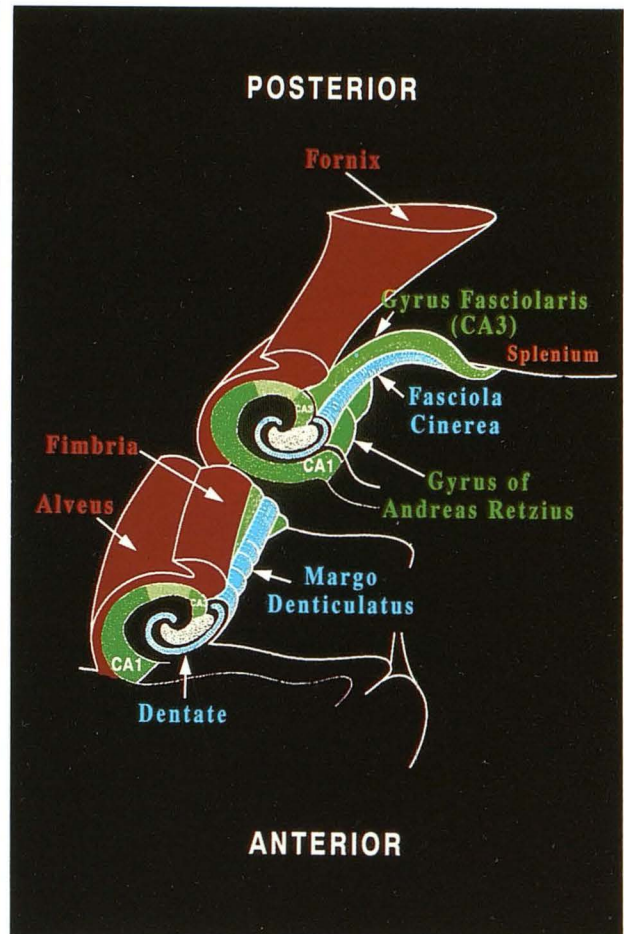


5B

Fig. 5. A, Reference figure for Figure 5B. The high resolution (field of view = 2 cm; slice thickness = 1 mm) coronal magnetic resonance image of a hippocampal specimen (left) corresponds to the indicated area on a clinical coronal magnetic resonance image (right).

B, High-resolution coronal magnetic resonance image of the anterior aspect of the body of the hippocampus in a specimen. The margo denticulatus is separated from the subiculum by the hippocampal sulcus. The alveus covers the superior surface of Ammon's horn. The fibers of the alveus also extend medially to form the fringelike fimbria.

Fig. 6. Schematic showing the visible structures on the medial surface of hippocampus viewed from superior medially. At the anterior aspect of the hippocampal body, the fimbria (red) is positioned immediately above the margo denticulatus (blue). At the posterior hippocampus, the divergent course of the fimbria (red) exposes gyrus fasciolaris (light green), which represents the medial bulging of CA1. The fasciola cinerea (blue) is the posterior continuation of the margo denticulatus. The gyrus of Andreas Retzius (dark green) represents the medial bulging of CA1 and is inferior to the fasciola cinerea (reprinted and modified from Duvernoy (5) with permission).



6

The divergent course of the fimbria reveals gyrus fasciolaris, which is the exposed portion of CA3 covered superiorly by the alveus. Fasciola cinerea is the posterior continuation of margo denticulatus. The gyrus of Andreas Retzius is the medial cortical bulging produced by CA1.

Subsequent Anatomic Moments will show how some of these limbic structures can be recognized on clinical magnetic resonance images and how these anatomic landmarks are altered by pathology.

Acknowledgment

We wish to thank Diane McCain of Medical Center Graphics in Milwaukee for her help in preparing the computerized images used for this article.

References

1. Lorente de Nó R. Studies on the structure of the cerebral cortex II. Continuation of the study of the ammonic system. *J f. Psychol Neurol* 1934;46(2):113-177
2. Naidich TP, Daniels DL, Haughton VM, Williams A, Pojunas K, Palacios E. Hippocampal formation and related structures of the limbic lobe: anatomic-MR correlation. I. Surface features and coronal sections. *Radiology* 1987;162:747-754
3. Naidich TP, Daniels DL, Haughton VM, Pach P, Williams A, Pojunas K, Palacios E. Hippocampal formation and related structures of the limbic lobe: anatomic-MR correlation. II. Sagittal sections. *Radiology* 1987;162:755-761
4. Williams PL, Warwick R, Dyson M, Bannister LH. *Gray's anatomy*. 37th ed. London: Churchill Livingstone, 1989
5. Duvernoy HM. *The human hippocampus: an atlas of applied anatomy*. Berlin: J. F. Bergmann Verlag Munchen, 1988
6. Nieuwenhuys R, Voogd J, Van Huijzen C. *The human central nervous system. a synopsis and atlas*. 3rd revised ed. Berlin: Springer-Verlag, 1988