



## Get Clarity On Generics

Cost-Effective CT & MRI Contrast Agents



FRESENIUS  
KABI

WATCH VIDEO

# AJNR

## **Rhabdomyosarcoma of the middle ear: imaging features in two children.**

M Castillo and H C Pillsbury, 3rd

*AJNR Am J Neuroradiol* 1993, 14 (3) 730-733

<http://www.ajnr.org/content/14/3/730>

This information is current as  
of August 13, 2025.

# Rhabdomyosarcoma of the Middle Ear: Imaging Features in Two Children

Mauricio Castillo<sup>1</sup> and Harold C. Pillsbury III<sup>2</sup>

**Summary:** The imaging features are presented in two cases of rhabdomyosarcoma arising from the middle ear during childhood, an extremely rare and aggressive neoplasia. CT provides excellent information concerning the degree of bone involvement; contrast-enhanced MR imaging clearly delineates subcranial and/or intracranial extension.

**Index terms:** Myosarcoma; Temporal bone, neoplasms; Temporal bone, magnetic resonance; Temporal bone, computed tomography; Pediatric neuroradiology

Rhabdomyosarcoma is the most common soft tissue malignancy found in children less than 5 years of age (1). Overall, embryonal rhabdomyosarcoma is the most common histologic subtype (2). Lesions originating in the middle ear are initially manifested as chronic otitis media; if a superficial biopsy is performed, only granulomatous inflammatory tissues will be found (3). Tumor extension to other portions of the temporal bone may give rise to cranial nerve deficits.

## Case 1

A 5-year-old previously healthy boy presented with a 2-week history of right facial palsy. Physical examination confirmed right Bell palsy and decreased taste in the anterior two thirds of the tongue. Lacrimation was preserved. Otologic evaluation revealed the presence of a red mass behind an intact right tympanic membrane. The external auditory canal was compressed by a subcutaneous mass involving its posterior and superior quadrant. Computed tomography (CT) showed soft tissue in the right external and middle ear (Figs. 1A and 1B). Destruction of the anterior and posterior margins of the external canal was evident. Erosion of the tegmen tympani with extension into the superior and lateral petrous bone was present. The temporal squama was also eroded. Gadolinium-enhanced magnetic resonance (MR) showed that the lesion extended into the intracranial space, displacing the temporal lobe

superiorly but not invading it (Figs. 1C and 1D). A retro-mastoid biopsy was performed and confirmed the presence of embryonal rhabdomyosarcoma. Radionuclide bone scan was normal, but chest CT showed two small nodules in the right lung compatible with metastases. At the time of this writing, the patient was undergoing chemotherapy and radiotherapy.

## Case 2

A 3-year-old boy presented with a 1-month history of left ear pain. He was treated with antibiotics for 10 days, but the pain persisted and bloody discharge from the left ear developed. On physical examination, the left external auditory canal was filled with a polypoid and hemorrhagic mass. CT showed soft tissue filling the left middle ear cavity with no destruction of the ossicles (Fig. 2A). The lesion destroyed the eustachian tube and extended into the region of the foramen lacerum. A relatively nonenhancing soft tissue mass extended into subcranial region (Fig. 2B). Biopsy of the lesion in the external auditory canal revealed embryonal rhabdomyosarcoma. The patient received radiation and chemotherapy; a 3-month follow-up CT showed partial remineralization of the temporal bone (Fig. 2C).

## Discussion

Rhabdomyosarcomas comprise three distinct histologic subtypes: embryonal, alveolar, and pleomorphic (2). Of these, the embryonal type is the most common one found in the head and neck. Of all childhood rhabdomyosarcomas, approximately 30%–50% occur in the head and neck (4). The most common locations in the head and neck include the nasopharynx and orbits. Only 7% of rhabdomyosarcomas arise in the middle ear, and they may begin either in the muscles of the eustachian tube, in the proper middle ear, or from primitive pluripotential mesenchymal rests (1, 5). However, at diagnosis,

Received March 12, 1992; revision requested July 30, received August 14, and accepted September 25.

Departments of <sup>1</sup>Radiology and <sup>2</sup>Head and Neck Surgery, University of North Carolina, Chapel Hill, NC 27599. Address reprint requests to Mauricio Castillo, M.D., Department of Radiology, CB 7510, University of North Carolina at Chapel Hill, Chapel Hill, NC 27599-7510.

AJNR 14:730–733, May/Jun 1993 0195-6108/93/1403-0730 © American Society of Neuroradiology



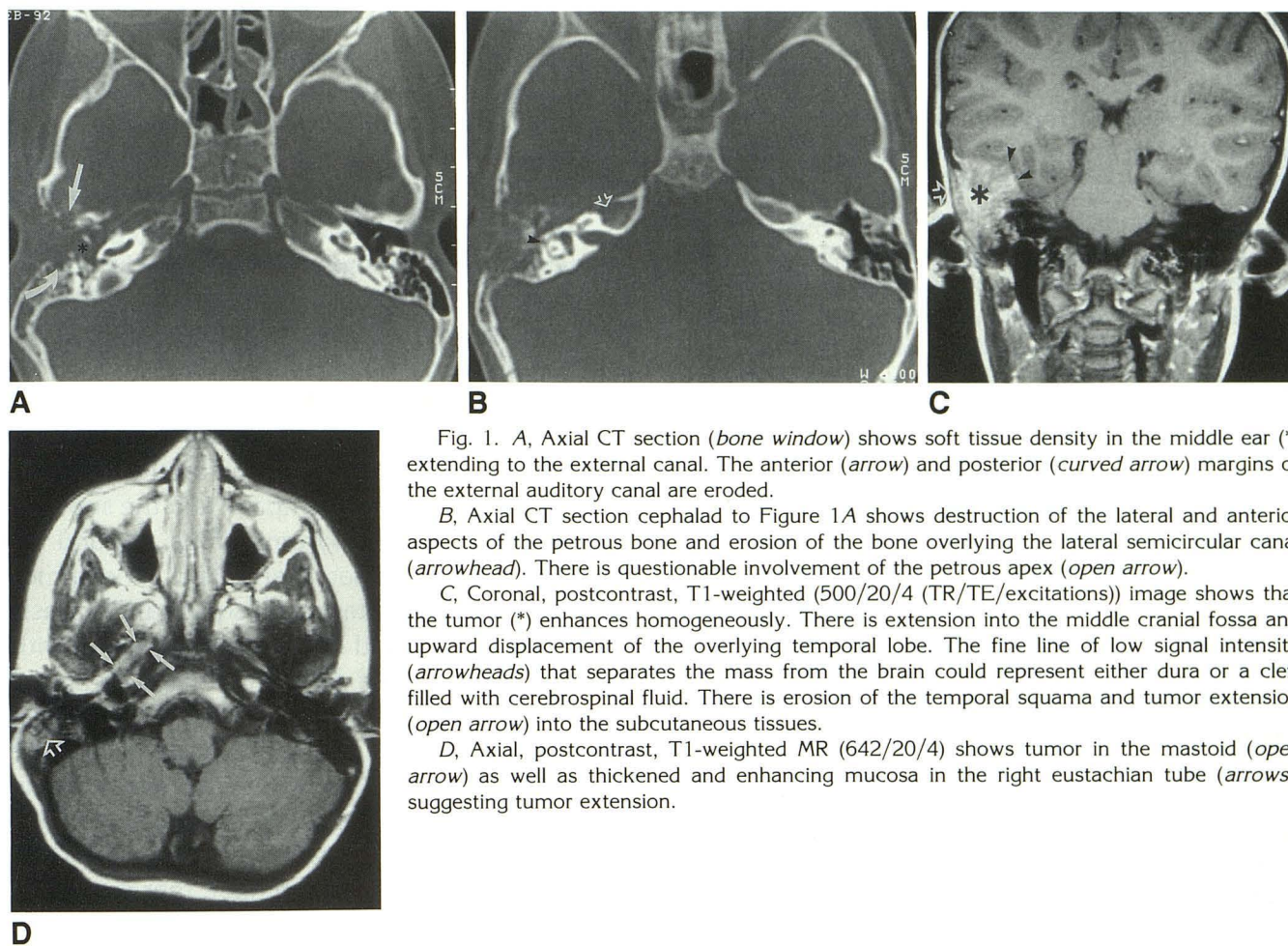


Fig. 1. A, Axial CT section (*bone window*) shows soft tissue density in the middle ear (\*) extending to the external canal. The anterior (*arrow*) and posterior (*curved arrow*) margins of the external auditory canal are eroded.

B, Axial CT section cephalad to Figure 1A shows destruction of the lateral and anterior aspects of the petrous bone and erosion of the bone overlying the lateral semicircular canal (*arrowhead*). There is questionable involvement of the petrous apex (*open arrow*).

C, Coronal, postcontrast, T1-weighted (500/20/4 (TR/TE/excitations)) image shows that the tumor (\*) enhances homogeneously. There is extension into the middle cranial fossa and upward displacement of the overlying temporal lobe. The fine line of low signal intensity (*arrowheads*) that separates the mass from the brain could represent either dura or a cleft filled with cerebrospinal fluid. There is erosion of the temporal squama and tumor extension (*open arrow*) into the subcutaneous tissues.

D, Axial, postcontrast, T1-weighted MR (642/20/4) shows tumor in the mastoid (*open arrow*) as well as thickened and enhancing mucosa in the right eustachian tube (*arrows*), suggesting tumor extension.

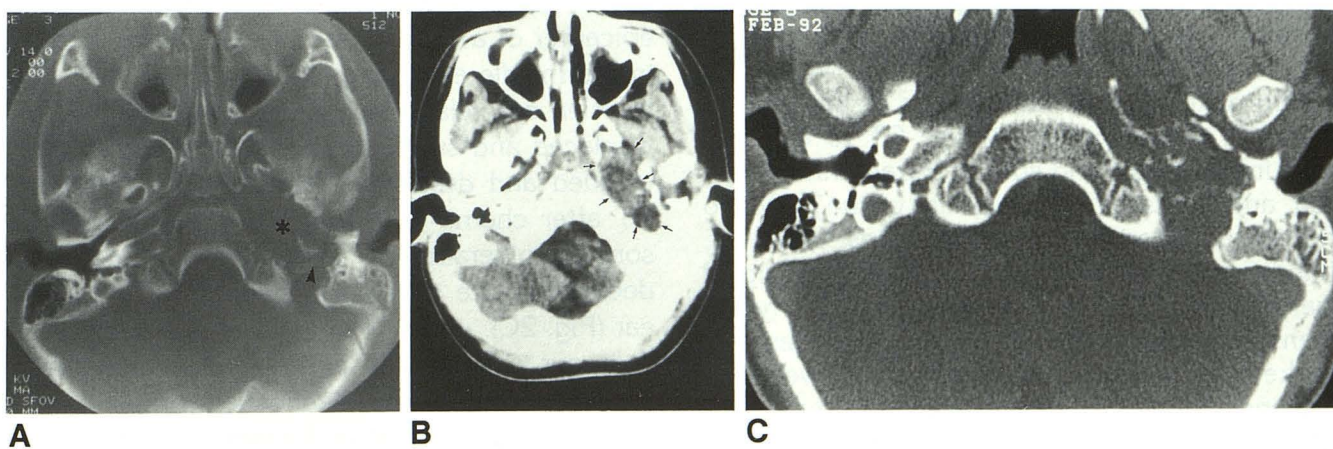


Fig. 2. A, Axial CT section (*bone window*) shows destruction of the bone margins of the eustachian tube as well as destruction of the medial petrous bone (\*). The anterior margin of the jugular foramen is eroded (*arrowhead*).

B, Axial, contrast-enhanced CT (*soft tissue windows*) at the same level as Figure 2A demonstrating that the mass (*arrows*) is relatively hypodense to muscle and shows no significant contrast enhancement.

C, Axial CT section (comparable level to Fig. 2A) obtained after the completion of radiotherapy and chemotherapy. This image best demonstrates the partial remineralization within the lesion. The mastoid air cells remain opacified.



there usually is widespread local invasion throughout the petrous bone and the actual site of origin cannot be determined in the great majority of cases. Extensive bone erosion occurs in up to 67% of middle ear tumors (6). Metastases to cervical lymph nodes are present in 12% to 50% of all patients with head and neck rhabdomyosarcomas (5, 7). At present, rhabdomyosarcomas of the head and neck are classified as: 1) orbital, 2) parameningeal, or 3) all other head and neck sites (7). Those arising in the middle ear are grouped jointly with those arising from the paranasal sinuses and from the nasopharynx (7). Meningeal involvement is the worst prognostic indicator in head and neck rhabdomyosarcomas (7).

Clinically, middle ear rhabdomyosarcomas are manifested initially as chronic otitis media (3). However, progression is fairly fast, and facial nerve palsy is usually present at diagnosis. Involvement of the petrous apex, internal auditory canal, and skull base may lead to other cranial neuropathies (8). Approximately 30% of these patients will have neurologic deficits at diagnosis (4). Middle ear inflammatory disease may be concomitantly present, thus delaying the diagnosis and making total resection impossible in most cases. Multiple drug chemotherapy and radiation therapy with or without tumor debulking have resulted in improvement of the long-term prognosis (2).

From the imaging standpoint, we believe that both CT and MR are needed in the evaluation of tumors involving the skull base. CT is the imaging modality of choice to evaluate bone destruction. Temporal bone rhabdomyosarcomas usually show aggressive osseous destruction with obliteration of the normal landmarks of the base of the skull. MR is preferred over CT to evaluate dural involvement and sub- or intracranial extension, and to assess the proximity of the tumor to the carotid arteries and jugular veins. However, rhabdomyosarcomas show nonspecific MR signal characteristics; that is, they are minimally hyperintense to muscle on T1-weighted images and markedly hyperintense to muscle on T2-weighted sequences (9). In one series, seven of 13 patients received gadolinium and these tumors demonstrated intense homogenous enhancement (9). These authors also found coronal images most useful in the planning of radiation treatments. The differential diagnosis of destructive lesions of

the temporal bone in children includes congenital and acquired cholesteatomas. The former usually present as well-margined masses in the petrous apex; the latter occur in the middle ear and characteristically show erosion of the scutum. Other destructive lesions of the temporal bones in children are Langerhans cell histiocytosis, adenocarcinoma, and squamous cell carcinoma. In our experience, these lesions are radiographically indistinguishable from each other; in order to reach a diagnosis, a biopsy is needed.

In case 1, the tumor arose in the middle ear and extended laterally, giving rise to erosion of the external auditory canal, the lateral semicircular canal, the tegmen tympani, and the superior aspect of the petrous pyramid (Figs. 1A and B). There was no ossicular destruction. The tumor also extended to the temporal squama. Contrast-enhanced MR showed intracranial extension with upward displacement of the overlying temporal lobe (Fig. 1C). MR also suggested the presence of tumor extension along the eustachian tube (Fig. 1D). In case 2, CT showed soft tissue in the left middle ear with destruction of the left medial petrous pyramid, the foramen lacerum, the foramen spinosum, and the anterior margin of the jugular foramen (Figs. 2A and B). We believe that in this case the tumor arose from the middle ear and extended into the petrous apex directly or via the eustachian tube. The ossicles were intact. The presence of relatively intact ossicles should not dissuade the radiologist from considering the epicenter of a rhabdomyosarcoma to be located in the middle ear. It is possible that because the ossicles are relatively mobile, they tend to be displaced and surrounded by tumor rather than invaded and destroyed. Three-month follow-up CT after chemo- and radiation therapy showed some remineralization of the petrous apex and decreasing size of the soft tissues in the middle ear (Fig. 2C).

In our opinion, CT and MR play an equally important role in the diagnostic workup of patients with suspected or known rhabdomyosarcomas of the middle ear. CT shows bone destruction in exquisite detail; MR better evaluates extension through the eustachian tube and/or intra/subcranial tumor involvement.

## References

1. Hasso AN, Vignaud J, Bird CR. Pathology of the temporal bone and mastoid. In: Newton TH, Hasso AN, Dillon WP, eds. *Computed tomography of the head and neck*. 1st ed. New York: Raven, 1988:5-9
2. Goepfert H, Gangir A, Lindberg R, et al. Rhabdomyosarcoma of the temporal bone: is surgical resection necessary? *Arch Otolaryngol* 1979;105:310-313
3. Lo WWM. Tumors of the temporal bone and the cerebellopontine angle. In: Som PM, Bergeron RT, eds. *Head and neck imaging*. 2nd ed. St. Louis: Mosby Year Book, 1991:1078
4. Schwartz RH, Movassaghi N, Marion ED. Rhabdomyosarcoma of the middle ear: a wolf in sheep's clothing. *Pediatrics* 1980;65:1131-1133
5. Batsakis JG. *Tumors of the head and neck, clinical and pathological considerations*. 2nd ed. Baltimore: Williams & Wilkins, 1979:280-288
6. Malogolowkin MH, Ortega JA. Rhabdomyosarcoma of childhood. *Pediatr Ann* 1988;17:251-268
7. Latack JT, Hutchinson RJ, Heyn RM. Imaging of rhabdomyosarcomas of the head and neck. *AJNR: Am J Neuroradiol* 1987;8:353-359
8. Canalis RR, Gussen R. Temporal bone findings in rhabdomyosarcoma with predominantly petrous involvement. *Arch Otolaryngol* 1980;106:290-293
9. Yousem DM, Lexa FJ, Bilaniuk LT, Zimmerman RI. Rhabdomyosarcomas in the head and neck: MR imaging evaluation. *Radiology* 1990;177:683-686