



Get Clarity On Generics

Cost-Effective CT & MRI Contrast Agents



FRESENIUS
KABI

WATCH VIDEO

AJNR

CT and MR in infants with pericerebral collections and macrocephaly: benign enlargement of the subarachnoid spaces versus subdural collections.

G Wilms, G Vanderschueren, P H Demaerel, M H Smet, F Van Calenbergh, C Plets, J Goffin and P Casaer

This information is current as of August 6, 2025.

AJNR Am J Neuroradiol 1993, 14 (4) 855-860
<http://www.ajnr.org/content/14/4/855>

CT and MR in Infants with Pericerebral Collections and Macrocephaly: Benign Enlargement of the Subarachnoid Spaces versus Subdural Collections

G. Wilms,^{1,4} G. Vanderschueren,¹ P. H. Demaerel,¹ M.-H. Smet,¹ F. Van Calenbergh,² C. Plets,² J. Goffin,² and P. Casaer³

PURPOSE: To compare CT and MR in the differentiation of benign enlargement of the subarachnoid spaces and subdural collections in infants with macrocephaly. **METHODS:** MR was performed in 19 infants with macrocephaly, showing bifrontal enlargement of the subarachnoid spaces on CT. **RESULTS:** In 11 patients, a single fluid layer could be distinguished on MR of the pericerebral collections, suggesting benign enlargement of the subarachnoid spaces. In eight patients, two separate layers were clearly differentiated, an outer layer that was hyperintense on all sequences and an inner layer with the same intensity as the cerebrospinal fluid. This indicated the presence of subdural collections. These collections were mainly frontal in six and extended over the entire hemisphere in two patients. On CT, these separate lesions were seen only in three patients and missed in three others. In two final patients, CT findings were equivocal with evidence of membrane formation within the hypodense collections. In seven patients with a subdural collection, subdural-external drainage was performed. In three patients, the collection was hemorrhagic. The protein content of the fluid showed a mean of 1381.7 ± 785.6 mg/dL. The MR and surgical findings of a subdural collection correlated with the absence of a family history of macrocrania, an age under 5 months, and acute clinical signs of vomiting, somnolence, and hypotonia. **CONCLUSION:** MR appears essential in the differential diagnosis between benign enlargement of the subarachnoid spaces and subdural collections in infants.

Index terms: Head, enlargement; Hydrocephalus; Brain, magnetic resonance; Pediatric neuroradiology

AJNR 14:855-860, Jul/Aug 1993

Pericerebral collections in infants have received considerable attention in the pediatric and neurosurgical literature (1-6). The differentiation between benign enlargement of the bifrontal subarachnoid spaces and a pathologic subdural collection is not always possible with computed tomography (CT) (7-10). Nevertheless, this differentiation is of utmost importance because direct subdural drainage or evacuation of the peri-

cerebral collections is necessary only in case of subdural collections with high protein content or in frank hematomas (4, 6, 11). In patients with benign enlargement of the subarachnoid spaces, an operation is not always indicated. Ventriculoperitoneal drainage may be the procedure of choice, if hydrocephalus is associated (5).

The high accuracy of magnetic resonance (MR) in the study of subdural hematomas and hygromas is well known (12, 13). We wish to report our results with MR in the study of pericerebral collections in infants and to give some typical characteristics of the differential diagnosis between benign enlargement of the subarachnoid spaces and subdural collections.

Materials and Methods

MR was performed in 19 children with macrocephaly, defined as excessively rapid increase of head circumference

Received January 31, 1992; accepted after revision September 2.

Presented at the 29th Annual Meeting of the American Society of Neuroradiology, June 9-14, 1991, Washington, DC.

¹Department of Radiology, ²Clinic for Neurology and Neurosurgery, and ³Department of Neuropediatrics, University Hospitals K.U. Leuven, Belgium.

⁴Address reprint requests to Dr G. Wilms, Department of Radiology, University Hospitals K.U. Leuven, Herestraat 49, B-3000, Leuven, Belgium.

AJNR 14:855-860, Jul/Aug 1993 0195-6108/93/1404-0855

© American Society of Neuroradiology

(> 97th percentile) (14) in whom pericerebral collections were found on CT.

There were 10 boys and 9 girls with a mean age of 7.7 ± 4.1 months. CT was performed with Somatom CR and Somatom DRH Scanners (Siemens, Erlangen, Germany). Transverse sections were obtained before (n=19) and after (n=10) intravenous injection of contrast medium. In the posterior fossa, 2-mm sections were obtained. In the supratentorial region, 8-mm sections were obtained.

MR was performed with a 1.5-T superconductive magnet (Magnetom, Siemens, Erlangen, Germany). Transverse T2-weighted (spin-echo (SE) 2500/90/1 (TR/TE/excitations)) and proton density-weighted (SE 2500/22/1) images were obtained. T1-weighted images (SE 600/15/1) were obtained in the transverse, sagittal, and coronal directions.

Benign enlargement of the subarachnoid spaces was diagnosed if only a single clear fluid layer could be seen in the pericerebral collections. Subdural collections were diagnosed if two different components could be differentiated in the pericerebral collection. These findings were correlated with the age of the patients, the medical history, the clinical manifestations, and the evolution.

Results

On CT scan, enlargement of the bifrontal subarachnoid space was seen in all patients. In 14 patients, only fluid density could be discerned at this level (Fig. 1). In three patients, a hyperdense subdural collection was seen that was clearly separated from the subarachnoid space (Fig. 2). In two patients, the findings on contrast-enhanced CT were equivocal with suspicion of membranes

within the collections. Definite diagnosis was possible only in retrospect after viewing the MR (Fig. 3).

On MR in 11 patients (group 1), the enlarged subarachnoid space showed only one layer. This layer displayed the same intensity characteristics as the cerebrospinal fluid (CSF).

In eight patients, a pathologic subdural collection was seen (group 2). In five of these patients, it was bifrontal and symmetrical. In one patient, the frontal collection was minimal on the left side, while on the right it was more voluminous. In two patients, the subdural collection extended bilaterally over the entire hemispheres (Fig. 4). In these eight patients, two distinct layers were seen. The inner layer showed the same intensity as CSF. The outer layer was hyperintense on all sequences. Therefore, the collection was clearly visible on proton density- and T1-weighted images. On T2-weighted images, the collection was slightly more intense than the CSF (Fig. 2).

In group 1, surgical drainage was performed in two patients (one ventriculoperitoneal drainage, one lumboperitoneal drainage). The laboratory values of the CSF obtained at the time of shunting were normal. The fluid was clear. In the other nine patients, no treatment was necessary. Repeat CT showed disappearance of the bifrontal collections before the age of 2 in all these patients.

In the eight patients with subdural collections (group 2), surgical intervention was performed in all patients. In seven patients, a bifrontal tempo-

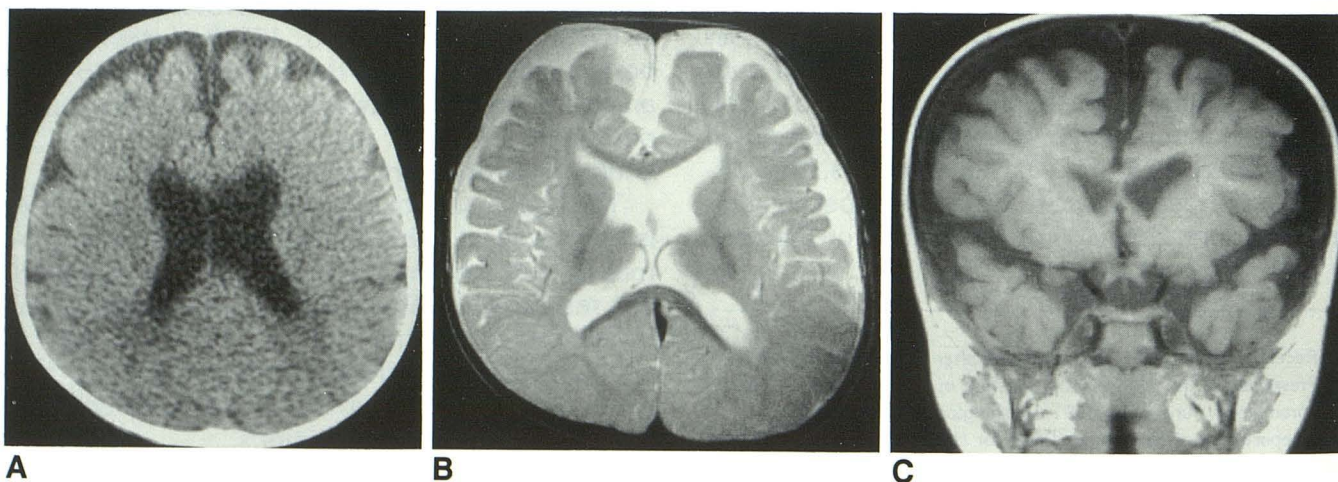


Fig. 1. Benign enlargement of the subarachnoid spaces.

A, CT scan. Slight enlargement of the bifrontal subarachnoid space.

B, MR: transverse T2-weighted (SE 2500/90/1). The enlarged frontal subarachnoid space displays a homogeneous hyperintensity comparable to that of CSF.

C, MR: coronal T1-weighted (SE 600/15/1). In the enlarged subarachnoid space, only one homogeneous CSF compartment is seen.

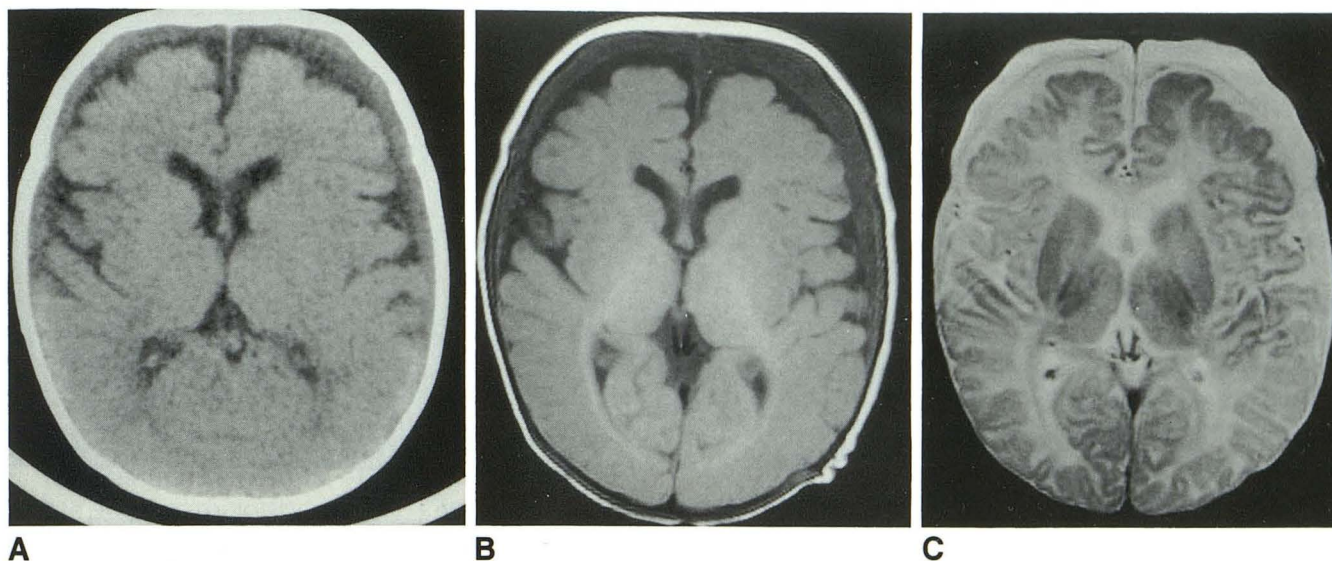


Fig. 2. Subdural collection: positive CT scan.

A, CT scan. Enlargement of the frontal subarachnoid space, with an outer hyperdense and an inner hypodense component.

B, MR: T1-weighted (SE 600/15/1). Clear visualization of both components.

C, MR: T2-weighted (SE 2500/90/1). The outer collection is slightly more intense.

rary subdural-external drainage was performed. In at least two of these patients, neomembrane formation in the subdural collections was reported by the neurosurgeon in the operation report. In the patient with "unilateral" subdural frontal hygroma, a ventriculoperitoneal drainage was performed because of associated important dilatation of the ventricular system. The mean protein content of the drained bifrontal fluid, as determined in six patients, was 1381.7 ± 783.6 mg/dL with an extreme of 3257 mg/dL. In three patients, the erythrocytes as counted in the fluid ranged from 85,000 to 785,000 cells/mm³.

The mean age of the patients was 10.1 ± 3.9 months in group 1 and 4.5 ± 1.1 months in group 2.

In the medical history of group 1, a family history of macrocephaly was reported in five patients and a traumatic birth in one patient.

In group 2 there never was a family history of macrocephaly. In one patient, a recent trauma (fall from the dressing table), and in three patients, a difficult delivery were mentioned. Another patient suffered from a thrombosis of the superior vena cava at the age of 2 months. In three cases, no special events were recorded in the past history.

Besides the macrocephaly in group 1, three patients had psychomotor delay, one patient facial asymmetria, and one patient nystagmus. Six patients had no other clinical signs.

In group 2, three patients presented with vomiting, hypotonia, and somnolence. In the patient with acute trauma, anisocoria was noted. In four patients, no other clinical signs except the macrocephaly were noted.

In the late evolution from group 1, the psychomotor delay persisted in three patients. The other eight patients and all patients of group 2 had a normal evolution. The bifrontal collections resolved well in all patients. As mentioned above, the enlargement of the bifrontal subarachnoid space resolved well in the patients of group 2.

Discussion

There is much confusion and controversy in the neuroradiologic, neurosurgical, and neuropathologic literature about the terminology in patients with reversible enlargement of the bifrontal subarachnoid space on CT scan, as well as in patients with pathologic subdural collections that are candidates for neurosurgical drainage.

The former are designated as benign subdural collections of infancy (1), benign extraaxial collections of infancy (2), benign enlargement of the subarachnoid spaces (3), benign communicating hydrocephalus (7), benign subdural effusions (8), benign subdural collections of infancy (9), or external hydrocephalus (10, 15). We have used the descriptive term *benign enlargement of the*

Fig. 3. Bifrontal subdural collection: equivocal CT scan.

A, CT scan. Bilateral enlargement of the frontal subarachnoid space, most pronounced on the left. On the left there is suspicion of membrane formation (*arrowheads*).

B, MR: T2-weighted (SE 2500/90/1). The intensity of the outer collection is somewhat higher than that of CSF.

C, MR: proton density-weighted images (SE 2500/15/1). Clear visualization of bilateral frontal hyperintense subdural effusion. At the inner aspect of the collection some residual normal CSF is seen.

D, MR: parasagittal T1-weighted (SE 600/15/1). Thick hyperintense peripheral collection over both hemispheres.

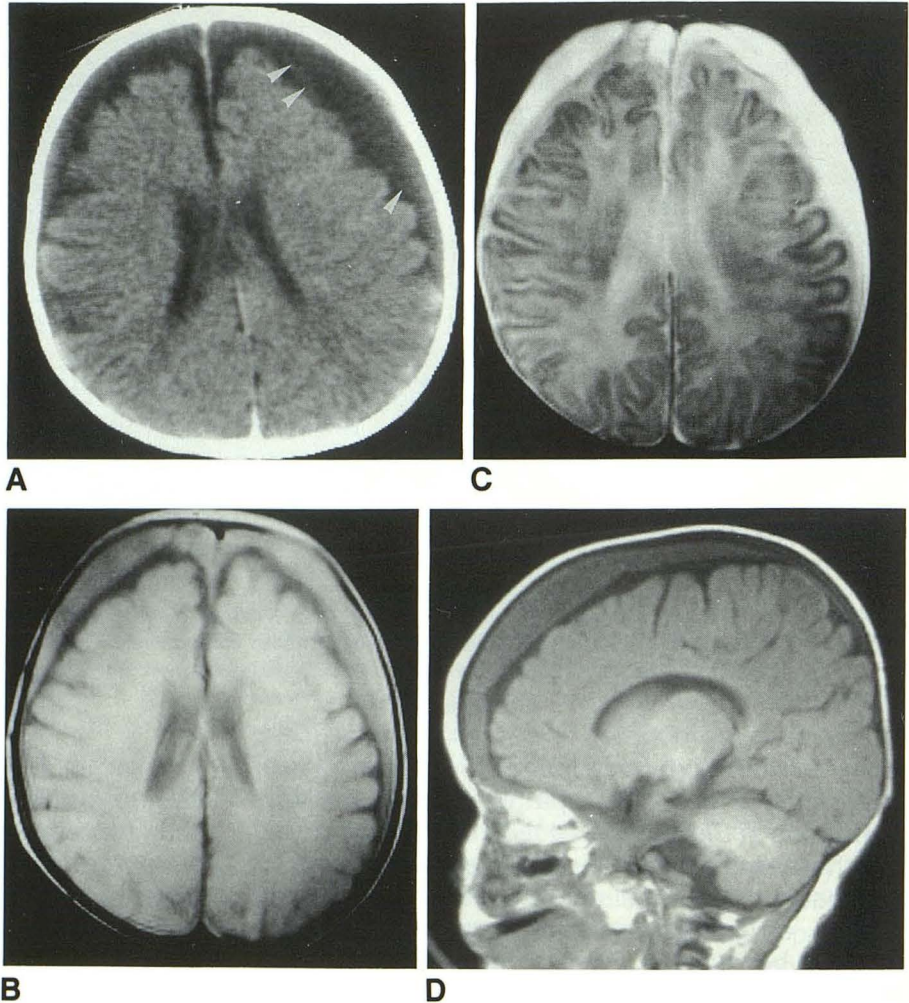
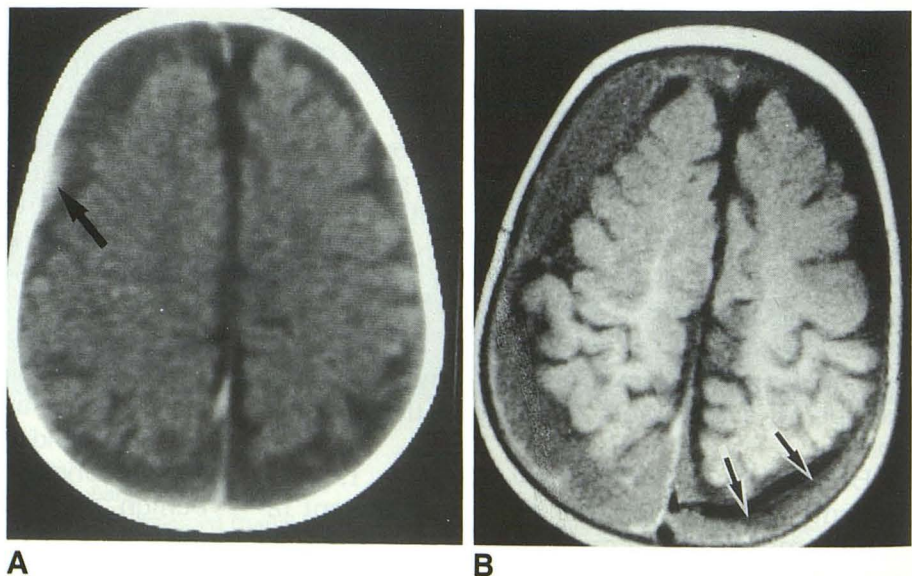


Fig. 4. Subdural collection over both hemispheres.

A, CT scan. Diffuse enlargement of the pericerebral subarachnoid space, suggesting atrophy. Presence of some hyperdense material (*arrow*) adjacent to the skull in the right frontal area.

B, MR: T1-weighted (SE 600/15/1). Huge pericerebral collection over the entire right hemisphere. Lesion is less pronounced on the left (*arrows*).



subarachnoid spaces, proposed by Nickel and used by Barkovich in the radiologic literature (16).

All these terms refer to dilatation of the subarachnoid space without severe dilatation of the ventricles in children with excessively rapid head growth and with communication between the subarachnoid space and the ventricles (1–3, 5, 7–10). Disturbance in the resorption of the CSF at the level of Pacchioni's granulations, possibly caused by delayed maturation of the arachnoid villi (16), leads to dilatation of all subarachnoid spaces. On CT scan, enlargement of the basal cisterns, the interhemispheric fissure, and the bifrontal subarachnoid space is seen (5, 7–10).

The clinical condition of the patients remains stable in the majority of the cases (1–3), with normal development, although gross motor delay can be found in individual cases (7).

The CT-scan abnormalities tend to resolve within 18 to 24 months (7), together with the normalization of the head circumference (2). This form of macrocephaly is familial in up to 88% of the cases (15). Because of the good prognosis and the favorable clinical evolution, neurosurgical treatment is seldom indicated. A direct evacuation of the subarachnoid fluid is not useful, and ventriculoperitoneal or lumboperitoneal shunting can be performed in selected cases with gross motor delay, intracranial hypertension, important hydrocephalus, huge collections, or gross abnormalities of CSF migration on cisternography (1–4, 7–9).

Pathologic collections are referred to as subdural hematoma (4, 6, 12, 13) if the collections contain gross blood or if the red-blood-cell count exceeds 1 million/mL³ (9). If the fluid of the collections is xanthochromic, with a protein content of more than 40 mg/dL higher than that of the lumbar CSF, the term subdural effusion is used, pointing to collections that are posttraumatic, postinflammatory, or of uncertain etiology (7, 9).

With CT, it is usually impossible to differentiate between both conditions (7, 9). First, there is no difference in density between clear fluid and chronic hemorrhage. Furthermore, plain CT cannot differentiate between a subdural and a subarachnoid localization of the fluid. Therefore, the terms "benign subdural effusions" (8) and "benign subdural collections" (9) have been used to designate both the bifrontal subarachnoid collection of communicating hydrocephalus as well as the xanthochromic fluid of subdural collections or chronic subdural hematoma. Both conditions are

described in patients with a history of postnatal trauma, infection, premature or traumatic birth, and raised venous pressure, as well as in patients without one of these antecedents (4). Before the introduction of MR, the differential diagnosis was based on isotope brain scintigraphy or isotope cisternography. On CT scan after intrathecal injection of contrast medium, benign enlarged subarachnoid spaces opacify entirely, while in subdural collections the outer component is not opacified (1, 5, 17).

In a preliminary study, we reported hopeful results with MR in the differentiation between benign enlargement of the subarachnoid spaces and subdural collections (18). This study confirms that with MR, this differential diagnosis has become easy. In the former condition, the brain is surrounded by one compartment, with a signal equal to that of CSF. In the latter, two components are seen on MR. The inner compartment has the same signal as CSF; the outer component has a higher signal than CSF on T1-weighted and proton density SE sequences and remains hyperintense on T2-weighted sequences. The signal characteristics of the subdural collection are compatible with subacute or chronic hemorrhage (12). These hemorrhages are hyperintense to CSF on all sequences, as in intraparenchymal hemorrhage, but hemosiderin deposition does not occur, probably because the absence of a blood-brain barrier allows clearance and dilution of blood products (12).

At surgery, in three of our patients, the collections contained a high erythrocyte count. Despite the fact that in only one of these patients a recent trauma was known and that in two others a history of difficult delivery dated from more than 4 months, it is highly probable that the shortening of T1 was due to subacute or chronic hemorrhage with methemoglobin formation.

It is theoretically possible that in the other five patients of group 2, the signal intensity changes on MR are also caused by chronic hemorrhage. This hypothesis can be clinically sustained in one patient with a traumatic birth and in the patient with superior vena cava thrombosis, with possible hemorrhagic complications. Nevertheless, in three patients there are no traumatic antecedents. It is known that proteinaceous fluids can cause strong T1 shortening (19). The mean protein content of the drained fluid in six of our patients of group 2 was very high, with an extreme of 3257 mg/dL. Therefore, this high protein content could be at the base of the T1 shortening and

could point to a postinflammatory origin of the collections.

MR appears to be essential in the radiologic investigation of children with macrocephaly, in order to differentiate between benign enlargement of the subarachnoid spaces and subdural collections. In the latter case, subdural external drainage is preferred over other neurosurgical procedures. Besides the MR findings, absence of a family history of macrocephaly, an age under 5 months, evidence of membrane formation on CT, or equivocal CT findings together with acute clinical signs should further suggest a subdural collection.

References

1. Brinner S, Bodensteiner J. Benign subdural collections of infancy. *Pediatrics* 1980;67:802-804
2. Carolan PL, McLaurin RL, Tobin RB, Tobin JA, Egelhoff JC. Benign extraxial collections in infancy. *Pediatr Neurosci* 1986;12:140-144
3. Nickel RE, Gallenstein JS. Developmental prognosis for infants with benign enlargement of the subarachnoid spaces. *Dev Med Child Neurol* 1987;29:181-186
4. Aoki N, Mizutani H, Masuzawa H. Unilateral subdural-peritoneal shunting for bilateral chronic subdural hematomas in infancy. *J Neurosurg* 1985;63:134-137
5. Plets C, Van Calenbergh F. Les collections péricérébrales: analyse des examens neuroradiologiques, et isotopiques, et des résultats thérapeutiques. *Neurochirurgie* 1989;35:390-394
6. Maheut J, Bartmez MA, Billard C, Rondeau C, Santini JJ. L'hématome sous-dural du nourrisson: indications et résultats de la déviation sous-durale externe. *Neurochirurgie* 1989;35:401-403
7. Kendall B, Holland I. Benign communicating hydrocephalus in children. *Neuroradiology* 1981;21:93-96
8. Mori K, Handa H, Itoh M, Okuno T. Benign subdural effusion in infants. *J Comput Assist Tomogr* 1980;4:466-471
9. Robertson WC, Chun RWM, Orrison RWW, Sackett JF. Benign subdural collections of infancy. *J Pediatr* 1979;94:382-385
10. Maytal J, Alvarez LA, Elkin CM, Shinnar S. External hydrocephalus: radiologic spectrum and differentiation from cerebral atrophy. *AJNR: Am J Neuroradiol* 1987;8:271-278
11. Tsubokana T, Nakamura, Sato K. Effect of temporary subdural-peritoneal shunt in subdural effusion with subarachnoid effusion. *Child's Brain* 1984;11:47-59
12. Fobben ES, Grossman RI, Atlas SW, et al. MR characteristics of subdural hematomas and hygromas at 1.5 T. *AJNR: Am J Neuroradiol* 1989;10:687-693
13. Sipponen JT, Sepponen RE, Sivula AS. Chronic subdural hematoma: demonstration by magnetic resonance. *Radiology* 1984;150:79-85
14. Weaver D, Christian J. Familial variation of head size and adjustment for parental head circumference. *J Pediatr* 1980;96:990-994
15. Alvarez LA, Majtaz S, Shinnar S. External hydrocephalus: natural history and relationship to familial macrocephaly. *Pediatrics* 1986;77:901-907
16. Barkovich AJ. Hydrocephalus. In: *Pediatric neuroimaging*. New York: Raven Press, 1990;7:220-221
17. Enzmann DR, Norman D, Price DC, Newton TH. Metrizamide and radionuclide cisternography in communicating hydrocephalus. *Radiology* 1979;130:681-686
18. De Vries LS, Smet M, Ceulemans B, et al. The role of high resolution ultrasound and MRI in the investigation of infants with macrocephaly. *Neuropediatrics* 1990;21:72-75
19. Fullerton GD. Physiologic basis of magnetic relaxation. In: Stark DD, Bradley WG, eds. *Magnetic resonance imaging*. St. Louis: Mosby, 1988:36-55