



Get Clarity On Generics

Cost-Effective CT & MRI Contrast Agents



FRESENIUS
KABI

WATCH VIDEO

AJNR

Detection of recurrent thyroid cancer: MR versus thallium-201 scintigraphy.

T Ohnishi, S Noguchi, N Murakami, S Jinnouchi, H Hoshi, S Futami and K Watanabe

AJNR Am J Neuroradiol 1993, 14 (5) 1051-1057

<http://www.ajnr.org/content/14/5/1051>

This information is current as
of August 13, 2025.

Detection of Recurrent Thyroid Cancer: MR versus Thallium-201 Scintigraphy

Takashi Ohnishi,¹ Shiro Noguchi,¹ Nobuo Murakami,¹ Seishi Jinnouchi,² Hiroaki Hoshi,² Shigemi Futami,² and Katsushi Watanabe²

PURPOSE: To compare MR with thallium-201 scintigraphy in the follow-up of patients who have undergone thyroidectomy and modified radical neck dissection for differentiated thyroid cancer. **METHODS:** Both MR imaging and ²⁰¹Tl scintigraphy were performed in 39 patients after surgery for differentiated thyroid cancer. Ten patients did not have recurrence; 29 patients had 51 recurrent tumors in the neck and mediastinum. **RESULTS:** Among 51 tumor sites, 39 sites of recurrence were detected by MR and 24 were detected by ²⁰¹Tl scintigraphy. The true-positive rate, false-negative rate, true-negative rate, and false-positive rate in detecting recurrent thyroid cancer were 76.5, 23.5, 100, and 0%, respectively, for MR and 47.1, 52.9, 100, and 0%, respectively, for ²⁰¹Tl scintigraphy. MR was more sensitive than ²⁰¹Tl scintigraphy in detecting recurrent tumors (especially small metastatic nodes). On T2-weighted MR images, recurrent tumor was characterized by high signal intensity. Scarring in the postoperative thyroid bed was characterized by low signal intensity on both T1- and T2-weighted images. Abnormal accumulation of ²⁰¹Tl in the postoperative thyroid bed was not observed. **CONCLUSIONS:** Although both MR images and ²⁰¹Tl scintigraphy were effective in distinguishing recurrent tumor from postoperative fibrous tissue, MR images were more sensitive than ²⁰¹Tl scintigraphy in detecting recurrent tumors. These results suggest that MR imaging is more useful than ²⁰¹Tl scintigraphy in the follow-up evaluation of patients after neck surgery for differentiated thyroid cancer.

Index terms: Thyroid gland, neoplasms; Neck, magnetic resonance; Neck, radionuclide studies; Radionuclide imaging, comparative studies; Magnetic resonance, comparative studies

AJNR 14:1051-1057, September/October 1993

Magnetic resonance (MR) imaging has been shown to be effective in demonstrating the extent and invasiveness of thyroid tumors (1, 2). The differentiation of recurrent tumor from scar tissue after surgery is important in the evaluation of patients who have undergone neck surgery. Recently, Aufermann et al reported the usefulness of MR imaging for detecting recurrent thyroid cancer, and they concluded that recurrent thyroid cancer and postoperative fibrosis could be differentiated on MR imaging (3). Other techniques

such as radioiodine scintigraphy, thallium-201 scintigraphy, and ultrasonography have been widely used for the follow-up and management of patients with differentiated thyroid cancer (DTC) (4-9). Radioiodine scintigraphy is said to be sensitive in detecting normal residual thyroid tissue and recurrent tumor postoperatively, but cannot differentiate local recurrent tumor from normal thyroid bed after thyroidectomy (4, 5). Ultrasonography does not allow differentiation of recurrent tumor or fibrosis unless guided biopsy of this tissue is done (8, 9). We performed both MR imaging and ²⁰¹Tl scintigraphy in patients who had previously undergone thyroidectomy and modified radical neck dissection for DTC, and we evaluated the capabilities of MR imaging in comparison with ²⁰¹Tl scintigraphy in the detection of recurrent thyroid cancer and the differentiation of tumor from normal postoperative bed after thyroidectomy.

Received February 11, 1992; revision requested April 23; final revision received August 17 and accepted November 3.

¹ Noguchi Thyroid Clinic and Hospital Foundation, Beppu, Oita, Japan 874, and ²Department of Radiology, Miyazaki Medical College, Miyazaki, Japan 889-16.

Address reprint requests to: Takashi Ohnishi, Noguchi Thyroid Clinic and Hospital Foundation, 6-33 Noguchi Nakamachi, Beppu, Oita, Japan 874.

AJNR 14:1051-1057, Sep/Oct 1993 0195-6108/93/1405-1051

© American Society of Neuroradiology

Materials and Methods

We studied 39 patients (mean age, 56 years; 25 women and 14 men) who had undergone subtotal thyroidectomy and modified radical neck dissection for DTC (36 papillary adenocarcinoma, two medullary carcinoma, and one follicular adenocarcinoma). The mean interval between thyroidectomy and our studies was 6.8 years (range, 1 to 20 years). The diagnosis of recurrent thyroid cancer was based on serum thyroglobulin measurements, palpitation, ultrasonography, ^{201}Tl scintigraphy, MR imaging, and fine-needle aspiration biopsy. Twenty-nine patients had suspected recurrence by these tests. All patients with suspected recurrence underwent operations. Sixteen patients without evidence of recurrence underwent surgery for resection of recurrent tumors in the lateral neck. Fibrous tissue in the thyroid bed was confirmed in these patients by intraoperative findings.

Fifty-one recurrent tumors were confirmed by surgery (Table 1). We evaluated the images of these 51 recurrent tumors and 26 postoperative thyroid beds without recurrent tumors (10 thyroid beds that were confirmed to be tumor negative by fine-needle aspiration biopsy, and 16 thyroid beds that were confirmed to be tumor negative by surgery).

MR imaging and ^{201}Tl scintigraphy technique

MR imaging was obtained by the use of a 0.5-T superconductive MR system (Toshiba MRT-50A; Toshiba, Tokyo, Japan) with a surface coil for the neck or a surface coil for the thyroid. Studies consisted of spin-echo images obtained in the axial plane with short (T1-weighted, 400 to 500/15 to 20 [repetition time/echo time]) and long (T2-weighted, 2000 to 2900/80, cardiac-gated) sequences. T1-weighted images were obtained with two acquisitions and a 256×256 double matrix or with 4 acquisitions and a 256×256 matrix. T2-weighted images were obtained with one acquisition and a 256×256 double matrix or two acquisitions and a 256×256 matrix. In both sequences, section thickness was 5 mm with an intersection gap of 1 mm. MR images were analyzed retrospectively to determine the signal characteristics of the "normal" thyroid bed after thyroidectomy and recurrent tumors, respectively, on T1-weighted and T2-weighted images. A lymph node larger than 10 mm in diameter was considered abnormal. Signal intensities of tissue were defined qualitatively as follows; high-intensity tissues were those with signal equal to or greater than that of fat; medium-intensity tissues were those with signal greater than that of muscle but less than that of fat; and low-intensity tissues were those with signal equal to or less than that of muscle. ^{201}Tl scintigraphy was obtained after an intravenous injection of 74 MBq of [^{201}Tl] chloride. Neck scans and chest scans were performed 10 minutes after the injection by the use of a gamma-camera system (SNC500R; Shimadzu, Kyoto, Japan), equipped with a low-energy, high-resolution collimator with 20% windows. The acquisition time was 10 minutes. ^{201}Tl scintigraphy was read as positive when increased focal activity was present with respect to background activity.

Results

A comparison of the results of MR images and ^{201}Tl scintigraphy is summarized in Table 2. Among 51 recurrent tumors, 39 were detected with MR imaging and 24 were detected with ^{201}Tl scintigraphy. MR images and ^{201}Tl scintigraphy were equally sensitive in detecting recurrent tumors in the remnant lobe (three of three). On the other hand, MR images were more sensitive than ^{201}Tl scintigraphy in detecting recurrent tumor in the lateral neck (MR images, 21 of 32; ^{201}Tl scintigraphy, 10 of 32), paratracheal area (MR images, 10 of 12; ^{201}Tl scintigraphy, 7 of 12), and mediastinum (MR images, four of four; ^{201}Tl scintigraphy, three of four). This difference was dependent on the size of the tumors (Fig 1). Both MR images and ^{201}Tl scintigraphy were sensitive in detecting large tumors (larger than 20 mm in the greatest diameter). All 12 tumors larger than 20 mm were detected with MR images. ^{201}Tl scintigraphy could detect 10 of these 12 tumors (20 to 30 mm, five of seven; 30 to 40 mm, four of four; >40 mm, one of one). Twenty-seven of 39 tumors smaller than 20 mm were detected with MR images (<5 mm, zero of three; 5 to 10 mm, zero of eight; 10 to 15 mm, nine of 10; 15 to 20 mm, 18 of 18). In these tumors, ^{201}Tl scintigraphy could detect only 14 tumors (<5 mm, zero of three; 5 to 10 mm, zero of eight; 10 to 15 mm, one of 10; 15 to 20 mm, 13 of 18).

TABLE 1: Materials

Characteristics	No. of Lesions
Recurrent tumor	51
Lateral neck	32
Paratracheal	12
Mediastinum	4
Remnant	3
Nontumorous postoperative thyroid bed	26
Confirmed by surgery	16
Confirmed by fine-needle aspiration biopsy	10
Total	77

TABLE 2: Comparison of results with MR imaging and ^{201}Tl scintigraphy

	No. of Lesions	No. Positive with MR	No. Positive with ^{201}Tl
Recurrence	51	39	24
Lateral neck	32	21	10
Paratracheal	12	10	7
Mediastinum	4	4	3
Remnant	3	3	3
Nontumorous thyroid bed	26	0	0

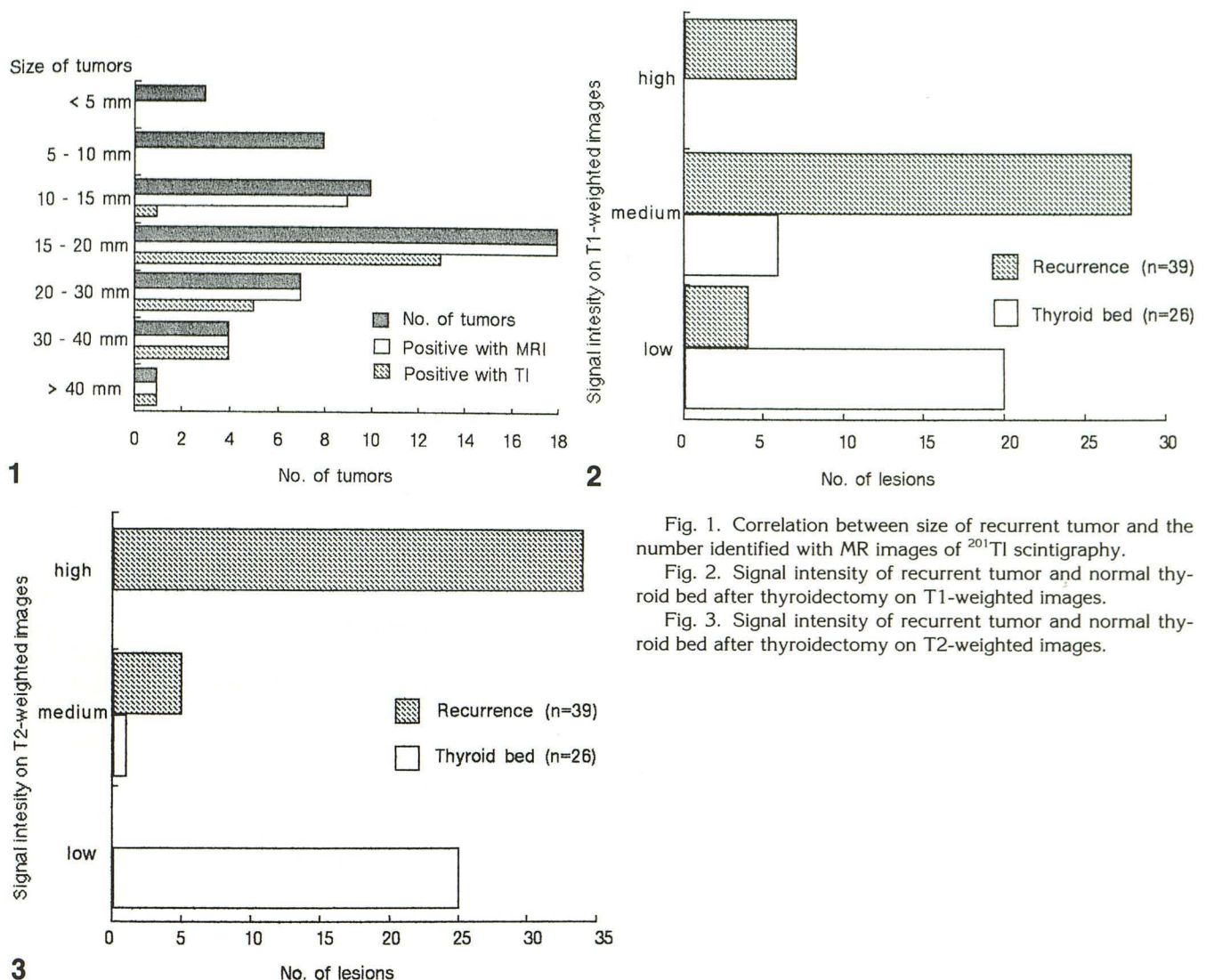


Fig. 1. Correlation between size of recurrent tumor and the number identified with MR images of ^{201}Tl scintigraphy.

Fig. 2. Signal intensity of recurrent tumor and normal thyroid bed after thyroidectomy on T1-weighted images.

Fig. 3. Signal intensity of recurrent tumor and normal thyroid bed after thyroidectomy on T2-weighted images.

MR images were more sensitive than ^{201}Tl scintigraphy in detecting small recurrent tumors (smaller than 20 mm), and ^{201}Tl scintigraphy could not detect the recurrent tumors that were smaller than 15 mm in the largest diameter. The true-positive rate, false-negative rate, true-negative rate, and false-positive rate in detecting recurrent thyroid cancer were 76.5, 23.5, 100, and 0%, respectively, for MR imaging and 47.1, 52.9, 100, and 0%, respectively, for ^{201}Tl scintigraphy.

Figures 2 and 3 show the signal intensity of recurrent tumor and normal thyroid bed after thyroidectomy on T1- and T2-weighted images, respectively. On T1-weighted images, 28 of 39 recurrent tumors showed medium intensity, four tumors showed low intensity, and seven tumors showed high intensity. On T2-weighted images, recurrent tumors demonstrated a high-intensity mass in 34 tumors and a medium-intensity mass

in five tumors. Recurrent tumor was characterized on MR images by medium to high intensity on T1-weighted images and high intensity on T2-weighted images (Figs 4 and 5). The normal thyroid beds after thyroidectomy demonstrated low intensity in 20 sites and medium intensity in six sites on T1-weighted images and low intensity in 25 sites and medium intensity in one site on T2-weighted images (Figs 2 and 3). The normal thyroid bed after thyroidectomy without recurrence was characterized by a small peritracheal rim of low-intensity tissue on T1-weighted and T2-weighted images (Figs 6 and 7).

Discussion

The differentiation of recurrent tumor from postoperative scar tissue is important in the care of patients who have undergone prior surgery for

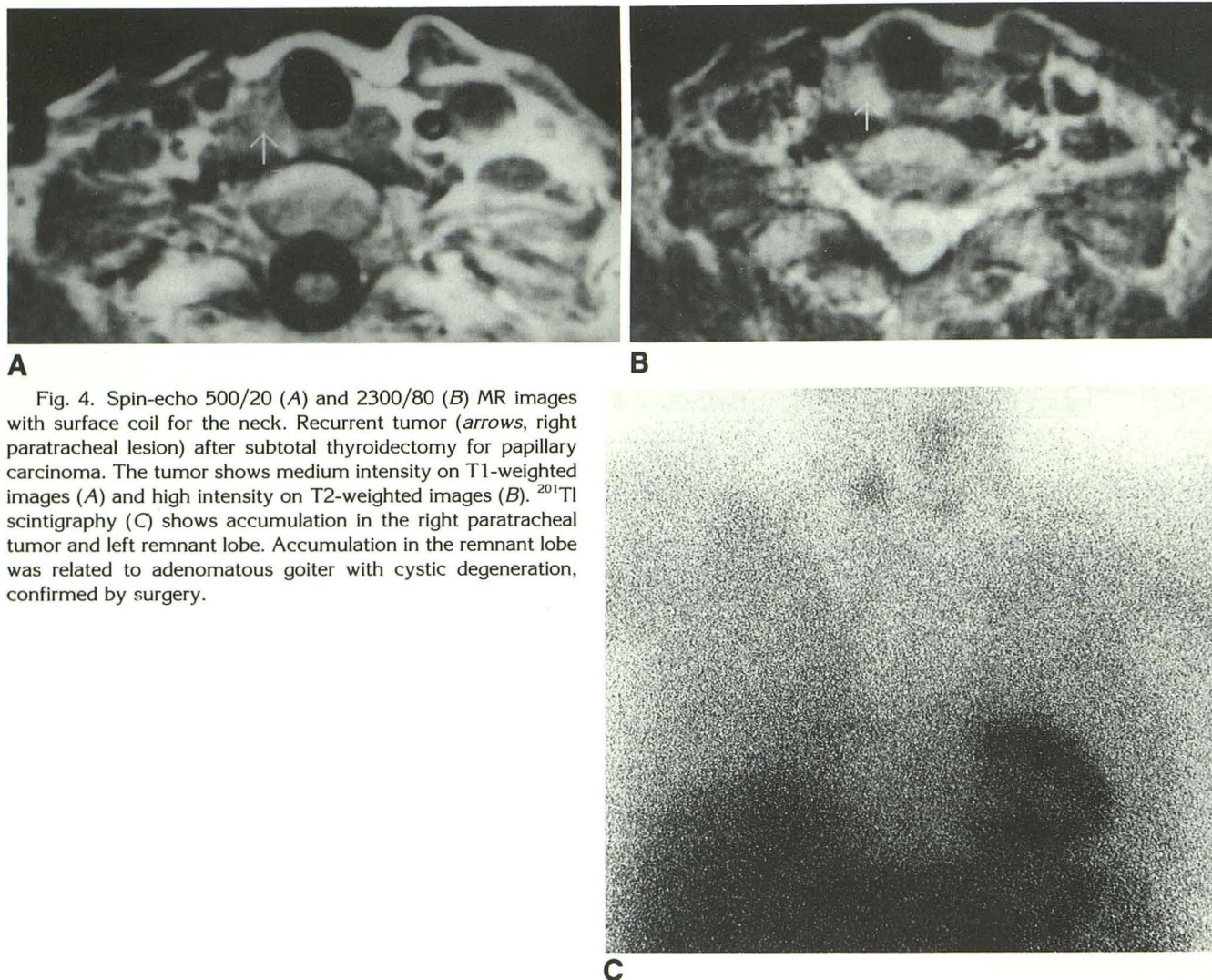


Fig. 4. Spin-echo 500/20 (A) and 2300/80 (B) MR images with surface coil for the neck. Recurrent tumor (arrows, right paratracheal lesion) after subtotal thyroidectomy for papillary carcinoma. The tumor shows medium intensity on T1-weighted images (A) and high intensity on T2-weighted images (B). ²⁰¹Tl scintigraphy (C) shows accumulation in the right paratracheal tumor and left remnant lobe. Accumulation in the remnant lobe was related to adenomatous goiter with cystic degeneration, confirmed by surgery.

malignant tumors. In the mediastinum, abdomen, and pelvis, recurrent tumor and fibrous tissue could be differentiated in MR images (10, 11). Aufermann et al reported the usefulness of MR imaging for detecting recurrent thyroid cancer, and they concluded that recurrent thyroid cancer and postoperative fibrosis could be differentiated MR imaging (3). That report stated that the recurrence of cancer was characterized by low to medium signal intensity on T1-weighted images and medium to high intensity on T2-weighted images. Fibrous tissue after surgery showed low intensity on both T1-weighted and T2-weighted images (3, 10, 11). In our study, recurrent tumor showed various intensity on T1-weighted images and medium to high intensity on T2-weighted images. Fibrosis in the normal thyroid bed after surgery had low intensity on both T1-weighted and T2-weighted images. A high-intensity mass

on T2-weighted images strongly suggested recurrent tumor, whereas a low-intensity structure surrounding the trachea on both T1- and T2-weighted images suggested postoperative fibrous tissue. The results of this study are generally in agreement with the results of previous reports. We think that MR images, especially T2-weighted images, are effective in distinguishing recurrent tumor from scarring in the normal thyroid bed after thyroidectomy.

In our study, seven recurrent tumors showed high intensity on T1-weighted images. Usually, thyroid cancer showed low to medium intensity on T1-weighted images (1–3). This discrepancy may be explained by bleeding, which was caused by fine-needle aspiration biopsy before MR examination in our study. ²⁰¹Tl scintigraphy was also effective in distinguishing large recurrent tumor (larger than 20 mm in the largest diameter)

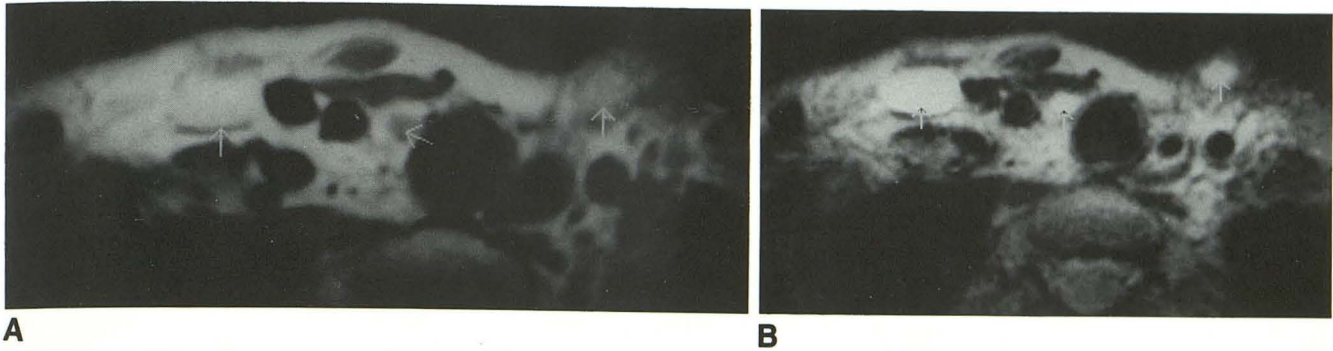


Fig. 5. Spin-echo 400/15 (A) and 2250/80 (B) MR images with surface coil. Recurrent papillary adenocarcinomas (arrows) in the cervicothoracic junction showed medium or high intensity on T1-weighted images (A) and high intensity on T2-weighted images (B). The fine-needle aspiration biopsy was done before the MR study in this patient. High intensity on T1-weighted image may be explained by bleeding caused by the fine-needle aspiration biopsy. Abnormal accumulation in these tumors was not observed on ^{201}Tl scintigraphy (C).

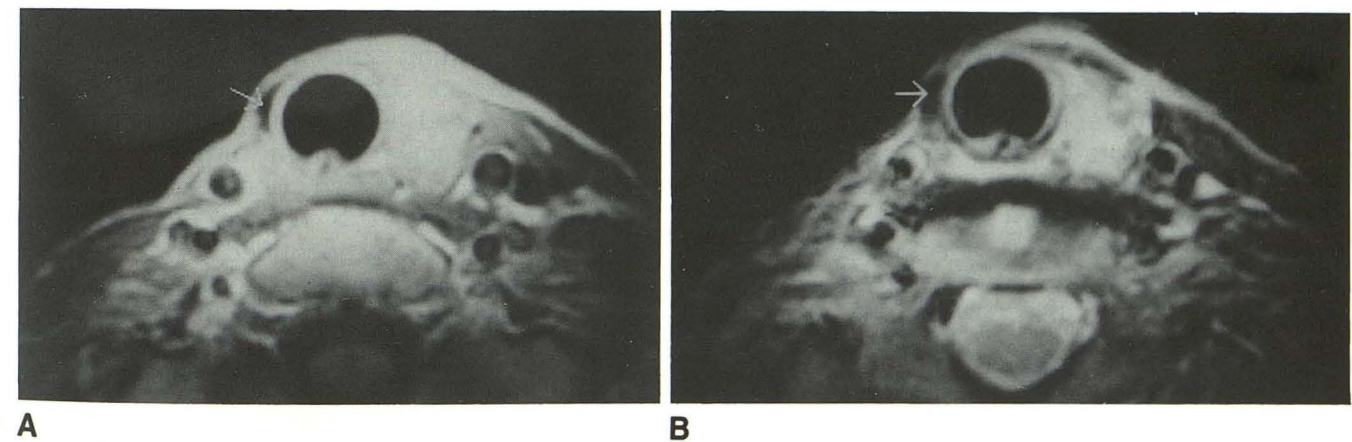
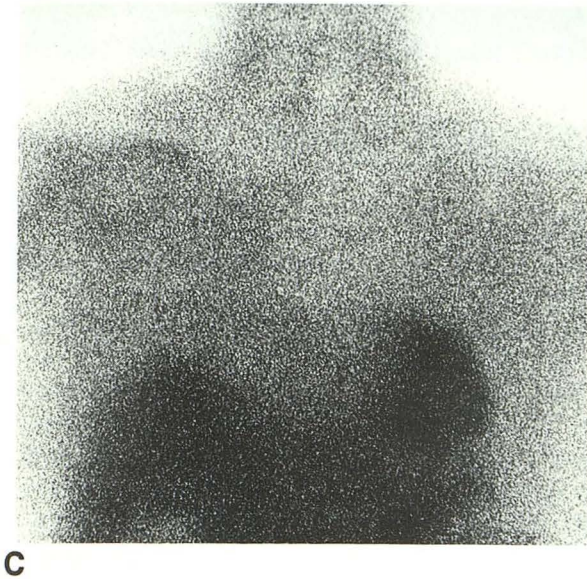


Fig. 6. Spin-echo 400/15 (A) and 2400/80 (B) MR images with surface coil. Postoperative fibrous tissue (arrows) shows low intensity on both T1- and T2-weighted images.

from normal thyroid bed after thyroidectomy. Other methods for monitoring thyroid cancer, such as ^{131}I scintigraphy and ultrasonography, do not allow differentiation of local recurrent tumor and paratracheal tumor from the postoperative thyroid bed (5, 8, 9). We believe that MR images and ^{201}Tl scintigraphy are the most useful meth-

ods for the evaluation of local recurrence and paratracheal tumor.

Opinions on the efficiency of MR images for the diagnosis of recurrent thyroid cancer have varied. Beierwaltes did not use computed tomographic scanning and MR imaging in patients who had modified neck dissection because most of

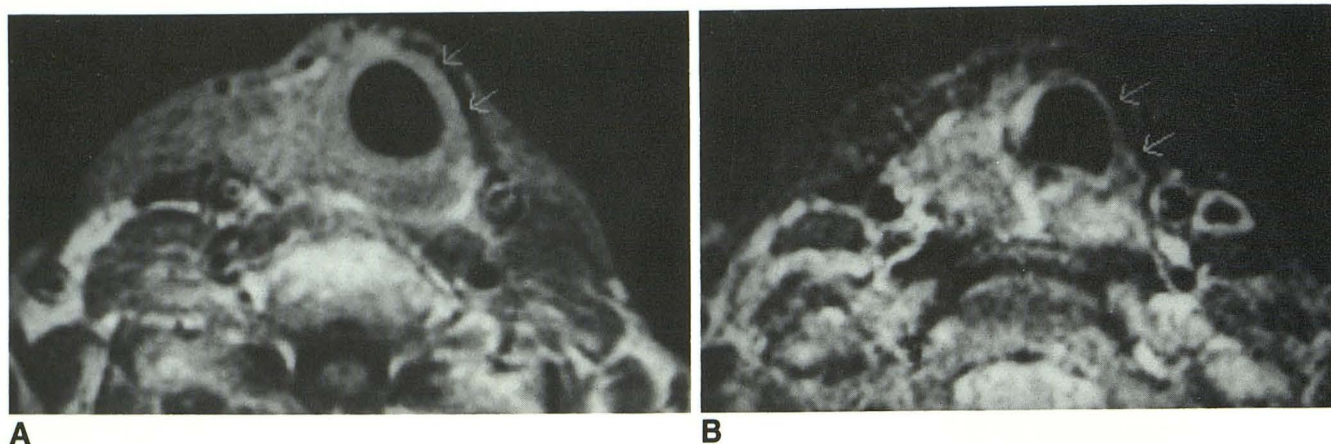


Fig. 7. Spin-echo 500/20 (A) and 2000/80 (B) MR images of scarring in the left thyroid bed (arrow) after left thyroidectomy for papillary thyroid carcinoma. Fibrous tissue shows low intensity on both T1- and T2-weighted images.

them showed enlarged nodes that are usually read as "benign lymphocytic hyperplasia" (12). Although it is true that MR may not differentiate recurrent tumor from inflammatory lymphoid hyperplasia (3), all recurrent tumors in our patients who had modified radical neck dissection showed enlarged nodes by MR images, which we interpreted as neoplastic because the perithyroidal and cervical lymphatic system is a common site of recurrence (13).

Although ^{201}Tl scintigraphy has been reported as a potential means of monitoring patients with DTC who have undergone total or subtotal thyroidectomy, we believe that MR imaging is more useful than ^{201}Tl scintigraphy in the evaluation of small tumors. MR images were more sensitive than ^{201}Tl scintigraphy for detecting recurrent DTC. ^{201}Tl scintigraphy has several advantages over ^{131}I scintigraphy. It does not require post-operative ablation therapy with ^{131}I and thyroid hormone withdrawal. The radiation exposure of ^{201}Tl is smaller than that of ^{131}I . Because of these advantages, ^{201}Tl scintigraphy has been used in our hospital in the follow-up evaluation of DTC patients who have undergone subtotal thyroidectomy and modified radical neck dissection. The sensitivity for ^{201}Tl detection of residual or recurrent DTC is variously reported as 45 to 94% (4–7). Ramana et al reported that ^{201}Tl was more sensitive than ^{131}I diagnostic (185 MBq) studies for the detection of DTC (5). The lowest sensitivity reported by Brendel et al was 45% (4). Brendel et al reported that ^{131}I therapeutic (3,700 to 5,550 MBq) studies were more sensitive than ^{201}Tl scintigraphy, and therefore, ^{201}Tl scintigraphy could not be recommended as the only modality for the follow-up of DTC patients. However, they

described some tumor sites negative with ^{131}I to be positive with ^{201}Tl (especially metastatic cervicomedistinal nodes).

In our study, ^{201}Tl scintigraphy had a high true-negative rate (100%) but a low true-positive rate (47.1%). The tumor sites of our study were mainly cervicomedistinal nodes. Lung, bone, and liver metastasis, which were said to be difficult to detect by ^{201}Tl scintigraphy, did not figure in this study. Two reasons for our low true-positive rate for ^{201}Tl detection of recurrence are considered. First, 32 of 38 recurrent tumors that were evaluated in this study were smaller than 20 mm. We think that ^{201}Tl scintigraphy is not sensitive for detecting small tumors. If the single photon emission computed tomography technique were added as part of ^{201}Tl scintigraphy, detection of small recurrent tumors might be possible. In lung cancer, Tonami et al demonstrated small ($15 \times 10 \times 10$ mm) adenocarcinomas that were clearly identified on ^{201}Tl single photon emission computed tomography (14). Second, most previous studies with ^{201}Tl scintigraphy used a higher dose of ^{201}Tl (111 to 185 MBq) than was used in our study (74 MBq). The dose of tracer in scintigraphic studies is an important factor for the quality of the image. ^{201}Tl scintigraphy for thyroid cancer in Japan is usually performed with 74 MBq of ^{201}Tl . Recently, Iida et al reported high sensitivity for detecting recurrence with 74 MBq of ^{201}Tl (6).

In conclusion, MR images and ^{201}Tl scintigraphy were both effective in distinguishing recurrent DTC from postoperative fibrosis. This is an advantage over ^{131}I scintigraphy, ultrasonography, and palpation. MR images were more sensitive than ^{201}Tl scintigraphy for the detection

of recurrent DTC. We believe that MR imaging is more useful than ^{201}Tl scintigraphy in the follow-up evaluation of patients after neck surgery for DTC.

References

1. Higgins CB, McNamara MT, Fisher MR, et al. MR imaging of the thyroid. *AJR: Am J Roentgenol* 1985;147:1255-1261
2. Geftter WB, Spiritzer CE, Eisenberg B, et al. Thyroid imaging with high-field-strength surface-coil MR. *Radiology* 1987;164:483-490
3. Auffermann W, Clark OH, Thurnher S, et al. Recurrent thyroid carcinoma: characteristics on MR images. *Radiology* 1988;168:753-757
4. Brendel AJ, Guyot M, Jeandot R, et al. Thallium-201 imaging in the follow-up of differentiated thyroid carcinoma. *J Nucl Med* 1988;29:1515-1520
5. Ramanna L, Waxman A, Braunstein. Thallium-201 scintigraphy in differentiated thyroid cancer: comparison with radioiodine scintigraphy and serum thyroglobulin determinations. *J Nucl Med* 1991;32:441-446
6. Iida Y, Hidaka A, Hatabu H, et al. Follow-up study of postoperative patients thyroid cancer by thallium-201 scintigraphy and serum thyroglobulin measurement. *J Nucl Med* 1991;32:2098-2100
7. Hoefnagel CA, Delprat CC, Marcuse HR, et al. Role of thallium-201 total-body scintigraphy in follow-up of thyroid carcinoma. *J Nucl Med* 1986;27:1854-1857
8. Simeone JF, Daniels GH, Hall DA, et al. Sonography in the follow-up of 100 patients with thyroid carcinoma. *AJR: Am J Roentgenol* 1987;148:45-49
9. Gorman B, Charboneau JW, James EM, et al. Medullary thyroid carcinoma: role of high resolution US. *Radiology* 1987;148:146-150
10. Schmidt HC, Tscholakoff D, Hricak H, et al. MR image contrast and relaxation time of solid tumor in the chest, abdomen, and pelvis. *J Comput Assist Tomogr* 1985;9:738-748
11. Ebner F, Kressel HY, Mintz MC, et al. Tumor recurrence versus fibrosis in the female pelvis: differentiation with MR imaging at 1.5T. *Radiology* 1988;166:333-340
12. Beierwaltes WH. Endocrine imaging in the management of goiter and thyroid nodules: Part 1. *J Nucl Med* 1991;32:1455-1461
13. Noguchi S, Murakami N. The value of lymph-node dissection in patients with differentiated thyroid cancer. *Surg Clin North Am* 1987;67:251-261
14. Tonami N, Yokoyama K, Taki J, et al. Thallium-201 SPECT depicts radiologically occult lung cancer. *J Nucl Med* 1991;32:2284-2285