



Get Clarity On Generics

Cost-Effective CT & MRI Contrast Agents



FRESENIUS
KABI

WATCH VIDEO

AJNR

Percutaneous transvenous embolization through the thrombosed sinus in transverse sinus dural fistula.

Y P Gobin, E Houdart, A Rogopoulos, A Casasco, A L Bailly and J J Merland

This information is current as of August 7, 2025.

AJNR Am J Neuroradiol 1993, 14 (5) 1102-1105
<http://www.ajnr.org/content/14/5/1102>

Percutaneous Transvenous Embolization through the Thrombosed Sinus in Transverse Sinus Dural Fistula

Y. P. Gobin,¹ E. Houdart,¹ A. Rogopoulos,² A. Casasco,¹ A. L. Bailly,¹ and J. J. Merland¹

Summary: Each of two patients presented with a dural arteriovenous fistula involving the transverse sinus. The sinus was thrombosed proximal and distal to the dural arteriovenous fistula with the venous drainage being retrograde through cortical veins. An ipsilateral percutaneous transjugular approach was used in both cases and allowed recanalization of the thrombosed sinus and embolization of the dural arteriovenous fistula with coils. Complete cure was achieved in one patient and 95% reduction in arteriovenous shunting including elimination of the cortical venous reflux in the other. This technique avoided surgical exposure of the sinus.

Index terms: Fistula, arteriovenous; Fistula, therapeutic blockade; Dural sinuses; Thrombosis, dural sinus; Interventional neuroradiology

Dural arteriovenous fistula (dAVF) of the transverse sinus consists of multiple arteriovenous shunts opening into the wall of the sinus. Transarterial embolization of these dAVFs can be difficult, because the arterial feeders are multiple. Complete cure is seldom achieved by a staged transarterial approach (1–3), and recanalization often occurs. On the other hand, the transverse sinus forms a single venous compartment, collecting all of the arteriovenous shunts. Occlusion of this single venous compartment allows a more complete and definitive occlusion of the arteriovenous shunts (4).

However, when the sinus is thrombosed, direct venous access to the arteriovenous shunts is impaired (5, 6). Percutaneous access to the transverse sinus has been obtained by passing a contralateral venous into the thrombosed sigmoid sinus, through the confluence of the sinuses (4). This is possible only when the transverse sinus near the confluence is patent. Otherwise this approach is not possible and access requires surgical exposure of the sinus (4, 7).

We present two cases of percutaneous recanalization of thrombosed sigmoid sinus, per-

formed to allow embolization of dAVF of the ipsilateral transverse sinus.

Patients and Methods

Case 1

A 72-year-old right-handed woman presented with headaches, right hemiparesis, and aphasia. Computed tomography on admission showed a left temporo-occipital hematoma. Cerebral angiography demonstrated a dAVF involving the left transverse sinus (Fig 1A). The arterial feeders consisted of multiple meningeal branches of the left external carotid artery. The transverse sinus was thrombosed downstream and upstream of the dAVF, and venous drainage was retrograde through the vein of Labbe and occipital cortical veins. The patient improved progressively and was referred to us 5 months after the acute episode. Neurologic examination showed residual alexia and acalculia.

Transarterial embolization was initially attempted, but superselective catheterization failed to reach the region of the shunts. Transvenous embolization was then planned. The procedure was conducted under neuroleptanalgesia and systemic heparin anticoagulation. The left femoral artery was punctured, and a 5-F catheter was passed into the left external carotid artery for follow-up arteriograms. The right femoral vein was punctured, and a 5-F guiding catheter was passed into the left jugular vein. Catheterization of the thrombosed sigmoid sinus using a Tracker 18 microcatheter and a Taper guide wire (Target Therapeutic, San Jose, Calif) was attempted, but failed. The Taper guide wire was replaced by a Terumo 16 guide wire (Terumo, St. Quentin en Yvelines, France). The Terumo guide wire entered the thrombosed sigmoid sinus up to the fistula area, but the Tracker 18 microcatheter did not follow. The same maneuver was attempted via the contralateral jugular vein, with a similar lack of success. A 5-F vertebral curve catheter (Mallinckrodt, Paris, France) was then positioned in the left jugular vein. A Terumo 35 guide wire could be passed into the transverse sinus, but the catheter would not follow the guide because of a tendency to loop in the right atrium. It was then decided to stop the procedure and

Received April 29, 1992; revision requested August 6, received September 22, and accepted November 11.

¹ Service de Neuroradiologie, Hôpital Lariboisière, 2, rue Ambroise Paré, 75745 Paris, France. Address reprint requests to Y. P. Gobin.

² Service de Radiologie, Hôpital Saint-Roch, Nice, France.

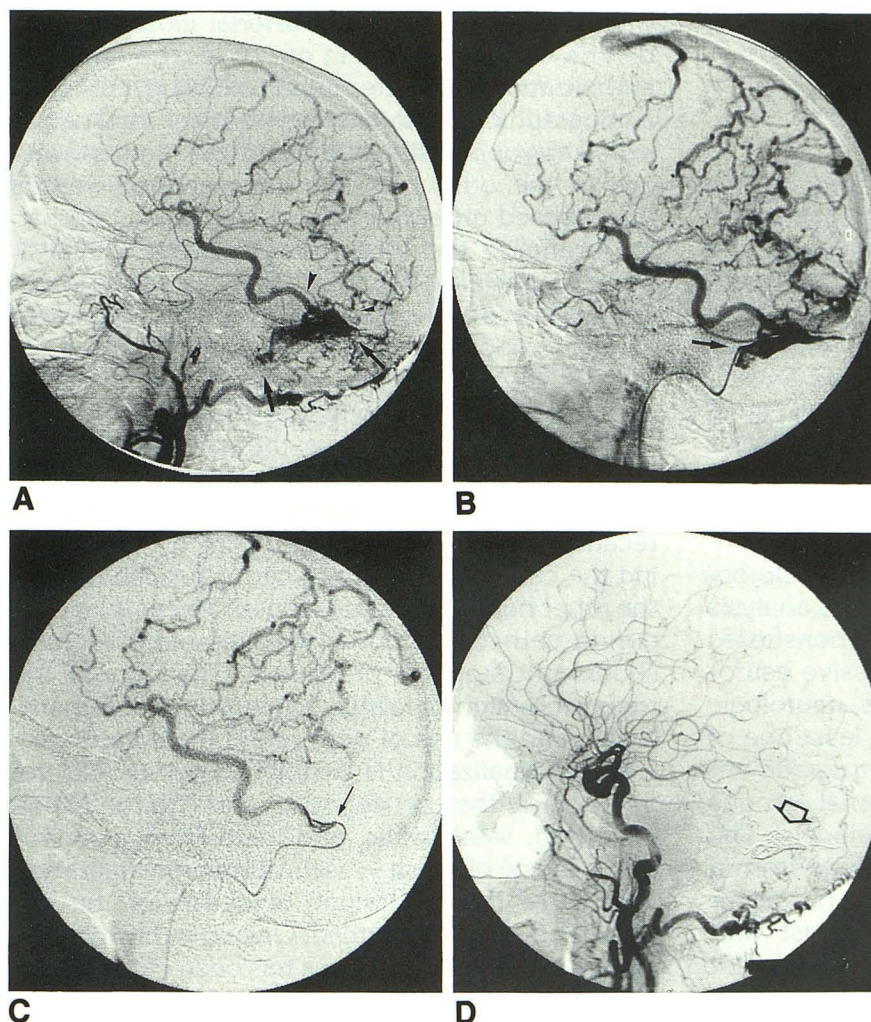


Fig. 1. Case 1: 72-year-old right-handed woman with left temporo-occipital hematoma on admission.

A, Left external carotid angiogram, lateral view, showing a dAVF of the left transverse sinus. The transverse sinus is thrombosed downstream and upstream of the dAVF (arrows), and the venous drainage of the dAVF flows retrograde through the vein of Labbe (large arrowhead) and occipital cortical veins (small arrowhead).

B, Left transverse sinus angiogram, lateral view. Catheterization of the left jugular vein with a 5-F introducer-sheath allowed subsequent catheterization of the fistulous portion of the transverse sinus with a 5-F catheter through the thrombosed sigmoid sinus. The tip of the 5-F catheter is shown (arrow).

C, Opacification of the vein of Labbe by the microcatheter, lateral view. Starting with the occlusion of the ostium of the vein of Labbe (arrow), 35 coils were successively released into the transverse sinus.

D, Left carotid angiogram after embolization, lateral view, demonstrating complete occlusion of the dAVF after coil packing of the whole pathologic fistulous portion of the transverse sinus (open arrow).

plan a second attempt via a direct left transjugular approach the following week.

In this second procedure the left jugular vein was punctured and catheterized with a 5-F introducer sheath through which the same type of 5-F catheter was positioned just below the sigmoid sinus. (The right femoral artery was also punctured and a 5-F catheter was left in the left external carotid artery for control angiograms.) The fistulous portion of the transverse sinus was easily reached through the thrombosed sigmoid sinus by a Terumo 35 guide wire. With the guide wire in position, the 5-F catheter was then slowly but firmly pushed and rotated over the guide wire up to the fistulous portion of the transverse sinus (Fig 1B). This maneuver provoked moderate pain in the ear, but no headache. Once the 5-F catheter was in place in the fistulous portion of the transverse sinus, a Tracker 18 microcatheter with a Terumo 16 guide wire and a coil pusher (Target Therapeutic) were used to release 35 microcoils (Cook, Paris, France; and Target Therapeutic), starting at the ostia of the vein of Labbe (Fig 1C) and occipital cortical veins and ending with packing of the pathologic fistulous portion of the transverse sinus until there was complete occlusion of the dAVF (Fig 1D). The patient was

discharged 2 days later on Nadroparine (low-molecular weight heparin) to prevent extensive cerebral venous thrombosis. During the following days, she complained of moderate headaches but showed complete recovery from the alexia and acalculia. Six weeks later, a follow-up angiogram confirmed cure of the dAVF and normalization of the cerebral venous drainage.

Case 2

A 67-year-old woman had a 2-month history of posterior headaches and generalized seizures. Radiologic investigations revealed a dAVF located on the left transverse sinus. The sinus was thrombosed and the dAVF drained extensively through cortical veins. Via left-jugular puncture, the pathologic transverse sinus was catheterized through the thrombosed sigmoid sinus using the same system (Terumo 0.035-inch guide wire and Mallinckrodt 5-F wired catheter). Using a Tracker 18 microcatheter, Terumo 16 guide wire, and coil pusher, the transverse sinus was then occluded with microcoils with 95% reduction of the dAVF. The residual drainage of the dAVF was via the inferior petrosal

sinus. The cortical venous drainage disappeared. There was resolution of the neurologic symptoms.

Discussion

In both cases, dAVFs were located on the transverse sinus, which was thrombosed proximal and distal to the dAVF. Venous drainage was retrograde via cortical veins. Neurologic symptoms (hemorrhage, persistent alexia, and acalculia in the first case; seizures in the second case) caused by the dAVFs theoretically could be secondary to the arterial feeders, from the dural arteriovenous shunts itself, or from the venous drainage. The dAVFs were fed by meningeal arteries only, which have no brain arterial supply. Thus, arterial steal can not be incriminated. Hemorrhage from the arteriovenous shunts could occur but is unlikely because an extensive analysis of 377 cases in the literature (8) demonstrated that "not a single case with an aggressive neurologic course (ie, hemorrhage, seizures, neurologic deficit) has been reported without at least one of these features (ie, leptomenigeal retrograde venous drainage, variceal or aneurysmal venous structures, and galenic venous drainage)." The fact that, to our knowledge, hemorrhage from a dAVF without cortical venous drainage has never been described suggests that, in contrast with brain arteriovenous malformations, dAVFs do not tend to bleed from their "nidus." This is because the arteriovenous shunts are located inside the dura, a strong, thick membrane. In both these cases of dAVFs, the symptoms were therefore directly related to their venous drainage, and the symptoms disappeared soon after embolization suppressed the retrograde cortical venous drainage.

An angiographic classification of transverse sinus dAVFs correlating the neurologic risk with the venous drainage has been made by Djindjian and Merland (9). In contrast with transverse sinus dAVFs with free antegrade outflow into the ipsilateral jugular vein (which have a nonaggressive course), dAVFs with retrograde cortical venous drainage have been shown to have an extremely aggressive neurologic course (1, 8–12). Our cases, with fistula drainage into the sinus followed by retrograde flow into cortical veins, would be type 2 according to this classification, and are likely to present with hemorrhage and neurologic deficits. These dAVFs need prompt and complete closure, partial arterial embolization does not eliminate the risk of hemorrhage (12).

Because complete transarterial closure of the dAVFs was impossible in our cases, transvenous embolization was attempted, allowing complete angiographic cure in one case and subtotal occlusion with suppression of the cortical venous drainage in the other. As the transverse sinus was thrombosed on either side of the fistula, we had to recanalize the thrombosed sigmoid sinus in order to reach the fistula site. Percutaneous transvenous access offered an obvious advantage over surgical venous access; it avoided the need for anesthesia and craniotomy and allowed continuous clinical monitoring during the procedure.

In both cases, the sinus thrombosis was long standing. Such organized thrombi are very compact. To prevent perforation of the sinus during recanalization, we observed a clinical rule: pushing the catheter should not cause headaches. On the other hand, moderate pain in the ear is normal during catheterization of the sigmoid sinus and should not stop the procedure. The dura of the transverse/sigmoid sinus is a strong, thick membrane, and the risk of perforating the dura is very low if recanalization is performed gently. On the other hand, the cortical veins draining the fistula have thin, weak walls, and inadvertent penetration into one of these vessels during recanalization with either the 0.035-inch guidewire or the 5-F catheter should be avoided. Once the thrombosed portion of the sigmoid sinus has been catheterized and the 5-F catheter has been positioned in the fistulous portion of the transverse sinus, the exact sites of release of the coils with the Tracker 18 microcatheter could be easily selected initially at the ostia of the cortical veins draining the dAVF (to be sure to suppress the cortical venous reflux), then at the fistulous sinus itself.

Three technical points that allowed successful recanalization of the transverse sigmoid sinus should be emphasized:

- 1) Direct jugular puncture is preferred to transfemoral puncture, because it enables better control of the catheter and avoids kinking in the right atrium.

- 2) The Terumo guide wire appeared to be superior to metallic guidewires to recanalize the thrombosed sinus, possibly because of its special mechanical properties, specifically its resistance to kinking, and its better gliding properties.

- 3) Recanalization should be performed using a 5-F catheter. Indeed, in our two patients, the microcatheter failed to follow the guide through the thrombosed sigmoid sinus. The 5-F catheter was wire-reinforced and had a tapered tip; this

allowed better control and progression over the guide.

These technical points were defined on the basis of our experience in the first case and enabled us to perform the procedure easily in the second case.

References

1. Ferman M, Reizine D, Melki JP, Riche MC, Merland JJ. Long term follow-up of 43 pure dural arteriovenous fistulae of the lateral sinus. *Neuroradiology* 1987;29:348-353
2. Vinuela F, Fox AJ, Pelz DM, et al. Unusual clinical manifestations of dural arteriovenous malformations. *J Neurosurg* 1986;64:554-558
3. Halbach VV, Higashida RT, Hieshima GB, Goto K, Norman D, Newton TH. Dural fistulas involving the transverse and sigmoid sinuses: results of treatment in 28 patients. *Radiology* 1987;163:443-447
4. Halbach VV, Higashida RT, Hieshima GB, Mehringer CM, Hardin CW. Transvenous embolization of dural fistulas involving the transverse and sigmoid sinuses. *AJNR: Am J Neuroradiol* 1989;10:385-392
5. Halbach VV, Higashida RT, Hieshima GB, Hardin CW, Pribam H. Trans-venous embolization of dural fistulas involving the cavernous sinus. *AJNR: Am J Neuroradiol* 1989;10:377-383
6. Barnwell SL, Halbach VV, Dowd CF, Higashida RT, Hieshima GB. Dural arteriovenous fistulas involving the inferior petrosal sinus: angiographic findings in six patients. *AJNR: Am J Neuroradiol* 1990;11:511-516
7. Barnwell SL, Halbach VV, Higashida RT, Hieshima GB, Wilson CB. Complex dural arteriovenous fistulas: results of combined endovascular and neurosurgical treatment in 16 patients. *J Neurosurg* 1989;71:352-358
8. Awad IA, Little JR, Akrawi WP, Ahl J. Intracranial dural arteriovenous malformations: factors predisposing to an aggressive neurological course. *J Neurosurg* 1990;72:839-850
9. Djindjian R, Merland JJ. *Superselective angiography of the external carotid artery*. Berlin: Springer Verlag, 1978
10. Castaigne P, Bories J, Brunet P, Cassan JL, Merland JJ. Fistules arterioveineuses de la dure-mère. Etude clinique et radiologique de 13 observations. *Ann Med Interne (Paris)* 1975;126:813-817
11. Gaston A, Chiras J, Bourbotte G, Leger JM, Guibert-Tranier F, Merland JJ. Meningeal arteriovenous fistulae draining into cortical veins. *J Neuroradiol* 1984;11:161-177
12. Pierot L, Chiras J, Meder JF, Rose M, Rivierez M, Marsault C. Dural arteriovenous fistulas of the posterior fossa draining into subarachnoid veins. *AJNR: Am J Neuroradiol* 1992;13:315-323