



Get Clarity On Generics

Cost-Effective CT & MRI Contrast Agents



FRESENIUS
KABI

WATCH VIDEO

AJNR

Double spinal dural arteriovenous fistulas: report of two cases.

L Pierot, T Vlachopoulos, N Attal, N Martin, S Bert and J Chiras

AJNR Am J Neuroradiol 1993, 14 (5) 1109-1112

<http://www.ajnr.org/content/14/5/1109>

This information is current as
of August 8, 2025.

Double Spinal Dural Arteriovenous Fistulas: Report of Two Cases

Laurent Pierot,¹ Takis Vlachopoulos,¹ Nadine Attal,² Nadine Martin,¹ Stéphane Bert,¹ and Jacques Chiras^{1,3}

Summary: We report two unusual cases of double spinal dural arteriovenous fistulas. Both patients had signs and symptoms commonly described in this condition, but selective angiography of the spinal cord demonstrated two separate dural arteriovenous fistulas with separate venous drainage for each fistula.

Index terms: Fistula, arteriovenous; Fistula, spinal dural; Arteriovenous malformations, spinal; Spinal angiography

Spinal dural arteriovenous fistula (DAVF) is a well-known anatomic and clinical entity. It is defined as a spinal vascular lesion supplied by dural branches arising from intercostal, lumbar, or, rarely, sacral arteries and drained by perimedullary veins. The vascular nidus of the shunt is embedded in the dura mater covering the proximal nerve root and in the adjacent spinal dura.

Since their first description by Kendall and Logue (1) as a group distinct from the less common intradural spinal vascular malformations, many spinal DAVFs have been reported in the literature (2–6).

In two cases, we observed double dural spinal fistulas. Topography of the shunt is usual, but venous drainage seems to be independent for each fistula.

Case 1

A 47-year-old man presented in September 1990 with paresthesia and motor deficit of the lower limbs. An episode of urinary incontinence was reported.

The clinical examination revealed hypoesthesia of the lower limbs and of the perineum, bilateral proprioceptive sensory deficits of the lower limbs which were worse on the right, increased deep tendon reflexes, bilateral lower extremity weakness, and urinary incontinence.

Magnetic resonance (MR) showed an enlargement of the thoracic spinal cord with central hypointensity on T1-weighted images, hypersignal on T2-weighted images, and serpiginous contrast enhancement on the posterior surface of the cord (Fig. 1A). Clinical features and MR findings were suggestive of a spinal DAVF.

Angiography of the spinal cord demonstrated the presence of two separate DAVFs. The first was fed by the sixth left intercostal artery and drained through an ascending dorsal retromedullary vein (Fig. 1B); the second was fed by the eighth right intercostal artery and drained through a descending dorsal retromedullary vein (Fig. 1C).

Endovascular treatment was performed. The fistula fed by the eighth right intercostal artery was embolized successfully with N-butyl cyanoacrylate. Selective catheterization of the second fistula fed by the sixth left intercostal artery was not possible and embolization of this pedicle was performed using polyvinyl alcohol foam powder (Ivalon, San Diego, Calif). Control angiogram showed persistent occlusion of the right fistula, but recanalization of the left fistula was observed with supply from the seventh left intercostal artery (Fig. 1D). The ascending venous drainage was noted.

Surgical treatment of this fistula was performed.

Case 2

A 64-year-old man suffered in December 1990 from progressive lower extremity weakness and sensory loss. In March 1991, he was admitted to the neurosurgery service with bilateral lower extremity weakness, sensory loss, and bladder dysfunction.

The myelogram showed dilated retromedullary vessels in the thoracic region. MR was considered normal. Spinal angiography revealed the presence of two separate DAVFs. One was supplied by a radiculomeningeal branch arising from the eighth right intercostal artery and draining through an ascending retromedullary vein (Fig. 2A). The other was supplied by a radiculomeningeal branch arising from the ninth left intercostal artery and draining through a descending retromedullary vein (Fig. 2B).

Surgical treatment was performed.

Discussion

DAVFs are the most common spinal arteriovenous malformations. They consist of abnormal communication between meningeal arteries and a medulloradicular vein; the fistula drains into these veins and then into the spinal veins. This drainage can be ascending, descending, or both

Received March 10, 1992; revision requested July 23, received September 25, and accepted November 11.

¹ Service de Neuroradiologie Charcot, Département de Neuroradiologie, and ²Service de Neurologie, Hôpital de la Salpêtrière, Paris, France.

³ Address reprint requests to Jacques Chiras, MD, Hôpital de la Salpêtrière, 47, boulevard de l'Hôpital, 75651 Paris Cedex 13.

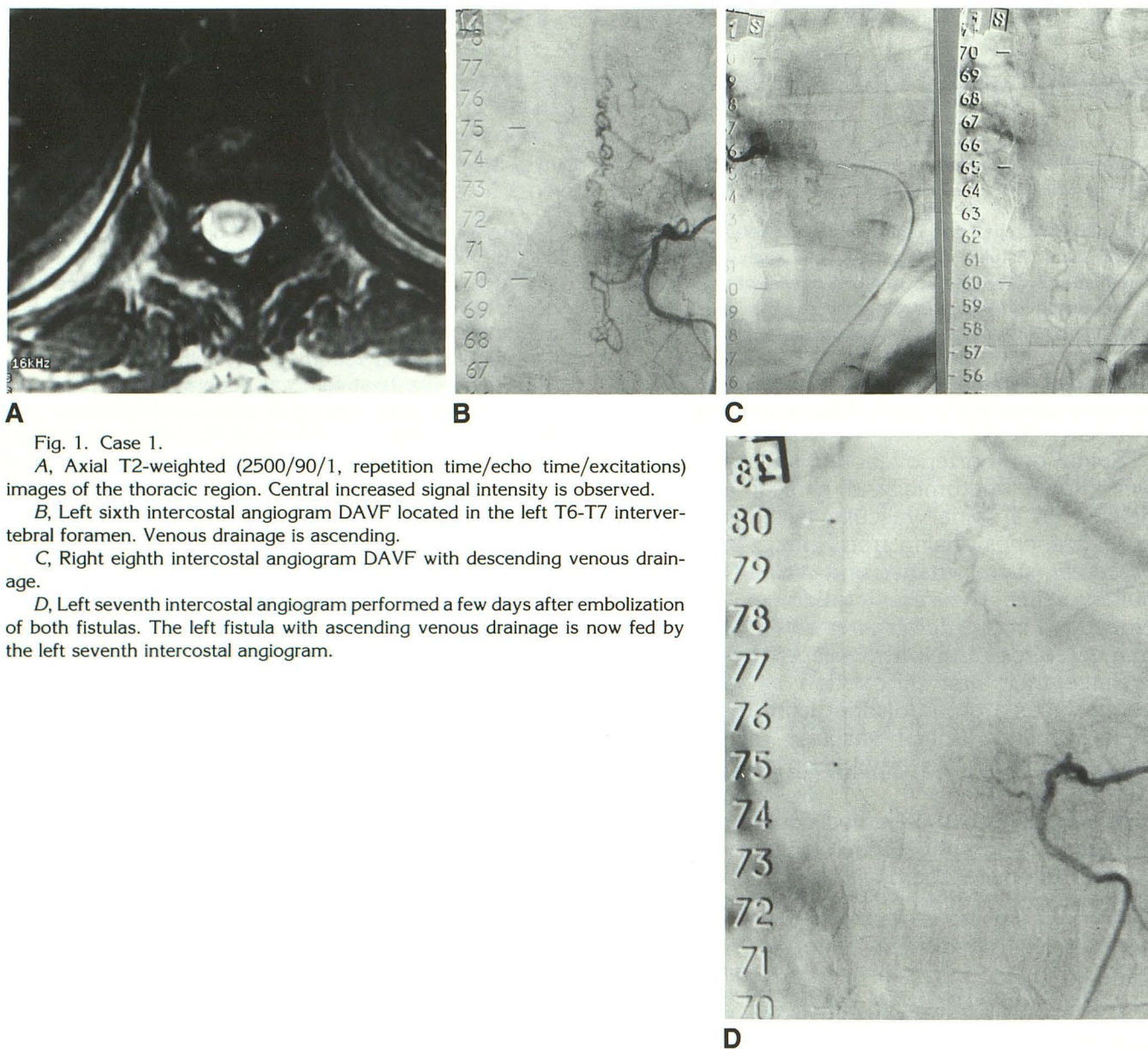


Fig. 1. Case 1.

A, Axial T2-weighted (2500/90/1, repetition time/echo time/excitations) images of the thoracic region. Central increased signal intensity is observed.

B, Left sixth intercostal angiogram DAVF located in the left T6-T7 intervertebral foramen. Venous drainage is ascending.

C, Right eighth intercostal angiogram DAVF with descending venous drainage.

D, Left seventh intercostal angiogram performed a few days after embolization of both fistulas. The left fistula with ascending venous drainage is now fed by the left seventh intercostal angiogram.

(2–4, 6). The nidus of the malformation consists of a single fistula located in the dura mater, along the nerve root. Most often, fistulas are found in the thoracic or lumbar spine (2–4, 6). Some cases have been described in the sacral spine (7, 8) and recently in the cervical and suboccipital area (9). Rarely, an intracranial fistula can drain into spinal veins (10, 11). In all previously reported cases we found, the nidus appeared solitary.

Our cases are the first known to us in which two distinct fistulas are discovered on angiography (Figs. 1, B and C, and 2, A and B). The clinical presentation and neuroradiologic findings (myelography and MR) were similar to others

described in the literature (12–16) (Fig. 1A). However, angiography showed some peculiarities: the location of the nidus was typical, but the venous drainage seemed to be independent for each fistula—the lower fistula drained into descending veins (Figs. 1C and 2B), the upper one into ascending veins (Figs. 1B and 2A)—even after embolization of one of the fistulas (case 1) (Fig. 1D).

These cases alert us about the investigation of DAVF of the spinal cord. It is commonly accepted that angiography is complete when one fistula feeder has been discovered and spinal arteries have been visualized. But our observations dem-

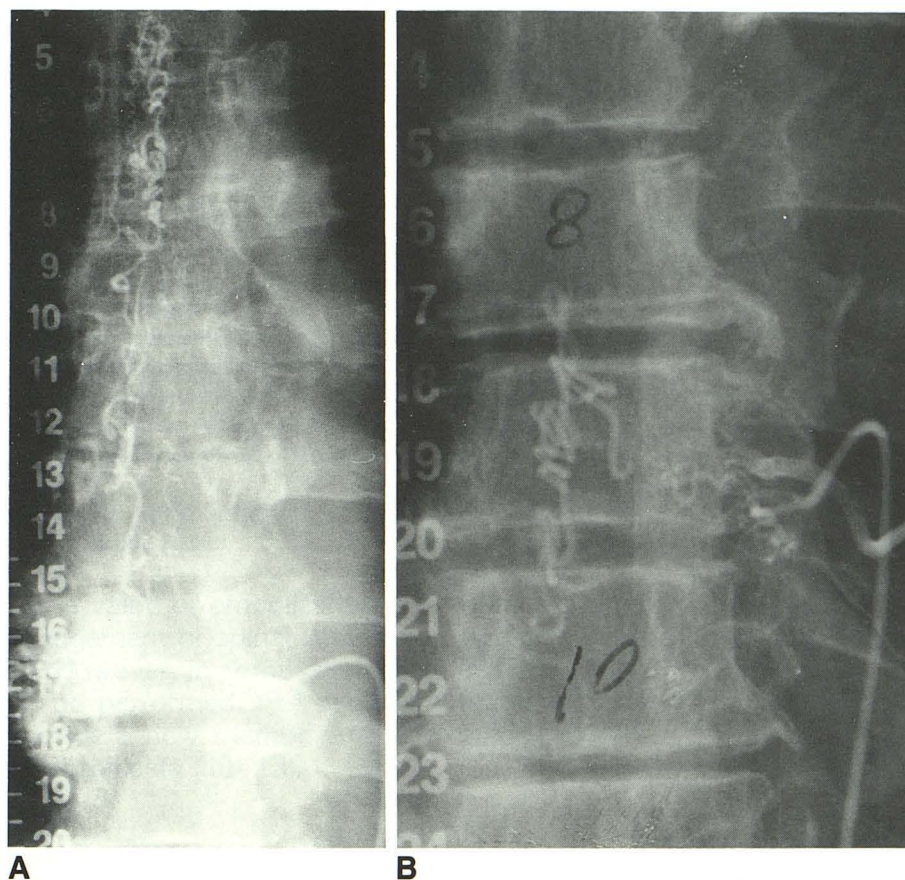


Fig. 2. Case 2.

A, Right eighth intercostal angiogram DAVF with ascending venous drainage.

B, Left ninth intercostal angiogram DAVF with descending venous drainage.

onstrate that this may not be sufficient in all cases. Nonangiographic investigations of the fistula could be important in regard to the venous drainage. The extent and direction of the venous drainage visualized by myelography and angiography can be evaluated for discrepancies. On MR, it is impossible to show precisely the extent of the venous drainage. It may be useful to perform complete spinal angiography either at the initial diagnostic step or during control angiography to avoid missing a second fistula.

Frequency of double spinal DAVF is difficult to evaluate. Indeed, double spinal DAVFs were not reported previously, to our knowledge. In the last 10 years, approximately 50 spinal DAVFs have been diagnosed in our institution. Out of these, two were double dural fistulas. Thus, frequency of double dural fistulas is probably less than 5%, around 1% to 2%. However, frequency of double dural fistulas may be underestimated if complete spinal angiography is not performed.

Pathogenesis of spinal DAVF remains unclear. DAVFs are probably acquired, as in cases of intracranial dural fistulas. These fistulas are thought to be acquired from dural sinus throm-

bosis (17). Spinal dural fistula theoretically could be the consequence of venous thrombosis. Could one spinal dural fistula promote venous stagnation and thrombosis resulting in a production of a second fistula?

References

1. Kendall BE, Logue V. Spinal epidural angiomatous malformations draining into intrathecal veins. *Neuroradiology* 1977;13:181-189
2. Merland JJ, Riche MC, Chiras J. Intraspinal extramedullary arteriovenous fistulae draining into the medullary veins. *J Neuroradiol* 1980;7:271-320
3. Symon L, Kuyama H, Kendall B. Dural arteriovenous malformations of the spine: clinical features and surgical results in 55 cases. *J Neurosurg* 1984;60:238-247
4. Rosenblum B, Oldfield EH, Doppman JL, Di Chiro G. Spinal arteriovenous malformations: a comparison of dural arteriovenous fistulas and intradural AVMs in 81 patients. *J Neurosurg* 1987;67:795-802
5. Morgan MK, Marsh WR. Management of spinal dural arteriovenous malformations. *J Neurosurg* 1989;70:832-836
6. Koenig E, Thron A, Schrader V, Dichgans J. Spinal arteriovenous malformations and fistulae: clinical, neuroradiological and neurophysiological findings. *J Neurol* 1989;236:260-266
7. Stein SC, Ommaya AK, Doppman JL, Di Chiro J. Arteriovenous malformation of the cauda equina with arterial supply from branches of the internal iliac arteries. *J Neurosurg* 1972;36:649-651

8. Heindel C, Duggen GS, Guinio FC. Spinal arteriovenous malformations with hypogastric blood supply. *Neuroradiology* 1977;13:181-189
9. Barnwell SL, Halbach VV, Dowd CF, Higashida RT, Hieshima GB, Wilson CB. Multiple dural arteriovenous fistulas of the cranium and spine. *AJNR: Am J Neuroradiol* 1991;12:441-445
10. Rivierez M, Gazengel J, Chiras J, et al. Les fistules artérioveineuses vertébro-durales du trou occipital à drainage médullaire: deux observations. *Neurochirurgie* 1991;37:179-184
11. Pierot L, Meder JF, Rivierez M, Chiras J, Marsault C. Dural arteriovenous malformations of the posterior fossa draining into cortical veins. *AJNR: Am J Neuroradiol* 1992;13:315-323
12. Doppman JL, Di Chiro G, Dwyer AJ, Frank JL, Oldfield EH. Magnetic resonance imaging of spinal arteriovenous malformations. *J Neurosurg* 1987;66:830-834
13. Dormont D, Gelbert F, Assouline E, et al. MR imaging of spinal cord. Arteriovenous malformations at 0,5 T: study of 34 cases. *AJNR: Am J Neuroradiol* 1988;9:833-838
14. Masaryk TJ, Ross JS, Modic MT, Ruff RL, Selman WR, Ratcheson RA. Radiculomeningeal vascular malformations of the spine: MR imaging. *Radiology* 1987;164(3):845-849
15. Minami S, Sagoh T, Nishimura K, et al. Spinal arteriovenous malformation: MR imaging. *Radiology* 1988;169(1):109-115
16. N'Diaye M, Chiras J, Meder JF, Barth MO, Koussa A, Bories J. Apport de la myélographie aux hydrosolubles dans les fistules artérioveineuses durales rachidiennes à drainage veineux péri-médullaire. *J Neuroradiol* 1984;11:327-339
17. Pierot L, Chiras J, Duyckaerts C, Jason M, Martin N. Intracranial dural arteriovenous fistulae and sinus thrombosis: report of five cases. *J Neuroradiol* 1993;20:9-18