



Discover Generics

Cost-Effective CT & MRI Contrast Agents



WATCH VIDEO

AJNR

Lumbar degenerative disk disease: prospective comparison of conventional T2-weighted spin-echo imaging and T2-weighted rapid acquisition relaxation-enhanced imaging.

J S Ross, P Ruggieri, J Tkach, N Obuchowski, J Dillinger, T J Masaryk and M T Modic

This information is current as of June 18, 2025.

AJNR Am J Neuroradiol 1993, 14 (5) 1215-1223
<http://www.ajnr.org/content/14/5/1215>

Lumbar Degenerative Disk Disease: Prospective Comparison of Conventional T2-Weighted Spin-Echo Imaging and T2-Weighted Rapid Acquisition Relaxation-Enhanced Imaging

Jeffrey S. Ross, Paul Ruggieri, Jean Tkach, Nancy Obuchowski, John Dillinger, Thomas J. Masaryk, and Michael T. Modic

PURPOSE: To compare conventional T2-weighted spin-echo imaging with a rapid acquisition relaxation enhanced (RARE) technique in the routine evaluation of lumbar degenerative disk disease. **METHODS:** Thirty consecutive patients referred for evaluation of the lumbar spine for suspected degenerative disk disease were evaluated with sagittal and axial T1-weighted spin-echo, conventional T2-weighted spin-echo, and T2-weighted RARE "turbo spin-echo" sequences (4000/93/2 (repetition time/echo time/excitations), 192×256 , echo train length of 8). Conventional T2-weighted and RARE images were evaluated independently by two neuroradiologists for image quality, presence of artifacts, cerebrospinal fluid signal intensity, extradural interface conspicuity, intradural nerve root conspicuity, soft-tissue detail, and signal intensity of normal and degenerated intervertebral disks. **RESULTS:** Both readers rated the cerebrospinal fluid signal higher, the extradural interface conspicuity higher, and the nerve root detail greater on the turbo spin-echo than on conventional spin-echo images. Neither reader had a significant difference in ranking "normal" or "degenerated" disk signal on the two sequences. Both readers rated soft-tissue detail higher for conventional than for turbo spin-echo. **CONCLUSION:** RARE sequences can replace conventional T2-weighted spin-echo sagittal studies for degenerative lumbar disk disease.

Index terms: Magnetic resonance, comparative studies; Spine, intervertebral disks, degeneration

AJNR 14:1215-1223, Sep/Oct 1993

Although protocols for magnetic resonance (MR) imaging of the lumbar spine for degenerative disk disease vary from institution to institution, some common themes are present. Generally, T1-weighted spin-echo (SE) images are obtained for the depiction of gross anatomy, disk herniations, and stenosis; a second sequence type is performed to provide increased cerebrospinal fluid signal, either with an intermediate/T2-weighted SE sequence or a low-flip-angle gradient-echo (GE) sequence for maximal extradural interface conspicuity. The widespread use of low-flip-angle GE sequences in the spine has been driven by time considerations: GE sequences can consistently produce increased signal CSF in a

shorter time period than either refocused or cardiac-gated T2-weighted SE sequences (1-4). The emergence of rapid acquisition relaxation enhanced (RARE) sequences capable of providing T2-weighted SE contrast in a fraction of the time of conventional T2-weighted sequences would seem to be the natural replacement for low-flip-angle GE sequences (or conventional SE [CSE]) in the evaluation of lumbar degenerative disk disease (5-7). The purpose of this study is to compare conventional T2-weighted spin echo with the RARE technique in the routine evaluation of lumbar degenerative disk disease.

Materials and Methods

All studies were obtained on a 1.5-T Siemens SP4000 system (Siemens Medical Systems, Ise-lin, NJ).

Thirty consecutive patients (with no history of previous low back surgery) referred for evaluation of the lumbar spine for suspected degenerative disk disease (low back pain and/or radiculopathy)

Received May 29, 1992; revision requested August 5 and accepted September 18.

All authors are from the Division of Radiology, Cleveland Clinic Foundation, 9500 Euclid Avenue, Desk L-10, Cleveland OH 44195-5129. Address requests for reprints to Jeffrey S. Ross, MD.

AJNR 14:1215-1223, Sep/Oct 1993 0195-6108/93/1405-1215

© American Society of Neuroradiology

were evaluated with the following sequences: 1) sagittal and axial T1-weighted SE (500/15/4 [repetition time (TR)/echo time (TE)/excitations], 192 × 256 matrix, 4-mm section thickness, 40% intersection gap, 23-cm field of view); 2) conventional T2-weighted SE (2000/90/1, 192 × 256, 4-mm section thickness, 40% intersection gap, 23-cm field of view, 6.4 min); 3) the T2-weighted RARE sequence "turbo SE" (4000/93/2, 192 × 256, 4-mm section thickness, 40% gap, echo train length of 8, echo spacing of 23 ms, 23-cm field of view, 3.3 min).

Conventional T2-weighted and RARE images were evaluated independently by two neuroradiologists for the following eight factors, graded on a five-point scale (0 = none to 4 = maximum): 1) overall image quality, 2) presence of artifacts, 3) CSF signal intensity, 4) extradural interface conspicuity, 5) intradural nerve root conspicuity, 6) soft-tissue detail (sharpness), 7) signal intensity of normal intervertebral disk, and 8) signal intensity of degenerated intervertebral disks. Image "quality" was a qualitative assessment of factors affecting image esthetics such as signal-to-noise ratio (S/N), contrast-to-noise ratio, and tissue signal homogeneity. Soft-tissue detail was a qualitative assessment of the degree of edge definition, with particular regard to the appearance of the neural foramina, the nerve root, and the ganglia, as well as the facet joints on the parasagittal images. Normal intervertebral disk signal was defined as normal disk space height with an internuclear cleft. Degenerated intervertebral disk was defined as one or more of the following: decreased intervertebral disk signal, loss of disk space height, associated end plate marrow changes, or herniation. Blinding the readers to sequence type was not possible because of the visual differences between conventional and RARE T2-weighted images.

Data for differences between the conventional and RARE T2-weighted sequences were evaluated by use of the nonparametric Wilcoxon signed ranked test.

Results

The degenerative disk disease present in this population included disk herniation (n = 12 levels), central canal stenosis (n = 14 levels), and spondylolithesis (n = 3 levels). Other findings included one patient with metastatic disease and one patient with a radiculomedullary fistula.

CSF signal

Both readers rated the CSF signal higher in the turbo SE than in the CSE (*P* values of .0001 and .0001) (Figs. 1–6; Table 1).

TABLE 1: CSF signal. Comparison of grades for CSE and turbo SE summed for both readers.

CSE Grades	TSE Grades			Totals
	1	2	3	
1	2	2	3	7
2	0	4	35	39
3	0	1	13	14
Totals	2	7	51	

Extradural interface conspicuity

Both readers rated the extradural interface conspicuity higher with turbo SE than with CSE (*P* values of .0001 and .0001) (Figs. 2–5; Table 2).

TABLE 2: Extradural interface. Comparison of grades for CSE and turbo SE summed for both readers.

CSE Grades	TSE Grades			Totals
	1	2	3	
0	1	0	0	1
1	1	6	1	8
2	2	7	12	21
3	0	0	0	0
Totals	4	13	13	

Root detail

Both readers rated the intradural nerve root conspicuity greater with turbo SE than with CSE (*P* values of .0001 and .0001) (Figs. 1 and 5; Table 3).

TABLE 3: Nerve root detail. Comparison of grades for CSE and turbo SE summed for both readers.

CSE CSE/TSE	TSE				Totals
	0	1	2	3	
0	1	6	2	1	10
1	1	3	19	6	29
2	1	0	5	13	19
3	0	0	1	1	2
Totals	3	9	26	21	

Normal disk signal

Neither reader had a statistically significant difference in ranking "normal" disk signal (*P* values of 1.000 and .0654), although reader 2 tended to rank CSE as having an increased signal relative to turbo SE (Figs. 2 and 3; Table 4).

TABLE 4: Normal disk signal. Comparison of grades for CSE and turbo SE summed for both readers.

CSE Grades	TSE Grades				Totals
	0	1	2	3	
0	0	1	0	0	1
1	0	14	1	0	15
2	0	11	16	5	32
3	0	0	3	6	9
Totals	0	26	20	11	

Degenerative disk signal

Neither reader had a statistically significant difference in ranking "degenerative" disk signal (P values of .0831 and .5000), although reader 1 tended to rank CSE as having an increased signal relative to turbo SE (Figs. 2 and 4; Table 5).

TABLE 5: Degenerative disk signal. Comparison of grades for CSE and turbo SE summed for both readers.

CSE Grades	TSE Grades		Totals
	0	1	
0	50	0	50
1	5	4	9
Totals	55	4	

Soft-tissue detail

Both readers rated soft-tissue detail higher for CSE than for turbo SE (P values of .0012 and .0001) (Fig. 6; Table 6).

TABLE 6: Soft-tissue detail. Comparison of grades for CSE and turbo SE summed for both readers.

CSE Grades	TSE Grades				Totals
	0	1	2	3	
0	3	0	0	0	3
1	12	7	3	0	22
2	0	18	8	1	27
3	0	1	5	1	7
Totals	15	26	16	2	

Quality

For both readers, a higher quality score was assigned to the turbo SE sequence than to the CSE sequence (P values of .0088 and .0001). This was a subjective evaluation by the readers for overall image appeal, which may be driven by

the overall appearance of the CSF. There were no uninterpretable studies (Table 7).

TABLE 7: Quality. Comparison of grades for CSE and turbo SE summed for both readers.

CSE Grades	TSE Grades				Totals
	1	2	3	4	
1	0	9	1	1	11
2	1	8	17	2	28
3	0	3	13	4	20
4	0	0	0	1	1
Totals	1	20	31	8	

Artifacts

There was no statistical difference in the severity of artifacts for reader 1 ($P = .4027$). Reader 2 rated the severity of artifacts higher with the turbo SE sequence than with the CSE ($P = .0009$) (Table 8). The artifacts category principally relates to the degree of ghosting artifact in the images. These were most conspicuous over the vertebral bodies and retroperitoneal fat (Fig. 3B) but were not thought to constitute any diagnostic impediment.

TABLE 8: Artifacts. Comparison of grades for CSE and turbo SE summed for both readers.

CSE Grades	TSE Grades				Totals
	0	1	2	3	
0	9	15	1	0	25
1	6	17	8	1	31
2	1	0	2	0	3
3	0	0	0	0	0
Totals	16	32	11	1	

Discussion

The RARE sequence was first defined by Hennig and associates as a variant of echo planar imaging using an SE (5, 6, 8). This technique consists of a 90-degree pulse followed by a series of 180-degree radio frequency pulses that refocus the SEs. Each SE is then uniquely phase encoded. Thus, a sequence with an echo train length of 8 has 8 Ky lines acquired for each excitation, and consequently, the imaging time would be decreased by a factor of 8 compared with CSE, in which only 1 Ky line is acquired for each excitation. These sequences are implemented by

Fig. 1. Increased definition of nerve roots.

A, Conventional T2-weighted sagittal sequence shows loss of signal intensity at L4-L5 with a bulging annulus fibrosus. Note the nerve roots within the distal thecal sac.

B, Turbo SE sequence in the same patient shows the loss of signal at L4-L5 and the small anterior extradural defect. There is improved definition of the intrathecal nerve roots compared with (A). Note the compression fractures of L2 and L3, with a similar appearance of both the RARE and CSE sequences.

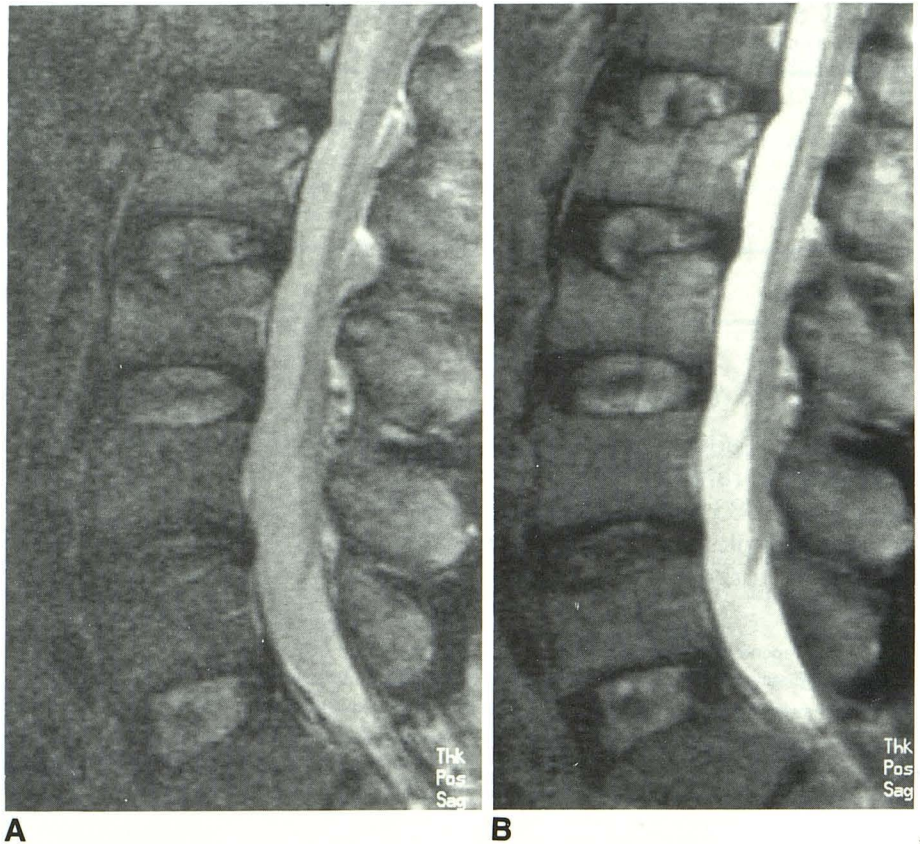
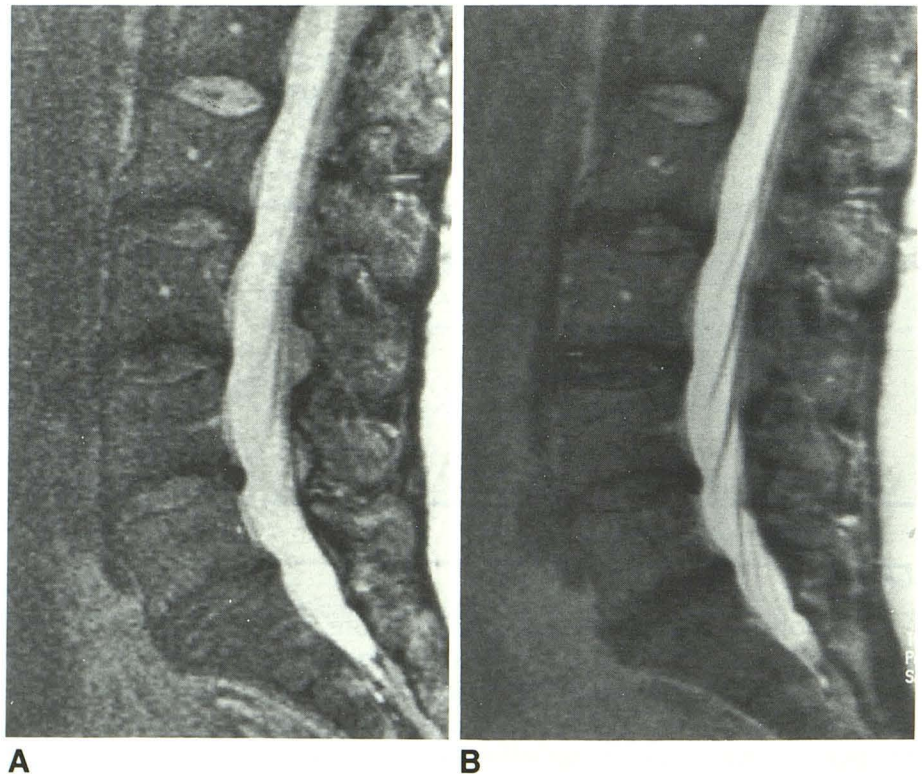


Fig. 2. Disk herniation
A, Conventional T2-weighted sagittal sequence demonstrates a small, low-signal-intensity disk herniation at L4-L5 and an anular bulge at L5-S1. There is loss of disk space signal at L2-L3 through L5-S1.

B, Turbo SE sequence in the same patient shows the low-signal herniation and the anular bulge. Note the increased signal from the CSF and the improved visualization of the intrathecal nerve roots.



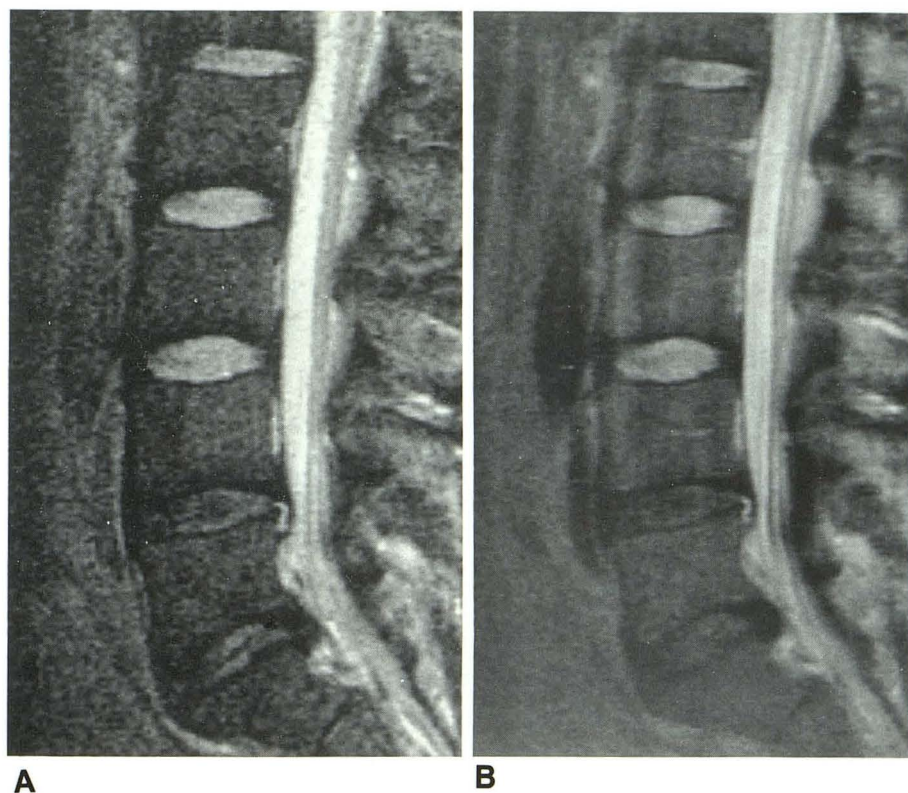


Fig. 3. Disk herniations

A, Conventional T2-weighted sagittal sequence shows a high-signal-intensity disk herniation at L4-L5 and low-signal herniation at L5-S1. There is also a loss of signal intensity in the L4 and L5 intervertebral disks.

B, Turbo SE sequence shows identical findings. There is improved visualization of the intrathecal nerve roots compared with the conventional T2-weighted sequence. There is increased ghosting artifact over the anterior aspects of the vertebral bodies and retroperitoneal fat.

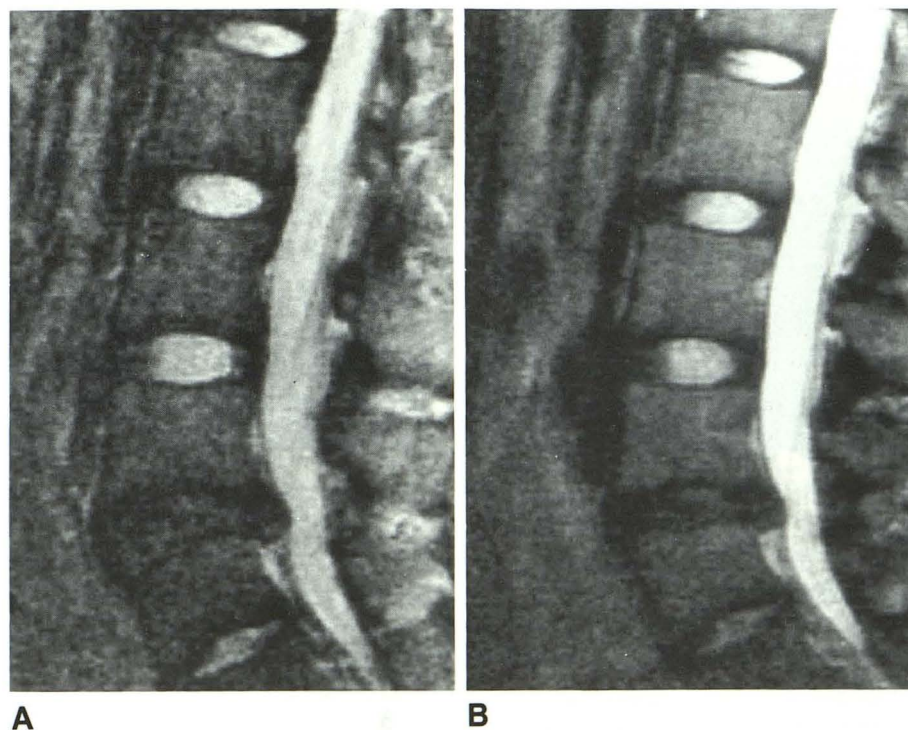


Fig. 4. Large herniation

A, Large L4-L5 herniation is seen on the conventional T2-weighted sagittal sequence, with dural tenting. There is a loss of signal from the L4 and L5 intervertebral disk spaces.

B, Similar findings are present on the turbo SE sagittal image.

Fig. 5. Canal stenosis.

A, Conventional T2-weighted sagittal sequence shows severe canal stenosis at L3-L4 and moderate stenosis at L4-L5, with indistinct intrathecal nerve roots. There is a loss of signal from the L3 and L4 intervertebral disks.

B, Turbo SE sequence shows the same findings, but with improved nerve root definition compared with the conventional T2-weighted sequence.

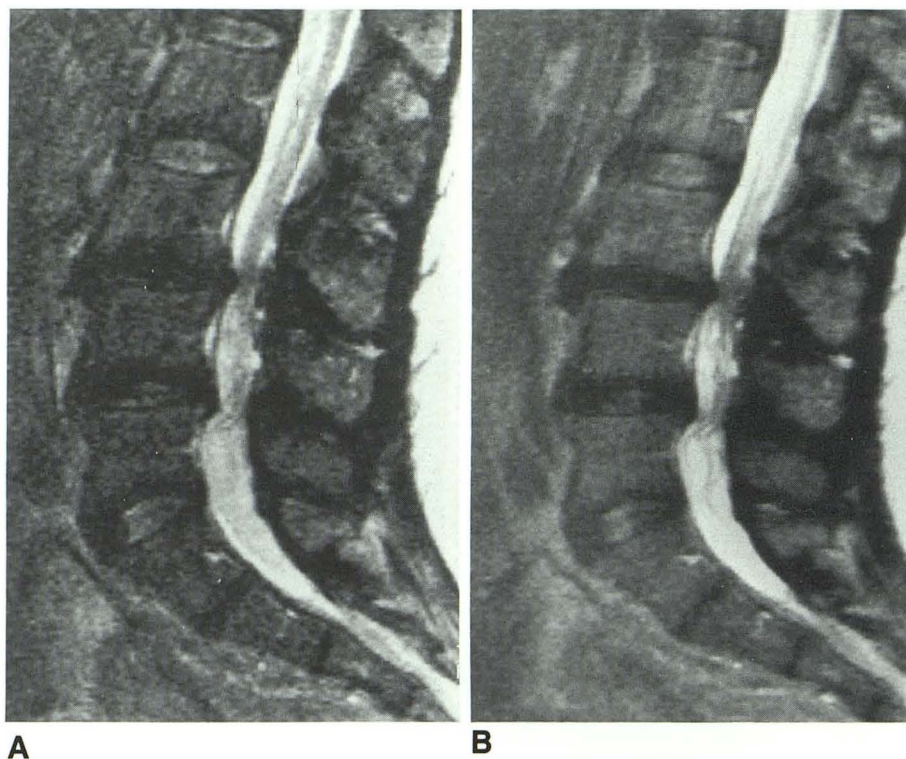
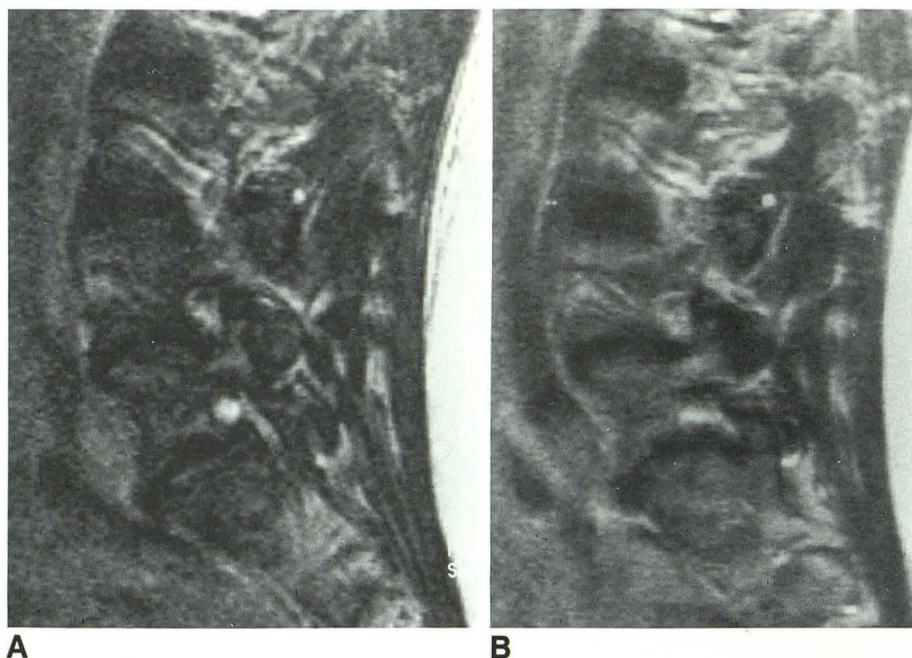


Fig. 6. Foraminal detail.

A, Conventional T2-weighted sagittal sequence through the neural foramina shows mild inferior stenosis at L4-L5 and at L5-S1.

B, Turbo SE sequence in the same patient shows the blurring effect of the RARE sequence for short T2 species (fat).



various manufacturers, for example, as "fast spin echo" (General Electric, Milwaukee, WI), FAME (Picker International, Cleveland, OH), or "turbo SE" (Siemens). For the implementation of these RARE sequences, factors to be considered include effective TE, TR, echo train length (ETL),

and interecho spacing (E_{space}). The effective TE of the sequence is defined as the time that the central Ky space is encoded, which determines tissue contrast. For the sequence implemented here, echoes were obtained every 23 milliseconds. The TE of 93 milliseconds was chosen to

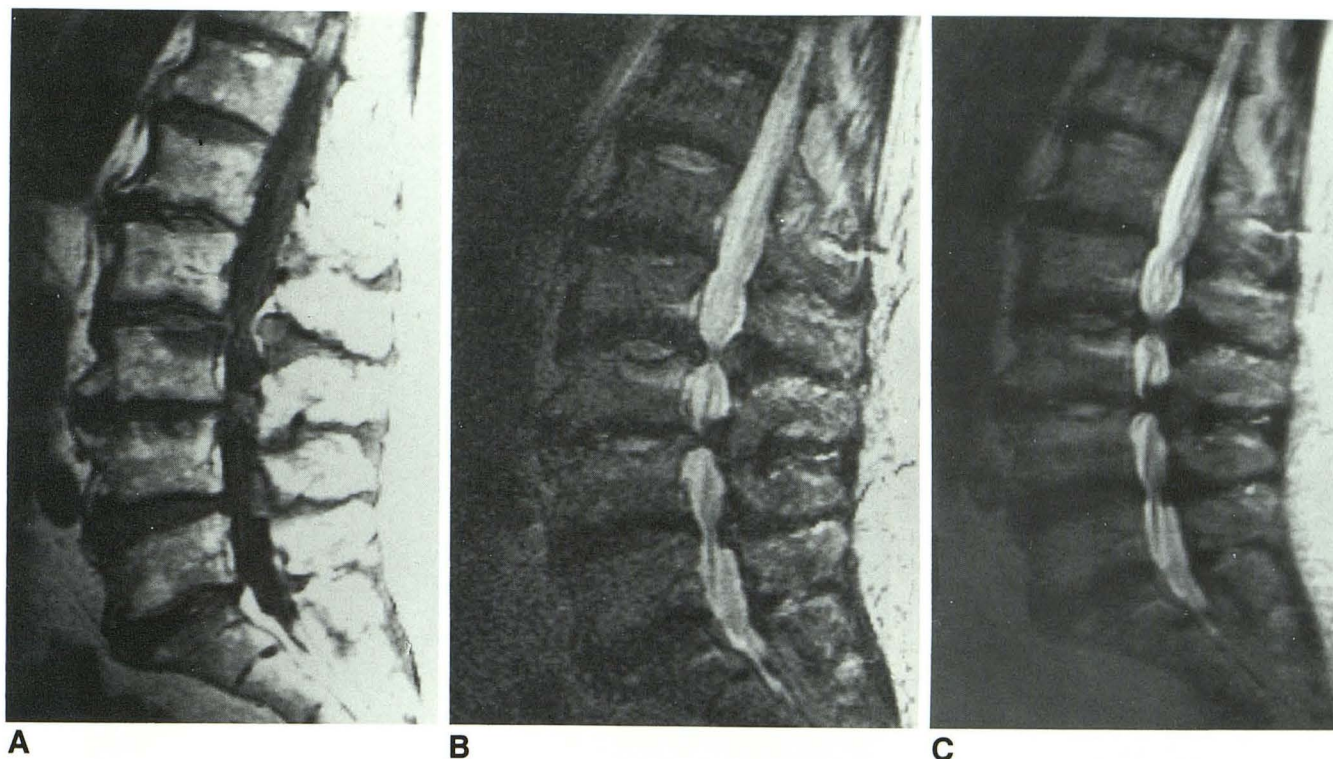


Fig. 7. Central canal stenosis with degenerative endplate changes.

A, Sagittal T1-weighted image shows a type I marrow change involving the superior endplate of L3 and a type II change involving L5-S1 endplates anteriorly.

B and C, Sagittal CSE (B) and turbo SE (C) demonstrate similar findings, including the high-signal L3 endplate, the loss of signal in multiple intervertebral disks, and severe canal stenosis. The fatty marrow of the type II end plate changes at L5-S1 and in the superior portion of the L4 body show very slight increased signal on the RARE sequence.

be as close as possible to the TE of the CSE sequence.

The initial evaluation of the RARE sequence showed that variations in the number of excitations, ETL, and TR followed theoretical predictions that have been previously described for RARE and CSE (9). In particular, increasing the TR or the number of acquisitions increased the S/N of the images. Increasing the ETL decreased the S/N of the sequence because of the contribution of later echoes. Similarly, a longer ETL increased CSF/extradural and CSF/intradural structure contrast-to-noise ratio for the same reason. The contrast-to-noise ratio for the vertebral bodies increased with increasing TR for ETLs of 4 and 8. On the basis of these results and the overall qualitative visual appeal, the 4000/93, ETL 8 sequence was chosen for the prospective comparison.

In this study, the sequence chosen for the clinical portion (4000/93, ETL 8) represents a compromise between high CSF signal intensity and examination time. The ETL affects the number of sections available for a given TR, the speed

of the sequence, and the amount of T2-dependent blurring present. As the ETL increases, the examination time decreases, but less time is available during the sequence for multisection implementation. Although this may have an effect in brain imaging with shorter TRs, the effect in sagittal lumbar spine imaging was nil. First, the TR was lengthened on the turbo SE sequence to increase the CSF signal. The longer TR secondarily allows an increased number of sections. With current software, a TR of 4000 allows 15 sections, whereas TRs of 3000 and 2000 allow 11 and 7 sections, respectively. Second, substantially fewer sagittal images are needed (~10) for coverage in the lumbar spine than are routinely obtained with axial images in the brain (~20).

We performed only a single TE-effective sequence in this study to compare the RARE technique with the late-echo conventional SE or the low-flip-angle GE sequences that are routinely used. The use of a single effective TE eliminated some potential problems of a double-echo sequence, namely, the intensity of the CSF on an early first echo. In a dual-echo sequence, to obtain

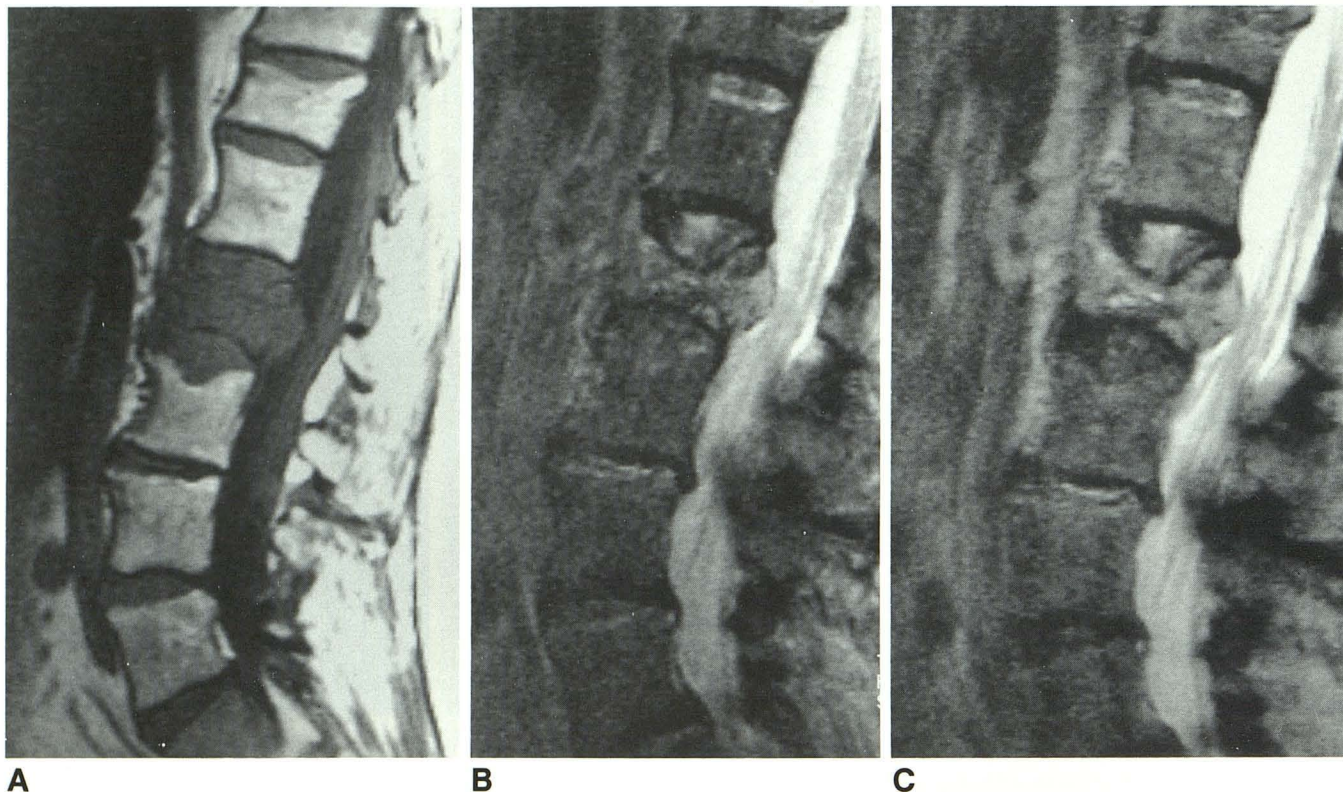


Fig. 8. Metastatic lymphoma.

A, Sagittal T1-weighted image shows tumor involvement of L2 with epidural extension and compression fracture.

B, Sagittal CSE image shows increased signal from the tumor and the thecal sac compression.

C, Turbo SE sagittal image shows findings equivalent to those of the conventional T2-weighted sequence, with the exception of overall slightly greater signal from the vertebral body marrow and tumor.

the late echo with a TR of 4000 would have meant an increased or isointense CSF signal on the early echo, which we find diagnostically unsatisfactory or unnecessary when the late echo is available. We did not attempt to vary the SE sequence parameters to match those of the RARE sequence, because this would have involved a clinically unacceptable examination time (25.6 minutes). A longer TR would have undoubtedly increased the signal of the CSF on the CSE sequence. However, the increased nerve root definition seen on the RARE sequence most likely relates to a combination of factors, including the longer TR and edge definition (high pass filter effect) for long T2 species inherent in the RARE sequence structure, which is not present with CSE.

The speed of the RARE sequence is maximized by using a longer ETL. This speed must be weighed against the T2-dependent blurring, which increases as ETL increases. This T2 filtering is present only along the phase-encoding axis. It is a direct result of the nonuniform weighting of k space, which occurs because each Ky line is

not collected at the same point along the T2 decay curve (7). For long T2 species (such as CSF), blurring is minimal; this accounts for the good clinical appearance of the extradural interface and the intradural nerve roots in this study. In other areas, where tissue T2 is much shorter (as in vertebral body marrow or foraminal fat), blurring is much more pronounced. Despite the readily apparent blurring in the region of the facets and neural foramina, the clinical effect was thought to be negligible. E_{spacing} shorter than the 23 milliseconds used in this study would be preferable, because this would produce less blurring and ghosting. However, problems involved in shortening the E_{space} include the finite width of the radio-frequency pulse and limited gradient strengths and switching times (7). Also, a very short E_{space} may result in an unacceptable specific absorption rate and section profile distortions (10).

Our preliminary experience with the RARE sequence showed no diagnostic difference in the appearance of various additional pathologies that may occur in the lumbar spine and that could

occur with low back pain and be confused clinically with degenerative disk disease. In particular, the evaluation of the T1-weighted images showed a total of 19 levels with type II endplate marrow changes and two levels with type I changes (11). The RARE sequence showed a very slight increased signal from the type II change, as compared with that of the CSE sequence, as would be expected from the contribution of the early echos giving increased signal from fat. No difference was seen in the appearance of type I changes (Fig. 7). Additionally, we have imaged patients with compression fractures (Fig. 1) and bony metastatic disease (Fig. 8) and have seen no difference between the two techniques.

Although RARE may produce decreased susceptibility artifacts in the brain, manifested as slightly decreased visibility of iron or hemorrhage, these issues are generally not applicable for the imaging of degenerative disk disease (12). Potential problems could involve the visibility of vacuum phenomena or calcification or gas associated with disk herniations. However, the advantage of the RARE sequence is less accentuation of extradural or foraminal disease relative to GE sequences because susceptibility artifacts are lessened (13).

If considered solely from a time perspective, this implementation of RARE does not provide dramatic savings. Our standard T2-weighted SE sequence takes 6.4 minutes, the standard GE sequence takes 5.1 minutes (fast imaging with steady precision, 400/10, 192 × 256 matrix), and the RARE sequence takes 3.3 minutes. What is gained by the use of the RARE sequence is the ability to increase the TR to 4000, with the corresponding increased CSF signal intensity and improved extradural interface.

In conclusion, the lumbar spine is an ideal site for implementation of the RARE sequence. Potential problems that may plague application in other areas, such as number of sections, CSF signal in short TE sequences, blurring, and CSF pulsatility, are either not present or are not clinically limiting. However, because of differences

between manufacturers and systems in methods of data collection, radio-frequency profiles, and gradient capabilities, the precise parameters implemented may vary. RARE sequences can replace conventional T2-weighted SE sagittal studies for degenerative lumbar disk disease. A corollary of this study is that RARE can also replace T2* GE sagittal images, because GE imaging is primarily implemented because of the time savings over conventional T2-weighted studies, not because T2* GE images have proved to be diagnostically superior to T2-weighted images.

References

1. Enzmann DR, Rubin JB. Cervical spine: MR imaging with a partial flip angle, Gradient-refocused pulse sequence. Part I. General considerations and disk disease. *Radiology* 1988;166:467-472
2. Mills TC, Ortendahl DA, Hylton NM, Crooks LE, Carlson JW, Kaufman L. Partial flip angle MR imaging. *Radiology* 1987;162:531-539
3. Murayama S, Numaguchi Y, Robinson AE. The diagnosis of herniated intervertebral disk with MR imaging: a comparison of gradient-refocused-echo and spin-echo pulse sequences. *AJNR: American Journal of Neuroradiology* 1990;11:17-22
4. Kulkarni MV, Narayana PA, McArdle CB, et al. Cervical spine MR imaging using multislice gradient echo imaging: comparison with cardiac gated spin echo. *Magn Reson Imaging* 1988;6:517-525
5. Hennig J, Naureth A, Freidburg H. RARE imaging: a fast imaging method for clinical MR. *Magn Reson Med* 1986;3:823-833
6. Hennig J, Freidburg H, Ott D. Fast three dimensional imaging of cerebrospinal fluid. *Magn Reson Med* 1987;5:380-383
7. Mulkern RV, Wong STS, Winalski C, Jolesz FA. Contrast manipulation and artifact assessment of 2D and 3D RARE sequences. *Magn Reson Imaging* 1990;8:557-566
8. Mansfield P, Maudsley AA. Planar spin imaging by NMR. *J Magn Reson* 1977;27:101-119
9. Edelman RR, Kleefield J, Wentz KU, Atkinson DJ. Basic principles of magnetic resonance imaging. In: Edelman RR, Hesselink JR, eds. *Clinical magnetic resonance imaging*. Philadelphia: Saunders, 1990:29-31
10. Vinitzki S, Mitchell DG, Rao VM, Ortega HA, Mohamed FB, Einstein S. Ultrashort-TE conventional and fast spin-echo imaging. *J Magn Reson Imaging* 1992;2(P):54
11. Modic MT, Steinberg PM, Ross JS, Masaryk TJ, Carter J. Degenerative disk disease: assessment of changes in vertebral body marrow with MRI. *Radiology* 1988;166:193-199
12. Jones KM, Mulkern RV, Mantello MT, et al. Brain hemorrhage: evaluation with fast spin-echo and conventional dual spin-echo images. *Radiology* 1992;182:53-58
13. Tsuruda JS, Remley K. Effects of magnetic susceptibility artifacts and motion in evaluating the cervical neural foramina on 3DFT gradient-echo MR imaging. *AJNR: American Journal of Neuroradiology* 1991;12:237-241