

# Generic Contrast Agents

Our portfolio is growing to serve you better. Now you have a *choice*.



[VIEW CATALOG](#)

# AJNR

## **Inflammatory pseudotumor of the maxillary sinus in a 15-year-old boy.**

J A Maldjian, K I Norton, G M Groisman and P M Som

*AJNR Am J Neuroradiol* 1994, 15 (4) 784-786

<http://www.ajnr.org/content/15/4/784>

This information is current as  
of May 17, 2025.

# Inflammatory Pseudotumor of the Maxillary Sinus in a 15-Year-Old Boy

Joseph A. Maldjian, Karen I. Norton, Gabriel M. Groisman, and Peter M. Som

**Summary:** Inflammatory pseudotumor is a benign neoplasm composed of fibroblasts, histiocytes, and inflammatory cells. Its occurrence in the paranasal sinuses is rare. We report a case of a 15-year-old boy with a maxillary sinus inflammatory pseudotumor that simulated an aggressive neoplasm on CT scan.

**Index terms:** Paranasal sinuses, neoplasms; Paranasal sinuses, computed tomography; Paranasal sinuses, inflammation; Pediatric neuroradiology

Inflammatory pseudotumor is a rare lesion characterized histologically by a proliferation of inflammatory cells, histiocytes, and fibroblasts mimicking a neoplastic process (1–3). It is thought to be a form of idiopathic pseudotumor (2) and has been reported most often to occur in the lungs and conducting airways, orbit, palatine tonsil, larynx, and gingival and periodontal tissues (1,2,4–6). Its occurrence in the maxillary sinus is rare (7–11), especially in children. We present a case of invasive maxillary sinus inflammatory pseudotumor in a 15-year-old boy.

## Case Report

A 15-year-old boy from Santo Domingo presented with a 6-week history of right eye pain and progressive right facial swelling. He also reported several episodes of epistaxis during the prior 3 months. The patient's medical history was otherwise unremarkable. Physical examination demonstrated proptosis of the right eye, with elevation of the globe, and facial swelling without erythema. Extraocular movements were intact, except for diplopia on left lateral gaze. There was no pain associated with extraocular movements. Bilateral submandibular, pretragal, and right axillary adenopathy were palpable. Laboratory examination demonstrated a slight hypochromic microcytic anemia (hemoglobin/hematocrit = 11.4 g/dL/35.4%). Serum electrolytes were normal, except for an elevated alkaline phosphatase level (183 U/L). The erythrocyte sedimentation

rate was 80 mm/h. Tuberculin test results were normal. A plain film of the chest was normal. Computed tomography (CT) of the head and neck demonstrated a large right maxillary sinus and nasal fossa mass, which extended into the infratemporal fossa (Fig 1). There was aggressive bone destruction of portions of the walls of the right maxillary sinus. In addition, most of the remaining antral bone was thickened and sclerotic, and in some areas had an amorphous appearance (Fig 1). There were also inflammatory changes in the left maxillary antrum. CT of the chest and abdomen was unremarkable, as was a skeletal survey. The results of serum protein electrophoresis, 24-hour urine collection, and bone marrow biopsy were normal. A bone scan demonstrated activity in both maxillary sinuses.

Right intranasal biopsy and antrostomy were performed. Tissue taken from the inferior meatus revealed respiratory-type epithelium, with focal erosion and underlying sheets of inflammatory cells admixed with fibroblasts and dense bands of collagen. The great majority of the inflammatory cells were plasma cells, with Russell bodies and small clusters of lymphocytes and polymorphonuclear cells. Multiple special stains for microorganisms (including *Mycobacterium leprae* and *Klebsiella rhinoscleromatis*) were negative. The patient was treated with corticosteroids (20 mg, three times daily), and a follow-up CT scan 2 months later revealed slight diminution in the size of the mass.

## Discussion

Inflammatory pseudotumor is a benign slow-growing lesion composed of an admixture of inflammatory cells, fibroblasts, and histiocytes (3,12,13). Other nomenclature applied to these lesions has included *plasma cell granuloma*, *mast cell granuloma*, *xanthogranuloma*, *pseudotumor*, and *histiocytoma* (5). The terms *inflammatory myofibroblastic tumor* and *inflammatory myofibrohistiocytic proliferation* have been proposed as more accurate descriptive names for these lesions (12,13). Histologically, the presence of

Received October 26, 1993; accepted for publication January 20, 1993.

From the Departments of Radiology (J.A.M., K.I.N., P.M.S.), Pathology (G.M.G.), and Otolaryngology (P.M.S.), Mount Sinai Medical Center, City University of New York.

Address reprint requests to Karen I. Norton, MD, Department of Radiology, Mount Sinai Medical Center, City University of New York, One Gustave L. Levy Place, New York, NY 10029.

AJNR 15:784–786, April 1994 0195-6108/94/1504-0784 © American Society of Neuroradiology



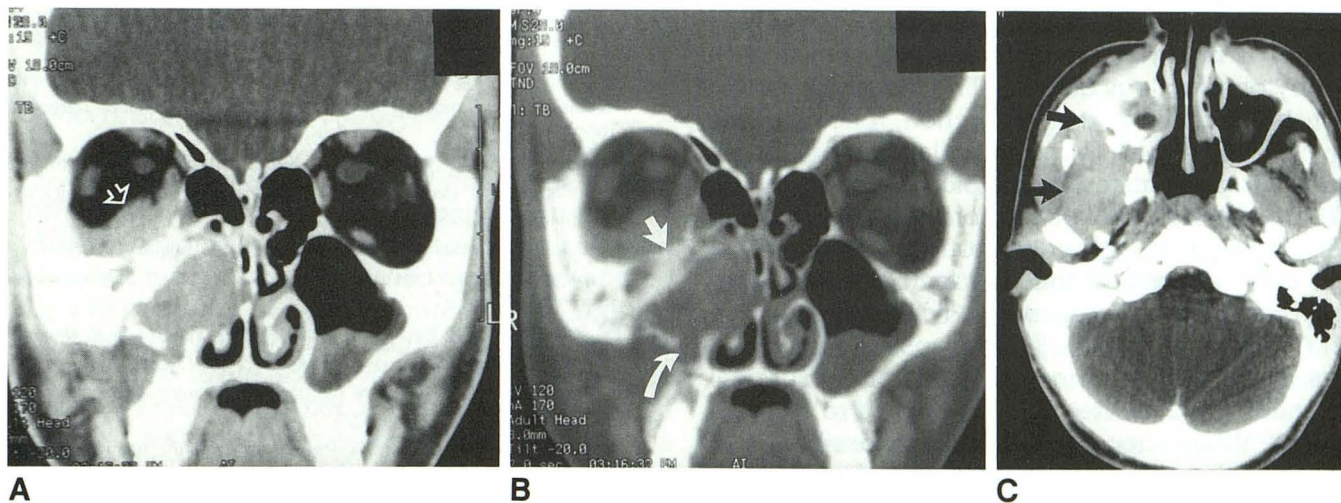


Fig. 1. A, Coronal narrow soft-tissue window; B, Wide bone window; C, Axial soft-tissue window. CT scans show a soft-tissue mass in the right maxillary sinus and right nasal fossa. The mass infiltrates the right infratemporal fossa (*black arrows*) obliterating the normal fat planes (compare with normal left side). The antral tumor extends into the right orbit (*open arrow*), and there are regions of bone destruction (*curved arrow*) and thickened and sclerotic bone (*solid white arrow*). There are incidental inflammatory changes in the left maxillary sinus.

Russell bodies is often used to distinguish inflammatory pseudotumor from a plasmacytoma, which has few, if any, of these bodies (14). The majority of inflammatory pseudotumor lesions present in the lungs as incidental masses on chest roentgenogram, usually in patients younger than 30 years of age (5,6). In children, inflammatory pseudotumor may be associated with microcytic hypochromic anemia, hypergammaglobulinemia, and high erythrocyte sedimentation rate (13,15). In the head and neck, they most commonly present with signs of orbital inflammation. Most orbital lesions are limited to the orbit (11). Involvement of the paranasal sinuses from orbital extension is uncommon (3,16,17), and inflammatory pseudotumor arising in the paranasal sinuses is rare (7-9,11).

Weisman et al (11) describe a pseudotumor of the maxillary sinus in a 63-year-old man. As in the case we present, this lesion simulated an aggressive neoplasm on CT, demonstrating bone destruction of the maxillary sinus. Takimoto et al (8) report a case of an inflammatory pseudotumor of the maxillary sinus in an 83-year-old man that also simulated an aggressive neoplasm. On CT scan this lesion demonstrated extensive destruction of the maxillary bone, with involvement of the nasal cavity and pterygoid fossa. De Miguel Garcia et al (10) report a case of inflammatory pseudotumor of the maxillary sinus in a 40-year-old man. This lesion also simulated an aggressive neoplasm on CT scan, with destruction of the maxillary sinus wall and extension into the eth-

moid and frontal sinuses. Benton et al (7) report a case of plasma cell granuloma of the middle ear and mastoid in a 37-year-old subject who, in retrospect, had a similar lesion of the maxillary sinus at the age of 27 years. This lesion was originally diagnosed as atypical histiocytosis X (7). In a series of 57 patients studied for the evaluation of preoperative maxillary sinus cytology, Nishoka et al (9) report only one case of inflammatory pseudotumor. However, no information is provided on the appearance of the lesion, its clinical presentation, or the age of the patient.

Three reported cases of inflammatory pseudotumor arising in the paranasal sinuses document the pertinent clinical and radiologic findings (8,11). In these cases, as in ours, the lesion simulated an aggressive neoplasm on CT, demonstrating invasion of surrounding structures with bone involvement. Despite its relative respect of anatomic boundaries in the orbit, inflammatory pseudotumor can apparently follow a more aggressive course in the paranasal sinuses. The significance of the sclerotic maxillary sinus bone is unclear. It may reflect the presence of chronic inflammation.

The diagnosis of pseudotumor in the paranasal sinuses is one of exclusion, but may be suggested based on clinical and imaging studies (11). When it demonstrates an aggressive appearance, as it did in our case, the diagnosis can be more challenging. Differentiation from carcinoma, aggressive fibrous lesions, lymphoma, or chronic fungal



disease may be impossible without biopsy. Early biopsy is recommended, to exclude such malignancy or infectious disease. The diagnosis should not be made by frozen section, because the diverse cell types found in inflammatory pseudotumor can make the histology confusing (4). The treatment of choice for orbital inflammatory pseudotumor is high-dose corticosteroids (11). It has been suggested that the lack of clinical response to such therapy may indicate the presence of a chronic or fibrotic form of pseudotumor or, less often, lymphoma (18). Complete surgical resection is advocated if the response to steroids is poor. When such resection is not possible, local radiation therapy has been shown to be effective in some cases (11).

## References

1. Gangemi M, Maiuri F, Giamundo A, Donati P, De Chiara A. Intracranial plasma cell granuloma. *Neurosurgery* 1989;24:591-595.
2. Figarella-Branger D, Gambarelli D, Perez-Castillo M, Garbe L, Grisoli F. Primary intracerebral plasma cell granuloma: a light immunocytochemical and ultrastructural study of one case. *Neurosurgery* 1990;27:142-147.
3. Pillai P, Saini JS. Bilateral sino-orbital pseudotumour. *Can J Ophthalmol* 1988;23:177-180.
4. West SG, Pittman DL, Coggin JT. Intracranial plasma cell granuloma. *Cancer* 1980;46:330-335.
5. Seider MJ, Cleary KR, van Tassel P, et al. Plasma cell granuloma of the nasal cavity treated by radiation therapy. *Cancer* 1991;67:929-932.
6. Bahadori M, Liebow AA. Plasma cell granulomas of the lung. *Cancer* 1973;1:191-208.
7. Benton NC, Korol HW, Smyth LT. Plasma cell granuloma of the middle ear and mastoid case report. *Ann Otol Rhinol Laryngol* 1992;101:92-94.
8. Takimoto T, Kathoh T, Ohmura T, Kamide M, Nishimura T, Umeda R. Inflammatory pseudotumour of the maxillary sinus mimicking malignancy. *Rhinology* 1990;28:123-127.
9. Nishioka K, Masuda Y, Yanagi E, Yuen K, Tanaka T, Ogura Y. Cytologic diagnosis of the maxillary sinus reevaluated. *Laryngoscope* 1989;99:842-845.
10. De Miguel Garcia F, Bori Aiguabella MA, Fernandez Lieas R, Rivares Esteban J, Martinez-Berganza y Asensio R, Vicente Gonzalez E. Inflammatory pseudotumor of the paranasal sinuses. *Acta Otorrinolaringol Esp* 1990;41:351-353.
11. Weisman RA, Osguthorpe JD. Pseudotumor of the head and neck masquerading as neoplasia. *Laryngoscope* 1988;98:610-614.
12. Stocker JT, Dehner LP, eds. *Pediatric pathology*. Philadelphia: Lippincott, 1992:549-551.
13. Tang TT, Segura AD, Oechler HW, et al. Inflammatory myofibrohistiocytic proliferation simulating sarcoma in children. *Cancer* 1990;65:1626-1634.
14. Batsakis JG, ed. *Tumors of the head and neck: clinical and pathological considerations*. Baltimore: Williams & Wilkins, 1979:472-473.
15. Dayy DL, Sane S, Dehner LP. Inflammatory pseudotumor of the mesentery and small intestine. *Pediatr Radiol* 1986;16:210-215.
16. Edwards MK, Zauel DW, Gilmor RL, et al. Invasive orbital pseudotumor-CT demonstration of extension beyond orbit. *Neuroradiology* 1982;3:215-217.
17. Eshaghian J, Anderson RL. Sinus involvement in orbital pseudotumor. *Arch Ophthalmol* 1981;104:380-384.
18. Flanders AE, Mafee MF, Rao VM, Choi KH. CT characteristics of orbital pseudotumors and other orbital inflammatory processes. *J Comput Assist Tomogr* 1989;13:40-47.