



**Contrast enhancement of brain tumors at different MR field strengths: comparison of 0.5 T and 2.0 T.**

K H Chang, D G Ra, M H Han, S H Cha, H D Kim and M C Han

*AJNR Am J Neuroradiol* 1994, 15 (8) 1413-1419

<http://www.ajnr.org/content/15/8/1413>

This information is current as of July 3, 2025.

# Contrast Enhancement of Brain Tumors at Different MR Field Strengths: Comparison of 0.5 T and 2.0 T

Kee Hyun Chang, Dong Gyu Ra, Moon Hee Han, Sang Hoon Cha, Hong Dae Kim, and Man Chung Han

**PURPOSE:** To compare the degree of MR contrast enhancement at 0.5 T and 2.0 T in various brain tumors. **METHODS:** MR images were studied prospectively in each of 31 patients with brain tumors (11 gliomas, 6 meningiomas, 6 neurinomas, and 8 others) before and after intravenous injection of gadopentetate dimeglumine. In every patient, both 0.5-T and 2.0-T MR studies were done within 1 week. Each patient received an initial standard dose (0.1 mmol/kg) of gadopentetate dimeglumine, followed by a subsequent 0.1-mmol/kg dose (total, double dose) in MR of each field strength. MR was done before and after each injection of the contrast agent. Degree of contrast enhancement in the lesions was assessed both visually and quantitatively. **RESULTS:** With standard-dose study, the tumor enhancement was visually stronger at 2.0 T than at 0.5 T in 9 gliomas. In extraaxial tumors there was visually no or minimal difference between 0.5 T and 2.0 T. Overall mean contrast-enhancement ratio and tumor and brain contrast-to-noise ratio were higher at 2.0 T than at 0.5 T by 53% and 108%, respectively. The double-dose study showed higher contrast-enhancement ratio and contrast-to-noise ratio than the standard-dose study at both field strengths, and the differences between 0.5 T and 2.0 T were almost similar to those of the standard-dose study. The degree of contrast enhancement with the standard dose at 2.0 T was comparable to that of the double dose at 0.5 T in most intraaxial tumors. **CONCLUSION:** The results suggest that effect of contrast enhancement increases with the field strength. Therefore, reevaluation of optimal doses of contrast media may be needed in a variety of brain lesions at each field strength.

**Index terms:** Brain, magnetic resonance; Brain, neoplasms; Magnetic resonance, comparative studies; Magnetic resonance, contrast enhancement

*AJNR Am J Neuroradiol* 15:1413–1419, Sep 1994

Gadopentetate dimeglumine has been widely used as an effective contrast agent for magnetic resonance (MR) of the central nervous system. Based on the results of preclinical (1, 2) and clinical studies (3–7), a dose of 0.1 mmol/kg has been recommended. The current standard

dose was derived from a study performed by Niendorf et al (7) at a field strength of 0.35 T. Although the influence of the magnetic field strength on the paramagnetic relaxation is well documented, its effect is often neglected in case of contrast media (8, 9).

The strength of the magnetic field modulates the contrast effect in two ways. First, the relaxivity of the contrast media in aqueous solution is field dependent. The relaxivity of gadopentetate dimeglumine decreases with increasing field strength (8, 9). Second, relaxation times of the tissue also depend on magnetic field strength; T1 in tissues increases with field strength, but T2 is hardly influenced by alterations in field strength (8, 10). Hausteiner et al (11) recently reported, however, that there were no significant differences in contrast enhancement among the field strengths in their clinical study. Yet in practice we found the contrast-enhancing

---

Received July 28, 1993; accepted after revision January 5, 1994.

This work was supported by the Schering Research Fund of the Korean Radiological Society, 1992.

Presented at the 31st Annual Meeting of the American Society of Neuroradiology, Vancouver, Canada, May 1993

From the Department of Radiology, Seoul National University College of Medicine (K.H.C., D.G.R., M.H.H., H.D.K., M.C.H.); and Department of Radiology, Chungbuk National University College of Medicine (S.H.C.); Seoul, Korea.

Address reprint requests to Kee Hyun Chang, MD, Department of Diagnostic Radiology, Seoul National University Hospital, 28 Yongon-dong, Chongno-gu, Seoul 110–744, Korea.

*AJNR* 15:1413–1419, Sep 1994 0195-6108/94/1508–1413

© American Society of Neuroradiology



effect to be substantially lower at 0.5 T than at 2.0 T with an injection of the same dose (0.1 mmol/kg) of the contrast agent in some intracranial lesions.

The purpose of the present study is to determine whether there is any difference in degree of contrast enhancement between 0.5 T and 2.0 T at both the standard and double doses and to see whether using the double dose of gadopentetate dimeglumine would improve clinical evaluation by obtaining the adequate contrast at both 0.5 T and 2.0 T.

## Subjects and Methods

Each of 31 patients (17 men and 14 women, ages 16 to 67 years) with intracranial tumors was prospectively examined with MR at both 0.5-T and 2.0-T field strengths. The diagnosis was histologically proved in 27 patients: 11 gliomas, 6 meningiomas, 6 neurinomas, and 1 each of lymphoma, pituitary adenoma, chordoma, and choroid plexus papilloma. There were two patients with presumed metastasis and two with unproved suprasellar tumors.

In all patients MR at 2.0 T was performed within 1 week after MR at 0.5 T, or vice versa. Fully informed consent was obtained in every patient. After precontrast T1- and T2-weighted spin-echo images were obtained, each patient received 0.1 mmol/kg of gadopentetate dimeglumine (Magnevist, Schering, Germany) then underwent the first enhanced T1-weighted imaging. Just afterward, another standard dose (total of 0.2 mmol/kg) was given, and the second postcontrast T1-weighted images were obtained in each MR study. Postcontrast T1-weighted imaging was performed within 5 minutes after each injection. The interval between the first and the second injection was approximately 6 to 8 minutes. Imaging parameters of T1-weighted images were the same at the two field strengths in a given patient: 500/30/2–4 (repetition time/echo time/excitations), 5-mm section thickness with a 2-mm gap. The field of view was 20 to 25 cm, with an acquisition matrix of  $256 \times 180$  to  $256$  in each scan. The imaging plane of postcontrast scans was same as that of precontrast scan in a given patient; it was axial in most patients but occasionally coronal or sagittal. Proton density-weighted (spin echo, 2500–3000/30/1–2) and T2-weighted (2500–3000/90/1–2) images were obtained in the axial planes at both field strengths. Tumor and brain contrast was assessed visually by two of us (K.H.C. and D.G.R.) and was also evaluated quantitatively. For the visual assessment, three pairs of T1-weighted images (a precontrast and two postcontrast images with both standard and double doses obtained at both field strengths) were displayed side by side. These were compared with respect to the degree and extent of visible enhancement. The differences of contrast enhancement between the two field strengths at both single- and double-dose levels were subjectively rated using a three-grade scale: no difference of enhancement, slight difference of enhancement, and

moderate to marked difference between the two field strengths. For the quantitative comparison of the contrast, we measured the signal intensity at the normal white matter of the contralateral hemisphere, tumor tissue, and background noise in the phase-encoding direction in the precontrast and postcontrast T1-weighted images. The signal intensity of tumor tissue was measured in enhancing areas. In cases of heterogeneous enhancement of tumor tissue, the area of maximum enhancement was selected for measurement. Measurements of a given structure in a given patient were made with a same-size circular region of interest, including an area of at least several pixels. The tumor and brain contrast-to-noise ratio was calculated as  $(SI_{\text{tumor}} - SI_{\text{normal}})/\text{noise SD}$ , where  $SI_{\text{tumor}}$  is the measured intensity of the tumor,  $SI_{\text{normal}}$  is the measured intensity of normal brain, and noise SD is the standard deviation of background noise.

In addition, the percent contrast-enhancement ratio was calculated as  $(SI_{\text{tumor,post}} - SI_{\text{tumor,pre}})/SI_{\text{tumor,pre}} \times 100$ , where  $SI_{\text{tumor,post}}$  is the measured intensity of tumor tissue in postcontrast images, and  $SI_{\text{tumor,pre}}$  is the measured intensity in precontrast images. For statistical analysis of contrast-to-noise and contrast-enhancement ratios between 0.5 T and 2.0 T, the paired Student's *t* test was used.

## Results

### Visual Assessment

Comparative visual assessments of the tumor enhancement between 0.5 T and 2.0 T are summarized in Table 1. At the single-dose level (0.1 mmol/kg), 45% (14 of 31 cases: 7 gliomas, 2 meningiomas, 1 neurinoma, and 4 others) showed stronger enhancement of the tumor on 2.0-T than on 0.5-T images (Fig 1); in three cases of glioma the contrast enhancement was apparent on only 2.0-T images, and 2 of 6 patients with meningioma demonstrated slightly but definitely greater enhancement in degree on 2.0-T images. In the remaining 55% (17 cases) there was no difference in visual assessment of the tumor enhancement between 0.5-T and 2.0-T images. In most extraaxial tumors the enhancement was moderate to marked in degree and appeared equally adequate at both field strengths (Fig 2). At the double-dose level, 39% (12 of 31: 5 gliomas, 3 meningiomas, and 4 others) revealed stronger enhancement with 2.0-T compared with 0.5-T images (Fig 1). The images of 2.0-T single-dose studies appeared comparable with those of 0.5-T double-dose studies in degree and extent of enhancement in 68% (21 of 31: 6 gliomas, 5 meningiomas, 6 neurinomas, and 4 others) and even superior to



**TABLE 1: Comparative visual assessment of tumor enhancement at 0.5 T and 2.0 T**

	0.5 T = 2.0 T	0.5 T < 2.0 T	
		+	++
Glioma (n = 11)			
Single dose	4 (1) <sup>a</sup>	6 (3) <sup>b</sup>	1
Double dose	6 (1) <sup>a</sup>	1 (1) <sup>b</sup>	4
Meningioma (n = 6)			
Single dose	4	2	0
Double dose	3	3	0
Neurinoma (n = 6)			
Single dose	5	1	0
Double dose	6	0	0
Others (n = 8) <sup>c</sup>			
Single dose	4	4 <sup>d</sup>	0
Double dose	4	4 <sup>d</sup>	0

Note.—0.5 T = 2.0 T indicates equal degree of enhancement at both field strengths; 0.5 T < 2.0 T indicates stronger enhancement on 2.0 T than on 0.5 T. + indicates slightly stronger enhancement on 2.0 T than on 0.5 T; ++, moderately to markedly stronger enhancement on 2.0 T than on 0.5 T.

<sup>a</sup> Number in parentheses indicates the number of cases showing no enhancement at both field strengths.

<sup>b</sup> Number of cases with no enhancement at 0.5 T but some enhancement at 2.0 T.

<sup>c</sup> Others include two cases each of metastasis and suprasellar tumors and one each of lymphoma, choroid plexus papilloma, pituitary adenoma, and chordoma.

<sup>d</sup> Includes two cases of metastasis and one each of suprasellar tumor and choroid plexus papilloma.

those of 0.5-T double-dose studies in 6% (1 each of glioma and meningioma).

As compared with the single-dose images, the double-dose images showed stronger enhancement of variable degree in 49% (15 of 31) each at a given field strength, either 0.5 T or 2.0 T (Fig 1); 2 cases of glioma showed the visible enhancement only at the double dose but not at the single dose on 0.5-T images. There was no such case at 2.0 T. In the majority of the meningiomas and neurinomas there was no visible difference in contrast enhancement between the single- and double-dose images at a given field strength, either 0.5 T or 2.0 T (Fig 2).

### Quantitative Assessment

The tumor and brain contrast-to-noise ratios at the two field strengths and dose levels are summarized in Table 2 and Figure 3. Tumor and brain contrast-to-noise ratio values in a total of 31 cases were higher with 2.0 T than with 0.5 T at each dose level ( $P < .001$ ). Mean values of contrast-to-noise ratio increased 100% (from 45.91 at 0.5 T to 95.53 at 2.0 T) at the single-

dose level and 116% (from 74.82 at 0.5 T to 161.78 at 2.0 T) at the double-dose level. In each group of gliomas ( $n = 11$ ), meningiomas ( $n = 6$ ), and neurinomas ( $n = 6$ ), the contrast-to-noise ratio values were all significantly higher with 2.0 T at each dose level ( $P < 0.05$ ). The difference of mean values of the contrast-to-noise ratios between the two field strengths was the largest at the single-dose level of the glioma group (168% increase from 26.11 at 0.5 T to 67.90 at 2.0 T), whereas it was the smallest at the single-dose level of the neurinoma group (69% increase from 80.38 at 0.5 T to 135.53 at 2.0 T).

Table 3 and Figure 3 summarize numerical values (mean  $\pm$  SD) of the contrast-enhancement ratios at the two field strengths and two dose levels. The mean value of the contrast-enhancement ratio ( $n = 31$ ) was higher with 2.0 T than with 0.5 T: at the single-dose level by 53% (62.81 versus 96.07;  $P < .001$ ) and at the double-dose level by 77% (89.25 versus 158.02;  $P < .001$ ). Each group of gliomas ( $n = 11$ ), meningiomas ( $n = 6$ ), and neurinomas ( $n = 6$ ) all revealed higher contrast-enhancement ratio values with 2.0 T at both the single-dose and double-dose levels than with 0.5 T ( $P < 0.05$ ). The greatest difference in mean contrast-enhancement ratio values between 0.5 T and 2.0 T was seen in the neurinoma group at the double-dose level (84%, 130.93 versus 240.45;  $P = .008$ ), whereas the smallest difference was noted in the neurinoma group at the single-dose level (35%, 108.66 versus 146.80;  $P = .009$ ).

Comparing the contrast-to-noise and contrast-enhancement ratio values of the single-dose level with those of the double-dose level, both the contrast-to-noise and contrast-enhancement ratio values increased with the double dose at a given field strength, either 0.5 T or 2.0 T. The increase rate of the contrast-to-noise and contrast-enhancement ratio values from the single dose to the double dose was greater at 2.0 T than at 0.5 T in all groups except the contrast-to-noise ratio of the glioma group.

### Discussion

In gadolinium-enhanced brain MR, the following factors regulate the contrast enhancement of the tissue: (a) biological factors such as vascularity and the blood-brain barrier of the brain



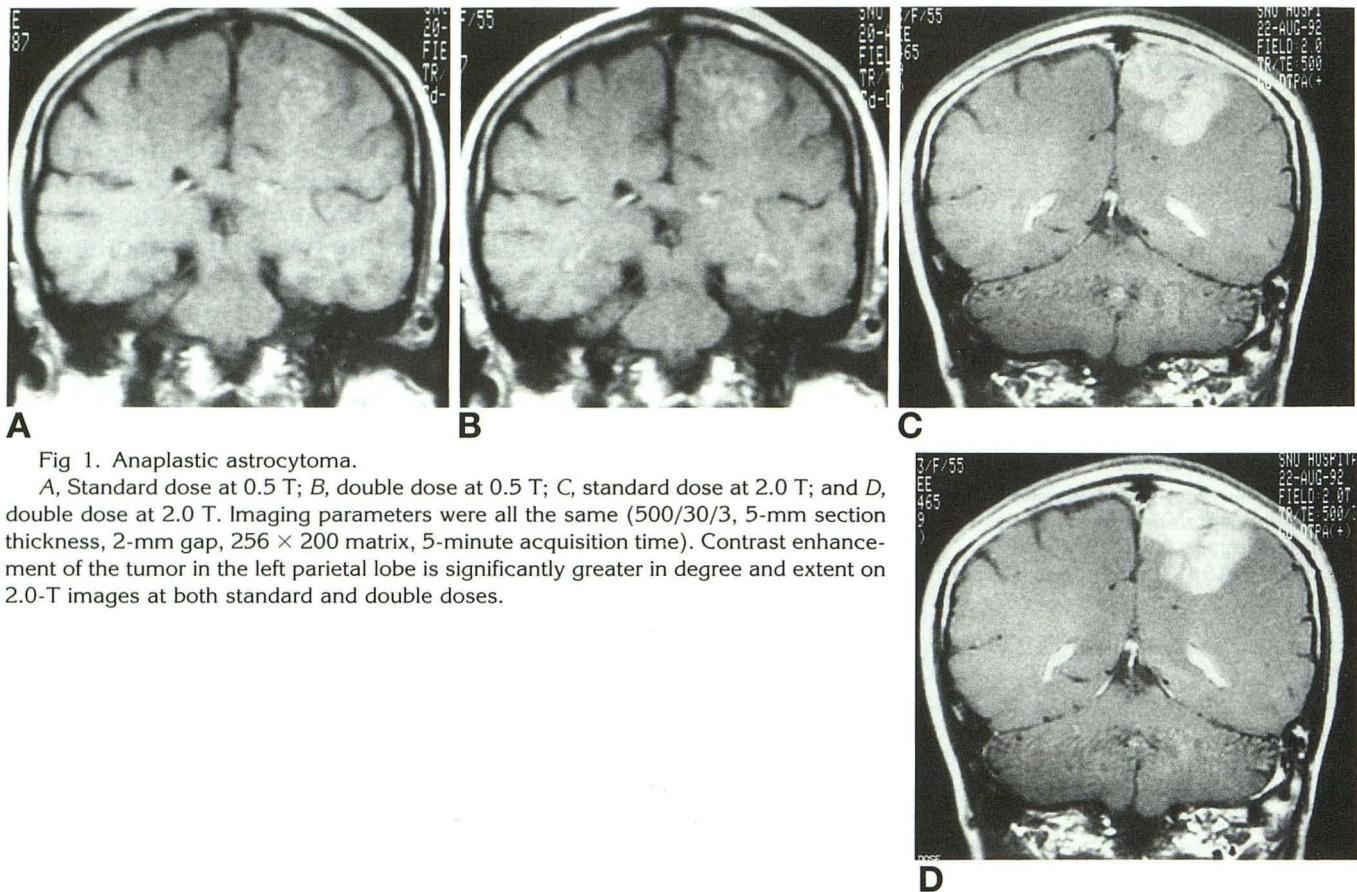


Fig 1. Anaplastic astrocytoma.

A, Standard dose at 0.5 T; B, double dose at 0.5 T; C, standard dose at 2.0 T; and D, double dose at 2.0 T. Imaging parameters were all the same (500/30/3, 5-mm section thickness, 2-mm gap, 256 × 200 matrix, 5-minute acquisition time). Contrast enhancement of the tumor in the left parietal lobe is significantly greater in degree and extent on 2.0-T images at both standard and double doses.

tissue; (b) distribution volume and concentration of the contrast media; (c) relaxivity of the contrast media; (d) intrinsic T1 relaxation time of the tissue; and (e) specifications of MR unit and imaging parameters, including pulse sequences and pulse sequence values. Of these factors the relaxivity of the contrast media and the intrinsic T1 of the tissue are field dependent (8–10). Therefore, the magnetic field strength affects the contrast enhancement in two ways. First, the relaxivity of the low-molecular-weight gadolinium compounds such as Gd-DTPA and Gd-DOTA decreases with increasing field strength within the current imaging field range. Both compounds show almost equal relaxivity at fields higher than 0.15 T, but Gd-DOTA has a greater relaxivity in the low-field range (9). Second, T1 of the tissue increases with field strength (8, 10). At low field strength the tissue already has a short T1 relative to that of a higher field; a further decrease of T1 after contrast injection will be small, leading to no or little significant increase in the signal intensity. Therefore, a very good effect of the contrast agents is seen in the high-field studies because

of the longer intrinsic T1 relaxation time of the tissue.

In the present study, the tumor and brain contrast-to-noise and contrast-enhancement ratios were significantly higher at 2.0 T than at 0.5 T at either the single-dose or double-dose level. In 23 of 31 cases the degree of contrast enhancement on 2.0-T single-dose images was visually comparable or even superior to that on 0.5-T double-dose images. In a study by Haustein et al (11), however, there were no statistically significant differences in enhancement among 0.5 T, 1.0 T, and 1.5 T. Various factors might contribute to this discrepancy, including interindividual (in the study by Haustein et al) versus intraindividual study design (in the present study) and different pulse sequences and field strengths. In the present study, we chose the intraindividual rather than interindividual study design because of higher reliability and better comparability of intraindividual data. Whether greater contrast enhancement at a higher field will lead to improved sensitivity and diagnostically relevant improvement in lesion



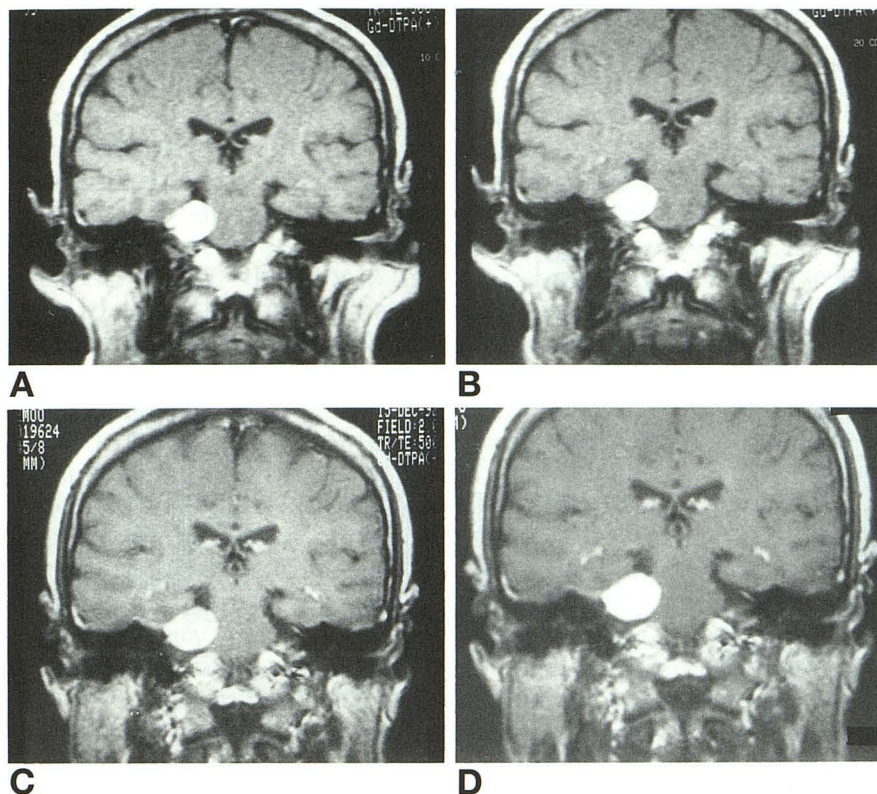


Fig 2. Cerebellopontine angle meningioma.

A, Standard dose at 0.5 T; B, double dose at 0.5 T; C, standard dose at 2.0 T; and D, double dose at 2.0 T. Imaging parameters of each scan were the same in Figure 1. There was no significant visual difference in enhancement between 0.5-T and 2.0-T images and between standard and double doses.

conspicuity remains to be further evaluated in prospective studies of larger populations.

In general, even with precontrast images the quality or contrast-to-noise ratios of images based on T1 or T2 discrimination increases with the field strength up to 1.5 to 2.0 T (10, 12). The behavior of T1 contrast-to-noise ratio versus field strength varies greatly from tissue pair to tissue pair, depending on minor details of the

field dependence of the measured T1. In one study (10), T1 contrast-to-noise ratios for tumor and muscle, kidney and liver, and liver and fat increases from 0.5 T up to 2.0 T, whereas the T1 contrast-to-noise ratio for muscle and kidney peaks at about 1.5 T. In another study (8), however, pure T1 contrast between normal brain tissue and pathologic lesions increased from low field strength to a maximum at medium field strength and decreased afterward. In the present study, we used the same pulse sequence on both the 0.5-T and 2.0-T images. Because there is prolongation of T1 at high field strength, the same pulse sequence would provide different tissue contrast in the same patient. In fact, almost all patients showed more T1-weighted contrast at 2.0 T than at 0.5 T. The difference of contrast between 0.5 and 2.0 T in mean value of tumor and brain contrast-to-noise ratios on unenhanced T1-weighted images, however, was not statistically significant ( $-10.43$  versus  $-11.45$ ;  $P > .1$ ).

The degree of the contrast enhancement is dose dependent. Tumor signal intensity increases with dosages from 0.025 to 0.3 mmol/kg (11). In the present series, the degree of contrast enhancement at the double-dose

TABLE 2: Tumor/brain contrast-to-noise ratio at 0.5 T and 2.0 T

	Contrast-to-Noise Ratio		P Value <sup>a</sup>
	0.5 T	2.0 T	
Total (n = 31)			
Single dose	45.91 ± 35.03	95.53 ± 60.88	<.001
Double dose	74.82 ± 42.65	161.78 ± 78.84	<.001
Glioma (n = 11)			
Single dose	26.11 ± 25.61	67.90 ± 45.16	=.001
Double dose	65.76 ± 50.36	133.50 ± 79.18	=.001
Meningioma (n = 6)			
Single dose	51.11 ± 23.05	108.75 ± 56.85	=.002
Double dose	74.01 ± 16.69	174.72 ± 63.84	=.005
Neurinoma (n = 6)			
Single dose	80.38 ± 22.81	135.53 ± 38.27	=.004
Double dose	112.94 ± 36.43	229.30 ± 51.08	=.012

Note.—Values were expressed as mean ± SD.

<sup>a</sup> Obtained with the paired *t* test.



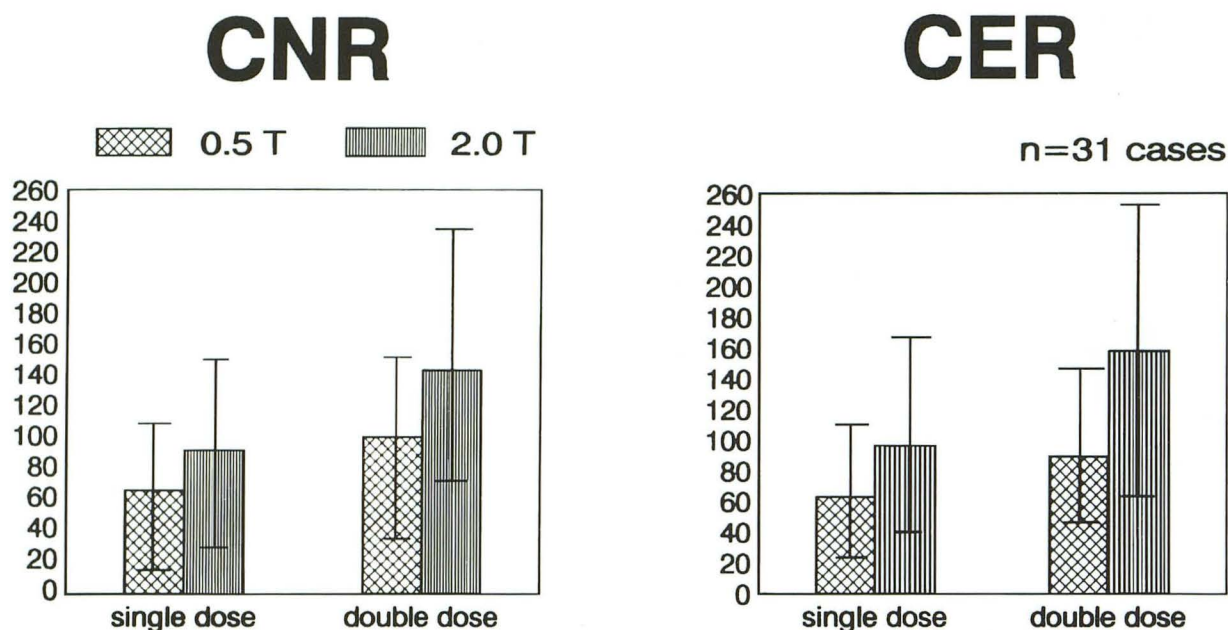


Fig 3. Mean values ( $\pm$ SD) of contrast-to-noise (CNR) and contrast-enhancement (CER) ratios as a function of field strength and dose. Mean contrast-to-noise and contrast-enhancement ratio values at 2.0 T are significantly higher than those at 0.5 T in both single- and double-dose studies ( $P < .05$ ).

level was significantly higher than that at the single-dose level at either 0.5 T or 2.0 T. In our experience, a half-dose (0.05 mmol/kg) produced different results for intraaxial and extraaxial tumors. Some gliomas did not display any distinct contrast enhancement after this dose. For extraaxial tumors, however, a dose of 0.05 mmol/kg produced much better enhancement. Extraaxial tumors such as meningiomas and neuromas show marked contrast enhancement after administration of single doses, indicating that smaller doses may be feasible (11).

Further studies are needed to clarify whether a dose reduction is affordable in the evaluation of the extraaxial tumors, particularly at the high field. Meanwhile, a double dose or more may be necessary in selected cases of the intraaxial tumors particularly at the low or medium field strength. In two cases of glioma in the present series, the contrast enhancement was seen at the double-dose level but not at the single-dose level at 0.5 T. Therefore, in our institute, one 20-mL vial of gadopentetate dimeglumine currently has been used in cases of intraaxial tumors at 0.5 T.

Besides the dose of contrast media, imaging time after administration of the contrast media is another factor that influences the enhancement. Enhancing lesions generally enhance soon after administration of the contrast media (5). Immediate postinfusion studies will show the vast majority of lesions. Immediate scanning after infusion is likely to be the preferred method, particularly in cases of extraaxial tumors. However, intraaxial brain tumors may show delayed uptake of contrast material at a given dose (6, 11). In a study on the temporal evolution of contrast enhancement (5), visible enhancement was most prominent in the initial sequence of most cases, but there were notable exceptions. The intensity of metastatic lesions

TABLE 3: Contrast-enhancement ratio at 0.5 T and 2.0 T

	Contrast-Enhancement Ratio		P Value <sup>a</sup>
	0.5 T	2.0 T	
Total (n = 31)			
Single dose	62.81 $\pm$ 41.51	96.07 $\pm$ 59.24	<.001
Double dose	89.25 $\pm$ 46.89	158.02 $\pm$ 83.80	<.001
Glioma (n = 11)			
Single dose	43.54 $\pm$ 26.54	65.41 $\pm$ 41.02	=.032
Double dose	81.87 $\pm$ 48.53	130.02 $\pm$ 80.62	=.008
Meningioma (n = 6)			
Single dose	77.57 $\pm$ 50.14	123.47 $\pm$ 73.22	=.016
Double dose	95.62 $\pm$ 49.85	174.76 $\pm$ 78.71	=.005
Neurinoma (n = 6)			
Single dose	108.66 $\pm$ 31.02	146.80 $\pm$ 39.22	=.009
Double dose	130.93 $\pm$ 33.32	240.45 $\pm$ 74.20	=.008

Note.—Values were expressed as mean  $\pm$  SD.

<sup>a</sup> Obtained with the paired *t* test.



was slightly brighter in the second enhanced T1-weighted images (18 to 33 minutes after injection). In one case of multiple sclerosis plaques, enhancement was most evident in the second and third T1-weighted sequences, the latter obtained 65 minutes after injection of gadopentetate dimeglumine (6). Increased enhancement at the double-dose level in the present study, therefore, might have been caused partly by the mechanism of delayed enhancement. In a study of determining the optimum dose of gadopentetate dimeglumine using a fractionated incremental dose (7), it was assumed that increases of the signal intensity in enhancing tumor tissue after the second and third injections were attributed predominantly to the additive effect of additional gadopentetate dimeglumine dose fractions, not to delayed enhancement from the previous dose fractions.

In summary, contrast enhancement was significantly stronger at 2.0 T than at 0.5 T in brain tumors at either single-dose or double-dose levels ( $P < .05$ ). With the current standard dose (0.1 mmol/kg) of gadopentetate dimeglumine three gliomas showed the enhancement only at 2.0 T but not at 0.5 T. In extraaxial tumors there was visually no or minimal difference in enhancement between 0.5 T and 2.0 T, even though mean values of tumor and brain contrast-to-noise and contrast-enhancement ratios were significantly higher at 2.0 T than at 0.5 T ( $P < .05$ ). In conclusion, our results suggest that the effect of contrast enhancement increases with the field strength. Thus, reevaluation of the optimal dose of the contrast media may be needed in a variety of brain lesions at each field strength.

## References

1. Weinmann HJ, Brasch RC, Press WR, Wesbey GE. Characteristics of gadolinium-DTPA complex: a potential NMR contrast agent. *AJR Am J Roentgenol* 1984;142:619-624
2. Brasch RC, Weinmann HJ, Wesbey GE. Contrast-enhanced NMR imaging: animal studies using gadolinium-DTPA complex. *AJR Am J Roentgenol* 1984;142:625-630
3. Laniado M, Weinmann HJ, Schorner W, Felix R, Speck U. First use of Gd-DTPA/dimeglumine in man. *Physiol Chem Phys Med NMR* 1984;16:157-165
4. Felix R, Schorner W, Laniado M, et al. Brain tumors: MR imaging with gadolinium-DTPA. *Radiology* 1985;156:681-688
5. Brant-Zawadzki M, Berry I, Osaki L, Brasch R. Temporal evolution of Gd-DTPA contrast enhancement of intracranial lesions viewed with magnetic resonance imaging. In: Runge VM, Claussen C, Felix R, James AE, eds. *Contrast Agents in Magnetic Resonance Imaging*. Amsterdam: Excerpta Medica, 1986:118-120
6. Schorner W, Laniado M, Niendorf HP, Schubert C, Felix R. Time-dependent changes in image contrast in brain tumors after gadolinium-DTPA. *AJNR Am J Neuroradiol* 1986;7:1013-1020
7. Niendorf HP, Laniado M, Semmler W, Schorner W, Felix R. Dose administration of gadolinium-DTPA in MR imaging of intracranial tumors. *AJNR Am J Neuroradiol* 1987;8:803-815
8. Rinck PA, Fischer HW, Elst LV, Haverbeke YV, Muller RN. Field-cycling relaxometry: medical applications. *Radiology* 1988;168:843-849
9. Muller RN, Elst LV, Rinck PA, et al. The importance of nuclear magnetic relaxation dispersion (NMRD) profiles in MRI contrast media development. *Invest Radiol* 1988;23 (suppl 1):S229-S231
10. Hart HR, Bottomley PA, Edelstein WA, et al. Nuclear magnetic resonance imaging: contrast-to-noise ratio as a function of strength of magnetic field. *AJR Am J Roentgenol* 1983;141:1195-1201
11. Hausteil J, Laniado M, Niendorf HP, et al. Administration of gadopentetate dimeglumine in MR imaging of intracranial tumors: dosage and field strength. *AJNR Am J Neuroradiol* 1992;13:1199-1206
12. Crooks LE, Arakawa M, Hoenninger J, McCarten B, Watts J, Kaufman L. Magnetic resonance imaging: effects of magnetic field strength. *Radiology* 1984;151:127-133

Please see the commentary on page 1420 in this issue.