



Discover Generics

Cost-Effective CT & MRI Contrast Agents



WATCH VIDEO

AJNR

Thrombolytic therapy in acute occlusion of the intracranial internal carotid artery bifurcation.

O Jansen, R von Kummer, M Forsting, W Hacke and K Sartor

AJNR Am J Neuroradiol 1995, 16 (10) 1977-1986

<http://www.ajnr.org/content/16/10/1977>

This information is current as
of June 22, 2025.

Thrombolytic Therapy in Acute Occlusion of the Intracranial Internal Carotid Artery Bifurcation

Olav Jansen, Rüdiger von Kummer, Michael Forsting, Werner Hacke, and Klaus Sartor

PURPOSE: To evaluate efficacy and clinical benefit of early thrombolytic therapy in intracranial internal carotid artery occlusion. **METHODS:** Thirty-two patients (mean age, 56 years) with acute intracranial internal carotid artery occlusion were studied clinically and with CT and angiography before and after thrombolytic therapy with intravenous alteplase ($n = 16$), superselective intraarterial alteplase ($n = 8$), and superselective intraarterial urokinase ($n = 8$). **RESULTS:** Initial CT showed a large parenchymal hypodensity in 11 (34%) patients, a small hypodensity in 15 (47%) patients, and no hypodensity in 6 (19%) patients. Recanalization after thrombolytic therapy was observed in 4 patients (12.5% in each treatment group). Follow-up CT showed six hemorrhagic infarcts and four parenchymal hematomas unrelated to recanalization, alteplase, or urokinase administration, but commonly associated with intraarterial treatment. Clinical outcome was fatal in 53%, poor in 31%, and moderate or good in 16% of the patients. Outcome was equal in different treatment groups and closely linked to both the quality of leptomeningeal collaterals and the extent of parenchymal hypodensity on the first CT. **CONCLUSION:** Because intravenous or intraarterial treatment with alteplase or urokinase fails to recanalize the vascular obstruction, it does not improve the prognosis of intracranial internal carotid artery occlusion over that of the natural course. Improved results may be possible with novel recanalization techniques.

Index terms: Thrombolysis; Arteries, carotid, internal; Arteries, stenosis and occlusion; Interventional neuroradiology

AJNR Am J Neuroradiol 16:1977–1986, November 1995

Acute occlusion of the distal intracranial segment of the internal carotid artery causes sudden severe hemispheric ischemia. This type of arterial occlusion most often is embolic (1). It may extend from the supraclinoid portion of the carotid siphon into the proximal segments of the anterior and middle cerebral arteries, thus obstructing not only the intracranial internal carotid artery bifurcation (carotid T) with the two major arteries that supply the cerebral hemisphere but frequently also the ostia of the anterior choroidal artery as well as the lenticulostri-

ate, or anterior central, arteries. Such occlusion results in ischemic edema and infarction of the basal ganglia; internal capsule; and the frontal, temporal, and parietal lobes, and causes a severe hemispheric neurologic syndrome. In the literature, neither the symptomatology of this type of stroke nor its natural course have received much attention. A few studies showed that intracranial internal carotid artery stenosis is a dangerous lesion, being highly related to stroke and death (2–4). Mortality in patients with middle cerebral artery occlusion ranges between 5% and 45% (5–7). This wide range of mortality rates, reported in different studies, can be explained by the lack of angiographic control and the analysis of quite varied types of occlusion. We noted a higher mortality rate (about 50%) in patients with complete embolic intracranial internal carotid artery occlusion, particularly if the middle cerebral artery trunk was included, which resulted in more severe and more extensive ischemic edema.

Received January 26, 1995; accepted after revision April 10.

From the Departments of Neuroradiology (O.J., R.v. K., M.F., K.S.) and Neurology (W.H.), University of Heidelberg (Germany) School of Medicine.

Address reprint requests to Olav Jansen, MD, Department of Neuroradiology, University of Heidelberg School of Medicine, Im Neuenheimer Feld 400, D-69120 Heidelberg, Germany.

AJNR 16:1977–1986, Nov 1995 0195-6108/95/1610–1977

© American Society of Neuroradiology

TABLE 1: Patients with acute intracranial internal carotid artery occlusion before different thrombolytic therapy

	All Alteplase/Urokinase	Intravenous Alteplase	Intraarterial Alteplase/Urokinase	Intraarterial Alteplase	Intraarterial Urokinase	Significance
No. of patients	32	16	16	8	8	
Age, y	55.8 ± 10.4	53.8 ± 11.7	57.7 ± 8.9	56.9 ± 8.3	58.6 ± 9.9	*
Sex, M/F	18/14	10/6	8/8	5/3	3/5	
Interval, min, between symptom onset and:						
CT Thrombolysis	146.0 ± 72.9	147.6 ± 72.5	120.2 ± 69.3	111.2 ± 31.4	192.2 ± 94.8	*
SSS ₀	245.1 ± 64.7	254.3 ± 73.4	235.9 ± 55.6	209.0 ± 34.7	262.8 ± 61.5	†
RS ₀	16.8 ± 6.2	16.9 ± 6.3	16.6 ± 6.2	19.8 ± 4.3	13.4 ± 6.3	*
Collaterals	4.9	5	4.9	5	4.9	*
Good						‡
Poor	12	6	6	2	4	
CT Hypodensity	20	10	10	6	4	
None						‡
Small	6	4	2	0	2	
Large	15	7	8	5	3	
	11	5	6	3	3	

* $P > .05$ (unpaired t test).

† $P > .05$ (Mann-Whitney U test).

‡ $P > .05$ (χ^2 test).

Note.—SSS₀ indicates Scandinavian stroke score at admission (\pm SD); RS₀, modified Rankin scale at admission.

The site of intracranial embolic occlusion primarily depends on the size and shape of the embolus, which along with the fibrin content within the thrombus determines success or failure of any type of thrombolytic therapy (8). It recently was shown that the site of arterial occlusion and the quality of leptomeningeal collaterals predict symptoms and clinical outcome in patients with acute embolic stroke (9, 10). It was shown further that successful thrombolytic recanalization of vascular occlusions in the anterior cerebral circulation is associated with good clinical outcome (11–14). The purpose of thrombolytic treatment in occlusion of intracranial vessels is not, however, to act on the infarcted tissue, but to prevent the ischemic core from increasing and to return the ischemic penumbra to normal function.

Detailed information about thrombolytic therapy in patients with acute hemispheric stroke and arterial occlusion at different intracranial sites still is lacking. To analyze various approaches of early thrombolytic therapy in intracranial internal carotid artery occlusion as to recanalization rate, safety, and clinical benefit, we followed prospectively 32 patients treated with systemic intravenous or superselective intraarterial thrombolytic therapy. The clinical outcome was assessed using two neurologic scores after 4 weeks.

Material and Methods

From February 1988 to April 1994, we recruited 137 consecutive patients with acute stroke for thrombolytic therapy. Among these patients were 32 with intracranial internal carotid artery occlusion plus occlusion of the middle cerebral artery trunk; these patients are the subject of this report. All 137 patients were admitted to our hospital within 4 hours of onset of symptoms. Each patient's status was documented by neurologic examination at admission and after 4 weeks using the Scandinavian stroke scale (SSS₀/SSS₄) (15) and the modified Rankin scale (RS₀/RS₄) (16), scoring death as 6. Inclusion criteria for this study were: (a) a precisely defined and witnessed onset of hemiparesis within the last 6 hours before thrombolytic therapy; (b) no evidence of intracranial hemorrhage or tumor or of severe cerebral microangiopathy on pretreatment computed tomography (CT); (c) angiographic evidence of complete occlusion of the carotid T; (d) informed consent from the patient or relatives.

The first CT was 32 to 311 minutes (mean, 146 minutes; SD, 72 minutes) after symptom onset (Table 1). All CT scans were obtained unenhanced, with axial section orientation, on a Picker 1200 SX or a Picker PO 2000 scanner (Picker International, Highland Heights, Ohio) using a section thickness of 8 mm throughout the brain; they were read prospectively by a neuroradiologist who was aware of the patient's clinical status. The interpreter determined regions of parenchymal hypodensity having an arterial distribution. These hypodensities were not the correlate of the final infarct area but, according to recent results (17), reflect early ischemia as seen on CT. The size of a hypodense area was called *small* if it covered less than 50% of the presumed middle cerebral artery territory and

large if it covered more than 50% (Fig 1A). A second CT was obtained 1 to 8 days after therapy to assess the size of infarct as well as to reveal or exclude any intracerebral lesions indicating intracerebral hemorrhage (Fig 1B). Hemorrhages were defined as *hemorrhagic infarct* or as *parenchymal hematoma*, according to criteria given by Pessin et al (18).

Within 6 hours of onset of symptoms, we performed arterial digital subtraction angiography of the entire anterior circulation by injecting both carotid arteries. The site and extent of arterial occlusion (Fig 1C) and the collateral blood supply were determined semiquantitatively by a neuroradiologist who graded the collateral circulation as *poor* if there were no collaterals (or only a few with slow flow), and *good* if there were many leptomeningeal collaterals from the anterior cerebral artery (Fig 1D). To avoid additional time-consuming catheterization of the vertebral arteries, we did not evaluate potential leptomeningeal collaterals from the posterior circulation. Recanalization was determined on the basis of a second angiogram obtained immediately after thrombolytic therapy (Fig 1F). Recanalization was defined as restoration of antegrade blood flow with adequate washout of contrast material.

Thrombolytic therapy was initiated within 6 hours of symptom onset in all patients. We treated the first 16 patients with intravenous alteplase infusion. After an initial bolus of 15 mg, 50 mg of alteplase dissolved in distilled water was infused over 30 minutes and another 35 mg over the next 60 minutes. Because we found that with intravenous treatment few vessels recanalized, we switched to superselective intraarterial infusion in the remaining 16 patients. The first 8 of these patients received alteplase; the subsequent 8 patients received urokinase. The agents were applied through a microcatheter (Tracker 18, Target Therapeutics, Fremont, Calif) placed next to the thrombus. By way of repeated angiography every 30 minutes, we checked the position of the microcatheter and simultaneously assessed the effect of the thrombolytic agent; if necessary, we corrected the catheter position. In about 30%, we were able to pass the thrombus with the microcatheter without effort once to explore the length of the obstruction and the degree of circulation beyond it (Fig 1E). Despite this manipulation, we did not observe significant fragmentation of the thrombus or any change in the overall angiographic appearance.

Alteplase (100 mg) was dissolved in 100 mL of distilled water; after a bolus injection of 10 mg of alteplase, we injected alteplase by hand in doses of 2 to 5 mg every 5 minutes until either recanalization or an upper dose limit of 100 mg was reached. We dissolved 500 000 IU of urokinase in 50 mL of distilled water. After a bolus dose of 100 000 IU injected through the guide catheter into the internal carotid artery by hand, 1 000 000 IU of urokinase per hour was infused through the microcatheter until either recanalization or an upper dose limit of 1 500 000 IU urokinase was reached. At the end of the procedure, the introducer sheath was left in place for 24 hours, fixed to the skin to avoid hemorrhage at the puncture site; the sheath was continuously flushed with heparinized saline solution

to avoid local thrombosis. Along with the thrombolytic agent, a bolus of 5000 IU of heparin was injected intravenously. Heparinization then was continued by infusion of 1000 to 1500 IU/h with the goal of doubling the activated partial thromboplastin time. If the second CT revealed parenchymal cerebral hemorrhage, heparinization was discontinued.

Recanalization was assessed by transcranial Doppler ultrasonography 24 hours later. After 4 weeks, clinical outcome again was scored by SSS₄ and RS₄. The relationship between neuroradiologic baseline characteristics and arterial recanalization was determined by χ^2 tests, Mann-Whitney *U* test, and unpaired *t* tests using StatView 4.0 (Abacus Concepts, Berkeley, Calif).

Results

Patient Baseline Characteristics in Different Treatment Groups

Patient baseline characteristics are listed in Table 1. Age, sex, intervals between symptom onset and first CT scan and start of thrombolysis, neurologic status at admission, state of collaterals, and extent of parenchymal hypodensity as shown by first CT did not differ significantly between treatment groups ($P > .05$). All patients presented with a severe hemispheric syndrome; the mean SSS₀ was 16.8 ± 6.2 (range, 6 to 25).

In most cases, the carotid occlusion extended from the origins of the ophthalmic or posterior communicating arteries to the internal carotid artery bifurcation (Fig. 1C).

We suspected a cardiogenic embolus in 17 patients who had a history of cardiac dysrhythmia or valve disease and in 1 patient with an open foramen ovale. As a source for distal embolic occlusion, spontaneous dissection of the internal carotid artery that supplied the symptomatic cerebral hemisphere was found in 6 patients; in one patient who had severe atherosclerosis including both carotid bifurcations, we suspected a local thrombosis of the internal carotid artery bifurcation. In 7 patients, the cause of carotid occlusion remained unknown. Different causes were homogeneously distributed in the three treatment groups.

Clinical Outcome

Seventeen (53%) patients died within 24 days (mean, 4 days) after the onset of symptoms: 11

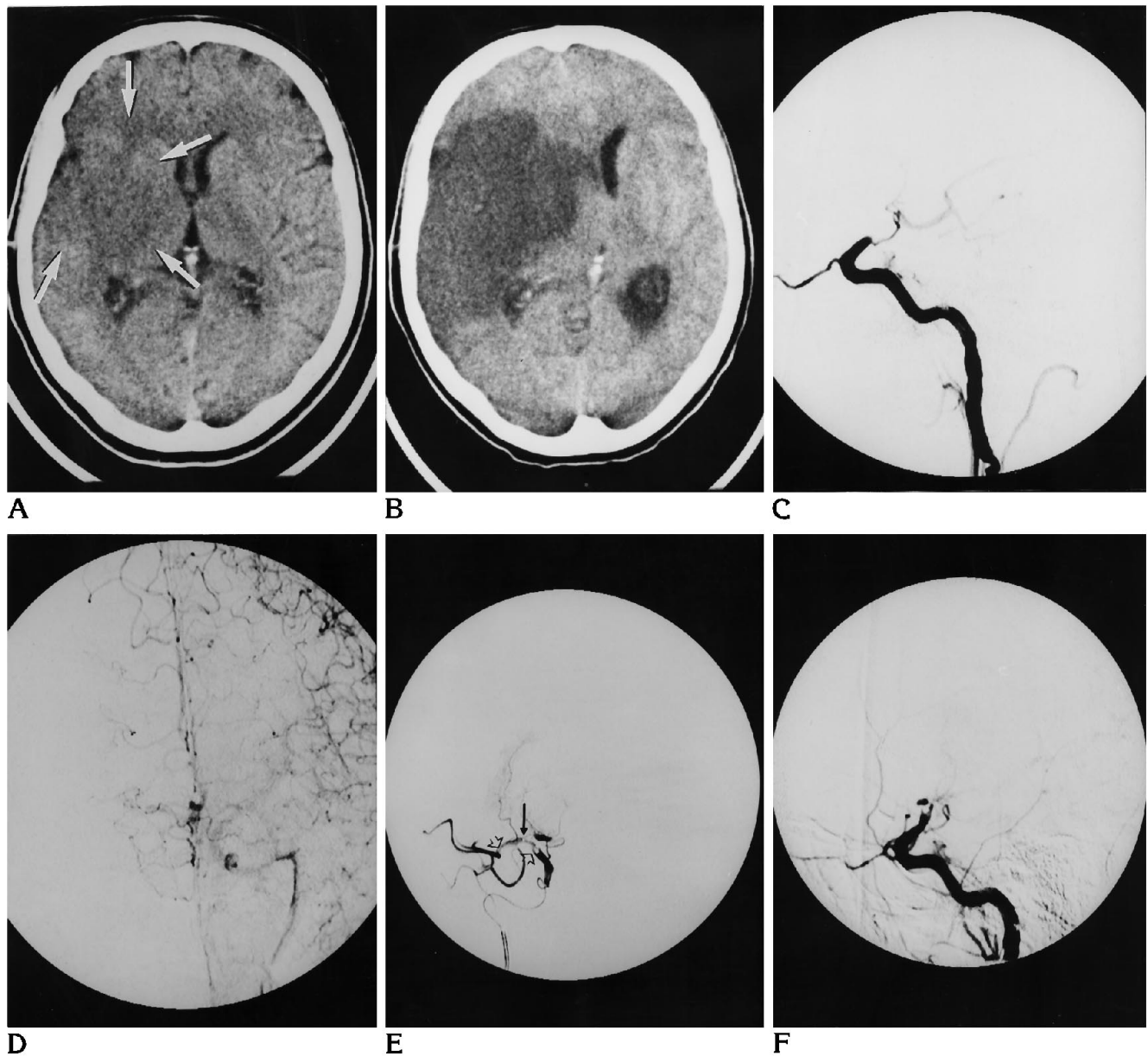


Fig 1. Images obtained in a 64-year-old man with history of cardiac dysrhythmia and acute right-hemispheric syndrome.

A, Noncontrast CT 4.5 hours after onset of symptoms shows effacement of right-sided cerebral sulci and parenchymal hypodensity (arrows) covering more than 50% of the middle cerebral artery territory.

B, Second CT 1 day after thrombolytic therapy shows well-demarcated infarction with space-occupying effect.

C, Right carotid arteriogram, lateral view, obtained 5 hours after onset of symptoms shows complete occlusion of the intracranial internal carotid artery including the ostium of the anterior choroid artery.

D, Left carotid arteriogram, anteroposterior view, shows crossfilling of the right anterior cerebral artery but poor leptomeningeal collaterals without evidence of retrograde filling of the right middle cerebral artery territory.

E, Superselective middle cerebral artery arteriogram during intraarterial thrombolysis with the tip of the microcatheter (black arrow) temporarily placed in the proximal M-1 segment shows the embolus to extend from the carotid T to the middle cerebral artery bifurcation (open arrows).

F, Lateral right carotid injection arteriogram after superselective intraarterial thrombolysis (1 500 000 IU urokinase/90 min) shows only minor thrombolytic effect at the proximal embolus surface with persistence of total occlusion of the carotid T.

TABLE 2: Outcome of patients with acute intracranial internal carotid artery occlusion after different thrombolytic therapies

	All Alteplase/ Urokinase	Intravenous Alteplase	Intraarterial Alteplase/ Urokinase	Intraarterial Alteplase	Intraarterial Urokinase	Significance
No of patients	32	16	16	8	8	
Recanalization						
at 8 h	4	2	2	1	1	
at 24 h	4	2	2	1	1	
Hemorrhage						
Hemorrhagic infarct	6	0	6	4	2	
Parenchymal hematoma	4	1	3	1	2	
Outcome*						†
Good (RS 1-3)	5	3	1	1	0	
Poor (RS 4-5)	10	5	6	2	4	
Fatal (RS 6)	17	8	9	5	4	
SSS ₄	14.2 ± 18.9	17.3 ± 20.4	13.5 ± 17.9	13.3 ± 20.8	13.8 ± 15.8	‡

* Clinical status after 4 weeks measured by Rankin scale (RS).

† $P > .05$ (χ^2 test).

‡ $P > .05$ (unpaired t test).

Note.—SSS₄ indicates Scandinavian stroke score after 4 weeks (\pm SD).

patients died because of malignant brain edema followed by transtentorial herniation; 4 patients died from massive intracranial hemorrhage; one patient had renal failure after decompressive craniectomy and died on day 24; and another patient died from cardiac failure (on day 4). Among the patients who survived, clinical outcome was poor (RS, 4 to 5) in 10 (31%) and good (RS, 0 to 3) in 5 (16%). As to clinical outcome, there was no difference in the various treatment groups ($P > .2$).

Leptomeningeal Collaterals and Parenchymal Hypodensity

Collateral blood flow via the anterior communicating artery and leptomeningeal vessels was rated good in 12 patients and poor in 20 patients. Poor collaterals were associated with fatal or poor clinical outcome ($P = .0004$); 16 (80%) patients died, and 3 (15%) patients had poor outcomes. The positive predictive value of poor collaterals for death was 80% (16 of 20). The positive predictive value of good collaterals for survival was 92% (11 of 12); 4 (30%) patients had good and 7 (58%) patients had poor outcomes. Four of 5 patients with good clinical outcome had good collaterals.

Poor collaterals also were associated with more extended parenchymal hypodensities as shown by initial CT ($P = .0024$); large hypodense areas were seen only in patients with poor collaterals. Eleven (34%) patients had large parenchymal hypodensities, and 15 (47%) pa-

tients had small hypodensities. No hypodensity was seen in 6 (19%) patients. The extent of parenchymal hypodensity correlated with clinical outcome ($P = .0045$); all 11 patients with large hypodensities died, whereas only 29% of patients with no or small hypodensity died. The positive predictive value of large hypodensity for death was 65% (11 of 17).

Recanalization

We observed complete recanalization in four patients within 8 hours of onset of symptoms (Table 2); the frequency of recanalization was the same (12.5%) in all treatment groups. Doppler examination after 24 hours documented no delayed recanalization and no reocclusion. Two patients with recanalization had good clinical outcomes (RS < 4), one patient had severe neurologic deficits (RS = 5), and one died. Recanalization was observed in two patients with cardiogenic emboli and in one patient with carotid artery dissection. In one patient, the cause of occlusion remained unclear.

In the recanalization group, three patients had poor and one had good collaterals. Two patients had small hypodensities, whereas one patient had no hypodensity and another had a large hypodensity on initial CT. The latter patient died; the patient with no hypodensity and one patient with small hypodensity had good clinical outcomes (RS < 4).

Hemorrhage

The second CT showed intracerebral hemorrhage in 10 patients (Table 2). These hemorrhages, all occurring on the side of the carotid occlusion, were classified as hemorrhagic infarct in 6 patients and as parenchymal hematoma in 4. In none of the patients did we see significant hemorrhage at the puncture site or elsewhere in the body, during or after thrombolysis. Intracranial hemorrhage was more frequent after intraarterial thrombolysis (9 patients) than after intravenous thrombolysis (1 patient) ($P = .0071$). We observed two hemorrhagic infarcts and two parenchymal hematomas with intraarterial urokinase, four hemorrhagic infarcts and one parenchymal hematoma with intraarterial alteplase, and one parenchymal hematoma with intravenous alteplase. As for parenchymal hematoma, there was no significant difference between the three treatment groups ($P > .5$). The time interval between symptom onset and onset of therapy was the same for patients without hemorrhage, patients with hemorrhagic infarct, and patients with parenchymal hematoma ($P > .3$). Likewise, the time between the onset of symptoms and the second CT did not differ between patients without hemorrhage (138 hours; SD, 77), patients with parenchymal hematoma (137.3 hours; SD, 57), and patients with hemorrhagic infarct (117 hours; SD, 63) ($P > .5$). In patients with hemorrhage, the second CT was obtained in 1 case within the first 48 hours of thrombolysis; in the other 9 patients, the second CT was obtained later (median, 140 hours; range, 32 to 190). In 20 patients with good collaterals we saw five hemorrhagic infarcts and three parenchymal hematomas, whereas in 12 patients with good collaterals we saw one hemorrhagic infarct and one parenchymal hematoma ($P > .3$). In 11 patients with large parenchymal hypodensity as shown by initial CT, we observed two hemorrhagic infarcts and three parenchymal hematomas, whereas in patients with small hypodensity, we saw three hemorrhagic infarcts and one parenchymal hematoma. Without hypodensity there was only one hemorrhagic infarct in 5 patients ($P > .4$). In the patient group without recanalization, 4 of 28 patients showed hemorrhagic infarcts and 4 parenchymal hematomas; with recanalization, 2 of 4 patients had hemorrhagic infarcts ($P > .2$). All 4 patients with parenchymal hematoma died; 3 of 6 patients with

hemorrhagic infarct died. Two had poor (RS = 5) and 1 had good (RS = 2) clinical outcome ($P > .3$).

Discussion

In acute embolic occlusion of the intracranial internal carotid artery bifurcation, thrombolysis with intravenous or intraarterial alteplase and intraarterial urokinase as used in this study appears to be largely ineffective. Rather than comparing the effects of these agents in a controlled randomized fashion, we observed them sequentially. We began by administering intravenous alteplase, having in mind that intravenous thrombolysis was potentially more useful in acute stroke than a treatment that required arterial catheterization. Thus, the results may have been biased while our experience with this new approach of stroke therapy increased. On the other hand, treatment groups did not differ with regard to their baseline characteristics.

Metaanalysis of controlled clinical trials has shown that early recanalization of the obstructed vessel is a promising way of actively treating acute ischemic stroke (19). The purpose of thrombolytic therapy in intracranial vascular occlusion is, however, to preserve threatened brain tissue, not to repair tissue that is already damaged. After sudden embolic occlusion of a major cerebral artery, cortical and subcortical structures can be prevented from becoming infarcted by rapid opening of leptomeningeal collaterals. Progressive brain swelling in the unreparably damaged area may cause secondary failure of these collaterals to function and thus may increase the size of the infarct. Because early recanalization may help to prevent enlargement of the infarct by compensating for the failure of collaterals to function properly, early signs of infarct in CT are not contraindications to thrombolytic therapy per se. Increased radiolucency of gray matter represents irreversibly damaged brain tissue which becomes detectable within the first 2 hours of onset of symptoms (17). If the volume of parenchymal hypodensity covers only a proportion of the tissue volume at risk, recanalizing therapy may be beneficial (20).

We explained the low recanalization rate after intravenous treatment by the inability of blood flow to transport adequate amounts of alteplase to the thrombus, and thus switched to intraar-

terial treatment. Angiography regularly showed that blood within the intracranial internal carotid artery was stagnant or near stagnant, because the major outflow vessels were obstructed. Neither alteplase nor urokinase directly applied to the proximal surface of the thrombus improved the recanalization rate. This observation is in keeping with the few existing accounts of thrombolytic therapy in intracranial internal carotid artery occlusion (12, 14, 21–26); by meta-analysis of the heterogeneous data from these reports, we calculated a mean recanalization rate of 11% (7 of 64 patients) in intracranial internal carotid artery occlusion. This rate of recanalization is considerably lower than that reported for middle cerebral artery occlusion (12, 14, 21–24, 26–28) or basilar artery occlusion (29). In these types of occlusion, the mean recanalization rates are 32% with intravenous alteplase and 63% with intraarterial urokinase or streptokinase, respectively (30). Because we did not study untreated control patients, we cannot state in our 4 patients in whom the vessel reopened, whether recanalization was spontaneous or caused by therapy. We are unaware, though, of any published report on spontaneous recanalization of the intracranial internal carotid artery (carotid T) occlusion, and we did not observe any delayed spontaneous recanalization in our patients.

We believe the low recanalization rate in carotid T occlusion to be explainable by the size and composition of the blood clot that obstructs the intracranial internal carotid artery lumen. A large organized and rigid clot likely occludes a large proximal vessel or the bifurcation itself. Without stenosis of the common or internal carotid artery, the carotid T is the first significant normal arterial narrowing of the anterior cerebral circulation, comparable to the bifurcation of the basilar artery, which also cannot be passed by large rigid emboli. Small emboli or large soft emboli capable of passing the narrow vascular segment by squeezing through or by fragmenting will result primarily in middle cerebral artery (and not intracranial internal carotid artery) occlusion. Although the neuroradiologist gains some information as to the rigidity of the thromboembolus by probing it with the guide wire or microcatheter, the exact size and composition of the lesion (whether organized, calcified, platelet-rich, or rich in fibrin) are presently

impossible to verify before therapy. Another reason why even intraarterial thrombolytic therapy fails in these patients might be that much of the agent simply flows away through the posterior communicating or ophthalmic arteries. Contrary to previous findings (31), recanalization was not associated with good collaterals in our study. When one considers the high mortality (53%) associated with the absence of recanalization, the two patients in our study who had a good outcomes after recanalization, as well as the total of three survivors in the recanalization group, suggest that recanalization of intracranial internal carotid artery occlusion might be clinically beneficial. However, the available numbers are too small to determine statistical significance.

Intracerebral hemorrhage after ischemic stroke is commonly observed if patients are studied with serial CT (32, 33). Following the example of others (18), we subdivided the bleeding as *hemorrhagic infarction* or *parenchymal hematoma*. Hemorrhagic infarct is petechiae or confluent hemorrhage in the area of ischemic injury; parenchymal hematoma is homogeneous bleeding with circumscribed clot formation and mass effect. In our patients, we observed a frequency of hemorrhage of 31.3%, including the four patients (12.5%) with parenchymal hematoma. These numbers are similar to those described for the natural course of hemorrhagic transformation of ischemic cerebral infarcts (32, 33). The frequency of hemorrhage was unrelated to presence or absence of recanalization, quality of leptomeningeal collateralization, interval between symptom onset and infusion of thrombolytic agent, and type of agent; the three treatment groups had similar frequencies of parenchymal hematoma. Hemorrhagic infarction, on the other hand, clearly occurred more often with intraarterial than with intravenous thrombolysis, suggesting that higher intraarterial concentrations of alteplase or urokinase might be responsible for an increased hemorrhagic infarct rate. Because recanalization and hemorrhage appeared to be unrelated, the concept of hemorrhagic transformation as a consequence of reperfusion injury is not supported by our observations. Parenchymal hemorrhage had a tendency to occur more often in patients with poor collaterals and consequently large infarctions; it invariably led to death caused by hemorrhage, extended ischemic edema, or both. In 9 of 10 patients with

hemorrhage, the second CT was obtained more than 48 hours after thrombolysis. Because of this delay, we could not exactly define the time point of cerebral hemorrhage and could not show whether or not the hemorrhage occurred immediately after thrombolysis. However, late CT scans give us the opportunity to differentiate between parenchymal hyperdensities caused by blood and those by contrast extravasation: contrast extravasation occurs in up to 60% of all patients with intraarterial thrombolysis but clears on CT within 24 hours, whereas hemorrhages persist for several days (34).

To avoid reocclusion or recurrent embolism, we treated all patients with full-dose heparin both during and after thrombolysis. In our experience, this therapeutic approach proved safe.

The majority of our patients had acute embolic intracranial internal carotid artery occlusion, giving collaterals no chance to develop, as often occurs in slowly progressive arterial stenosis; the entire cohort was free of asymptomatic cases. These factors explain the extremely poor prognosis, with mortality and severe morbidity combined amounting to 84%. Previous reports on the prognosis of intracranial internal carotid artery stenosis or occlusion (2-4) mainly dealt with atherosclerosis and stenosis of the infraclinoid carotid in older patients (mean age, 62 years versus 56 years in our study). These reports include asymptomatic patients and exclude patients who died from stroke (3) and thus are unsuited for comparison.

As noted by others (9, 10), prognosis after acute occlusion of the carotid T is closely linked with the state of collaterals, not with the success of thrombolysis in recanalizing the vessel. A patient's chance of surviving the occlusion was 20% if collaterals were of poor and 92% if they were of good function; of the five patients with favorable clinical outcomes, four were judged to have good leptomeningeal collaterals. The only patient with a good clinical outcome despite poor collaterals had successful intracranial internal carotid artery recanalization. Because all patients with good outcome showed only a small hypodensity or none at all on the first CT scan, CT appears to be the more sensitive indicator for good prognosis; however a "good" first CT scan was of low specificity for good clinical outcome. Sixteen patients with no or just small parenchymal hypointensity had poor or fatal outcomes. It remains unclear why most patients

with normal or near-normal initial CT scans and unsuccessful recanalization were in poor clinical condition on follow-up, and few patients showed good clinical outcome. We can only surmise that sufficient collateral circulation is the prerequisite for successful thrombolytic therapy with good clinical outcome. Insufficient collaterals or failure of collateral pathways to function before recanalization occurs seem to promote irreversible tissue damage; thrombolytic recanalization of the occluded artery then has no beneficial effect on the clinical course of the disease.

The mortality rate of 53%, caused mainly by transtentorial herniation attributable to extensive brain edema, shows the primary insufficiency or the secondary failure of collateral blood supply in carotid T occlusions. Three of four patients with successful recanalization survived, two of them with only minor neurologic deficit. Although these results are based on a small number of patients, it seems that reopening of the occluded carotid "T" might be effective if good collateral blood supply exists. Further experience must be gained, though, to improve the recanalization rate in carotid T occlusion; particular attention should be directed to the properties of blood clots in this location. We believe that recanalization itself is safe and not responsible for clinical deterioration caused by cerebral hemorrhage. With suitable devices, endovascular thrombectomy in carotid T occlusion may be feasible. Infusing thrombolytic material at both the proximal and distal end of the thrombus may be more efficacious for dissolving thrombus than infusing thrombolytic material proximal to the thrombus alone. However, in only 30% were we able to pass the microcatheter beyond the area of occlusion; thus this technique can be used only in the minority of patients. Novel thrombolytic agents also may improve recanalization rates; their efficacy should be investigated in further studies. In pilot studies, the addition of plasminogen during thrombolytic therapy with alteplase (plasminogen lysis) shortened recanalization times and improved recanalization rates (35).

Our study also underlines the great significance collateral blood flow has for clinical outcome. We suggest, however, that even in patients with initially good leptomeningeal collaterals, progressive brain swelling did occur, causing secondary failure of collateral blood supply followed by increased tissue necrosis.

Enhancing blood flow and oxygen transport through leptomeningeal collaterals are other approaches to improve clinical outcome in patients with carotid T occlusions.

In summary, sudden occlusion of the intracranial internal carotid artery bifurcation is a life-threatening cerebrovascular event that cannot be treated effectively with intravenous or intraarterial thrombolysis under the protocols used in this study. Although our approach appears to be safe in terms of not producing dangerous intracranial hemorrhage, the recanalization rates are unacceptably low. Improved results may be possible with novel thrombolytic agents (as in so-called plasminogen lysis) or with endovascular thrombectomy. A better control of brain swelling may improve clinical outcome in those patients who have good leptomeningeal collaterals. In patients without such collaterals, the outcome is poor, regardless of whether thrombolysis was effective.

References

1. Yamaguchi T, Minematsu K, Choki J-I, Ikeda. Clinical and neuro-radiological analysis of thrombotic and embolic cerebral infarction. *Jpn Circ J* 1984;48:50-58
2. Marzewski DJ, Furlan AJ, Louis PS, Little JR, Modic MT, Williams G. Intracranial internal carotid artery stenosis: longterm prognosis. *Stroke* 1982;13:821-824
3. Craig DR, Meguro K, Watridge C, Robertson JT, Barnett HJM, Fox AJ. Intracranial internal carotid artery stenosis. *Stroke* 1982;13:825-828
4. Bogousslavsky J, Regli F. Prognosis of symptomatic intracranial obstruction of internal carotid artery. *Eur Neurol* 1983;22:351-358
5. Kaste M, Waltimo O. Prognosis of patients with middle cerebral artery occlusion. *Stroke* 1976;7:482-485
6. Moulin DE, Lo R, Chiang J, Barnett HJM. Prognosis in middle cerebral artery occlusion. *Stroke* 1985;16:282-284
7. Saito I, Segawa H, Shiokawa Y, Taniguchi M, Tsutsumi K. Middle cerebral artery occlusion: correlation of computed tomography with clinical outcome. *Stroke* 1987;18:863-868
8. del Zoppo GJ, Pessin MS, Mori E, Hacke W. Thrombolytic intervention in acute thrombotic and embolic stroke. *Semin Neurol* 1991;11:368-384
9. Bozzao L, Fantozzi LM, Bastianello S, Bozzao A, Fieschi C. Early collateral blood supply and late parenchymal brain damage in patients with middle cerebral artery occlusion. *Stroke* 1989;20:735-740
10. von Kummer R, Forsting M. Effects of recanalization and collateral blood supply on infarct extent and brain edema after middle cerebral artery occlusion. *Cerebrovasc Dis* 1993;3:252-255
11. von Kummer R, Hacke W. Safety and efficacy of intravenous tissue plasminogen activator and heparin in acute middle cerebral artery stroke. *Stroke* 1992;23:646-652
12. Mori E, Tabuchi M, Yoshida T, Yamadori A. Intracarotid urokinase with thromboembolic occlusion of the middle cerebral artery. *Stroke* 1988;19:802-812
13. Mori E, Yoneda Y, Tabuchi M, et al. Double-blind, placebo-controlled trial of recombinant tissue plasminogen activator (rt-PA) in acute carotid stroke. *Neurology* 1992;42:976-982
14. Yamaguchi T, Japanese Thrombolysis Study Group. Intravenous tissue plasminogen activator in acute thromboembolic stroke: a placebo-controlled, double blind trial. In: del Zoppo GJ, Mori E, Hacke W, eds. *Thrombolytic Therapy in Acute Ischemic Stroke*. Heidelberg, Germany: Springer; 1993;11:59-65
15. Scandinavian Stroke Study Group. Multicenter trial of hemodilution in ischemic stroke: background and study protocol. *Stroke* 1985;16:885-890
16. van Swieten JC, Koudstaal PJ, Visser MC, Schouten HJA, van Gijl J. Interobserver agreement for the assessment of handicap in stroke patients. *Stroke* 1988;19:604-607
17. von Kummer R, Meyding-Lamadé U, Forsting M, et al. Sensitivity and prognostic value of early CT in occlusion of the middle cerebral artery trunk. *AJNR Am J Neuroradiol* 1994;15:9-15
18. Pessin MS, delZoppo GJ, Estol C. Thrombolytic agents in the treatment of stroke. *Clin Neuropharmacol* 1990;13:271-289
19. Wardlaw JM, Warlow CP. Thrombolysis in acute ischemic stroke: does it work? *Stroke* 1992;23:1826-1839
20. von Kummer R, Holle R, Rosin L, Forsting M, Hacke W. Does arterial recanalization improve outcome in carotid territory stroke? *Stroke* 1995;26:581-587
21. Theron J, Courtheoux P, Casaco A, et al. Local intraarterial fibrinolysis in the carotid territory. *AJNR Am J Neuroradiol* 1989;10:753-765
22. Matsumoto K, Satoh K. Topical intraarterial urokinase infusion for acute stroke. In: Hacke W, del Zoppo GJ, Hirschberg M, eds. *Thrombolytic Therapy in Acute Ischemic Stroke*. Heidelberg, Germany: Springer; 1991:207-212
23. Siepmann G, Müller-Jensen M, Goossens-Merkel H, Lachenmayer L, Zeumer H. Local intraarterial fibrinolysis in acute middle cerebral artery occlusion. In: Hacke W, del Zoppo GJ, Hirschberg M, eds. *Thrombolytic Therapy in Acute Ischemic Stroke*. Heidelberg, Germany: Springer; 1991:68-71
24. Zeumer H, Freitag H-J, Zanella A, Arning C. Local intra-arterial fibrinolytic therapy in patients with stroke: urokinase versus recombinant tissue plasminogen activator (rt-PA). *Neuroradiology* 1993;35:159-162
25. Wolpert SW, Brückmann H, Greenlee R, et al. Neuroradiologic evaluation of patients with acute stroke treated with recombinant tissue plasminogen activator. *AJNR Am J Neuroradiol* 1993;14:3-13
26. del Zoppo G, Poeck K, Pessin MS, Acute Stroke Study Group. Recombinant tissue plasminogen activator in acute thrombotic and embolic stroke. *Ann Neurol* 1992;32:78-86
27. Yamaguchi T, Hayakawa T, Kikichi H, Abe T. Thrombolytic therapy in embolic and thrombotic cerebral infarction: a cooperative study. In: Hacke W, del Zoppo GJ, Hirschberg M, eds. *Thrombolytic Therapy in Acute Ischemic Stroke*. Heidelberg, Germany: Springer; 1991:168-174
28. del Zoppo GJ, Ferbert A, Otis S, et al. Local intra-arterial fibrinolytic therapy in acute carotid territory stroke. *Stroke* 1988;19:307-313
29. Hacke W, Zeumer H, Ferbert A, Brückmann H, del Zoppo G. Intraarterial fibrinolytic therapy improves outcome in patients with acute vertebrobasilar occlusive disease. *Stroke* 1988;19:1216-1222
30. von Kummer R, Forsting M, Wildemann B, Sartor K. Thrombolyse bei akuter zerebraler Ischämie. *Aktuelle Radiol* 1993;3:351-355

31. Ringelstein EB, Biniek R, Weiler B, Ammeling PN, Nolte N, Thron A. Type and extent of hemispheric brain infarctions and clinical outcome in early and delayed middle cerebral artery recanalization. *Neurology* 1992;42:289-298
32. Okada Y, Yamaguchi T, Minematsu K. Hemorrhagic transformation in cerebral embolism. *Stroke* 1989;20:598-603
33. Hornig CR, Dorndorf W, Agnoli AL. Hemorrhagic transformation in cerebral embolism. *Stroke* 1986;17:179-185
34. Wildenhain SL, Jungreis CA, Barr J, Mathis J, Wechsler L, Horton JA. CT after intracranial intraarterial thrombolysis for acute stroke. *AJNR Am J Neuroradiol* 1994;15:487-492
35. Freitag H-J, Becker V, Thie A, et al. Lys-Plasminogen as a support to local intraarterial fibrinolysis for carotid territory stroke. *Neuroradiology* (in press)

Please see the commentary on page 1994 in this issue.
--