



Get Clarity On Generics

Cost-Effective CT & MRI Contrast Agents

**FRESENIUS
KABI**

WATCH VIDEO

AJNR

**Posttreatment MR findings in spinal dural
arteriovenous malformations.**

R A Willinsky, K terBrugge, W Montanera, D Mikulis and M C
Wallace

AJNR Am J Neuroradiol 1995, 16 (10) 2063-2071

<http://www.ajnr.org/content/16/10/2063>

This information is current as
of August 7, 2025.

Posttreatment MR Findings in Spinal Dural Arteriovenous Malformations

Robert A. Willinsky, Karel terBrugge, Walter Montanera, David Mikulis, and M. Christopher Wallace

PURPOSE: To review the MR findings in 17 patients with spinal dural arteriovenous malformations and compare posttreatment MR with clinical outcome in 10 patients. **METHODS:** Extramedullary flow voids, cord swelling, and intramedullary signal changes were recorded in 17 patients. Enhancement and vessel conspicuity were assessed in 10 patients given gadopentetate dimeglumine. In 10 patients, follow-up MR was correlated with clinical outcome. **RESULTS:** Of the 17 patients, 14 (82%) had abnormal subarachnoid vessels, 11 (65%) had cord enlargement, and 16 (94%) had hyperintensity on T2-weighted images. In 3 patients, the vessels were better seen with contrast, and 6 had cord enhancement. On posttreatment MR, the vessels were no longer evident in 7 of 10 patients, cord swelling resolved in 9 of 9 patients, and the T2 hyperintensity resolved or was less evident in 9 of 9 patients. Eight patients had clinical improvement, and 2 stabilized. **CONCLUSIONS:** Follow-up MR showed resolution of most of the findings in spinal dural arteriovenous malformation. There was some correlation between MR and clinical outcome, but MR evaluation could not distinguish those who had improved from those who stabilized.

Index terms: Arteriovenous malformations, spinal; Spine, magnetic resonance

AJNR Am J Neuroradiol 16:2063–2071, November 1995

The diagnosis of spinal dural arteriovenous malformation (AVMs) remains elusive and characteristically defies an early recognition. Berenstein and Lasjaunias combined their series with the reports by Djindjian, Merland, Rosenblum, and Symon to summarize the common clinical presentations and findings (1–5). Patients usually present in the 4th to 6th decade with a slowly progressive thoracic myelopathy. Leg weakness, back pain, and/or radicular pain are the most common presenting problems. Stocking and/or saddle paraesthesias often develop in association with bladder, bowel, and sexual-function disturbances. Upper and lower motor neuron findings in the lower limbs suggest a low cord or conus lesion. Power usually is

grade 4. Deep tendon reflexes may be increased despite wasting of the buttocks and lower extremities. Clonus often is present. Loss of pain and temperature sensation as well as joint-position sense is frequent.

The pathophysiology of spinal dural AVMs was elucidated by Aminoff and supported by the work of Kendall and Merland (3, 6, 7). Shunting into the perimedullary venous plexus results in a venous hypertension and chronic passive venous congestion of the cord. The patient's signs and symptoms relate to dysfunction in the lower thoracic cord and conus, irrespective of the location of the shunt. Intracranial dural AVMs draining into the perimedullary venous plexus of the cord can produce a similar myelopathy (8–10).

Magnetic resonance (MR) of the spinal cord now should be the first radiologic investigation of a myelopathy. Previous reports have shown the following MR findings in spinal dural AVMs: hyperintensity in the thoracic cord on T2-weighted images, dilated perimedullary vessels, thoracolumbar cord swelling, "blurred" cord margins, and gadolinium enhancement of the thoracic cord and/or perimedullary vessels (11–

Received March 7, 1995; accepted after revision August 7.

From the Departments of Radiology (R.W., K.T., W.M., D.M.) and Surgery (M.C.W.) and the Vascular Malformation Study Group (R.W., K.T., M.C.W.), the Toronto Hospital, University of Toronto, Ontario, Canada.

Address reprint requests to Robert A. Willinsky, MD, Department of Radiology, The Toronto Hospital, Western Division, 399 Bathurst St, Toronto, Ontario, Canada, M5T 2S8.

AJNR 16:2063–2071, Nov 1995 0195-6108/95/1610-2063

© American Society of Neuroradiology

TABLE 1: MR findings in 17 patients with dural AVMs

Case	Sex/Age, y	Unenhanced MR			MR with Gadopentetate Dimeglumine		Level of Dural AVM
		Vessels	Cord Swelling	T2 Hyperintensity	Vessels	Enhancement	
1	F/28	*	No	T-4 to conus	L L-2
2	F/68	No	No	†to conus	No	Diffuse	L T-7
3	M/63	Yes	Conus	T-8 to conus	Same	Patchy	L L-2
4	M/64	Yes	No	T-4 to conus	R T-6
5	M/66	Yes	T-6 to conus	T-6 to conus	R T-7
6	M/64	Yes	Conus	T-5 to conus	Improved	No	R T-6
7	F/62	Yes	Conus	T-5 to conus	L L-2
8	M/46	Yes	Conus	T-5 to conus	Same	No	L T-7
9	M/55	Yes	T-7 to conus	T-7 to conus	Same	No	L T-2
10	M/47	Yes	Conus	Conus	Same	Patchy	L T-3
11	M/59	Yes	Conus	T-5 to conus	No	Diffuse	L T-6
12	M/74	Yes	Conus	T-7 to conus	Same	No	R L-2
13	M/70	Yes	No	No	Improved	Patchy	R T-7
14	M/68	*	No	T-7 to conus	L L-4
15	M/71	Yes	Conus	T-7 to conus	Improved	Patchy	L T-5
16	M/76	Yes	Conus	T-6 to conus	R T-7
17	M/39	Yes	No	T-7 to conus	L T-4

* "Hazy" margin of cord or suspicious for flow voids.

† Upper level not imaged.

18). In this report, we reviewed the MR findings in 17 patients with angiographically proved spinal dural AVMs. In 10 patients, posttreatment MR was evaluated to see which findings were reversible. Clinical follow-up was correlated to pretreatment and posttreatment MR to see whether MR may be useful as a prognostic indicator.

Materials and Methods

A retrospective review of the MR images of 17 patients with angiographically proved spinal dural AVMs was done. The patients were assessed and/or treated at our institution between 1990 and 1994. In 10 patients, the pretreatment and posttreatment MR was compared, and these findings were correlated with the clinical results. The following features were assessed on MR: dilated extramedullary flow-voids, "hazy" cord margins, cord enlargement, and intramedullary signal changes. We noted the levels of cord swelling and signal changes. On the postgadolinium studies, we assessed whether too many tortuous, dilated subarachnoid vessels were evident, and noted the presence of cord enhancement. We compared precontrast to postcontrast exams to evaluate the role of contrast in the detection of abnormal vessels. Cord enhancement was noted to be either diffuse or patchy.

The MR studies were done at different institutions on 1.5-T magnets. The imaging parameters varied from one institution to another and at our own hospital over the

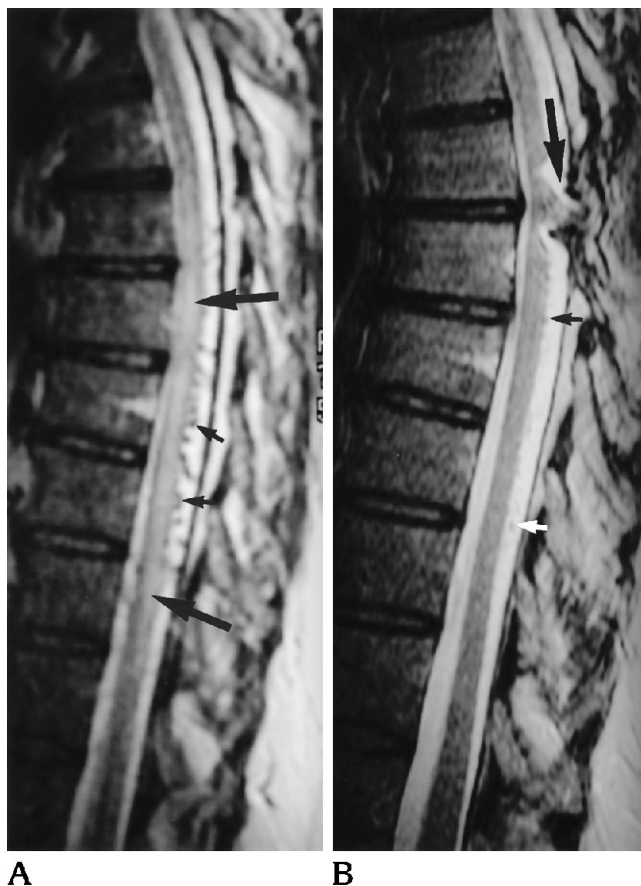4-year period. The thoracic cord was studied in all patients with varying fields of view. All patients had sagittal, conventional, spin-echo T1-weighted images, and sagittal, conventional or fast spin-echo, proton-density, and T2-weighted images. All patients had axial, T1-weighted or T2-weighted images. Gadopentetate dimeglumine (Magnevist, Berlex, Wayne, NJ) was given to 10 patients at a dose of 0.1 mmol/kg.

Eleven patients were treated with surgery and 5 with embolization with liquid adhesives; 1 patient refused surgery after a failed embolization. Follow-up MR was done in 10 of the treated patients. These studies were done from 1 to 54 months after treatment, with an average time interval of 23 months. Seven patients had 1 follow-up MR, 2 patients had 2 follow-up MRs, and 1 had 3 follow-up MRs. Clinical follow-up included assessment of back pain, motor function, sensory signs or symptoms, and bladder and bowel function.

Results

All patients presented with a progressive, thoracic myelopathy. Time interval before diagnosis varied from 1 to 36 months, with a mean of 12 months. There were 14 men and 3 women. Age varied from 28 to 77 years, with a mean age of 60 years.

Eleven patients had myelography before the MR, and in 9 suspicious vessels were evident. The thoracic cord was not examined in 1 of the



A Fig 1. Case 8. *A*, T2-weighted sagittal thoracic MR shows perimedullary flow voids on the dorsal aspect of the cord (*short arrows*) and a diffuse intramedullary hyperintensity (*long arrows*) that extended to the conus.

B, Posttreatment (17 months) T2-weighted MR shows resolution of the hyperintensity and only subtle flow voids on the dorsal aspect of the cord (*short arrows*). Artifact from metallic clips is seen in the high thoracic region (*arrow*).

2 false-negative myelograms. The MR and angiographic findings are outlined in Table 1. On MR, 14 (82%) patients had a plethora of extramedullary flow voids, 11 (65%) had cord enlargement, and 16 (94%) had a diffuse, intramedullary hyperintensity on T2-weighted images. The extramedullary flow voids were seen predominantly dorsal to the cord throughout the thoracic region (Figs 1 and 2). These flow voids were recognized on the proton-density and T2-weighted images. The T1-weighted images often revealed only irregular or "hazy" cord margins. Prominent flow voids were not seen in the cervical region in this series. The cord enlargement and/or hyperintensity on T2-weighted images involved the conus with a variable cephalad extension. The hyperintensity ex-

tended up to the upper thoracic level in 13 of the 16 patients (Figs 1, 3, 4). On axial MR, the hyperintensity involved the central cord, both gray and white matter, with a surrounding rim of cord that was spared (Fig 4). The hyperintensity did not extend above T-4 level in any of our patients. In 4 patients, a subtle hypointensity on T1-weighted images was evident at the conus or in the thoracic cord (Fig 3). In 8 patients, the cord enlargement was limited to the conus (Fig 2). Gadolinium enhancement improved the conspicuity of the dilated subarachnoid vessels in 3 patients, compared with the proton-density and T2-weighted images. Gadolinium enhancement did not reveal the presence of abnormal vessels that were not evident on the noncontrast images. Enhancement of the conus or thoracic cord could be described as patchy in 4 of the 10 patients and diffuse in 2 (Fig 2).

Table 2 outlines the findings on follow-up MR in 10 of the treated patients. On the final MR, the prominent subarachnoid vessels were less evident in 3 of the 10 patients (Fig 1) and not evident in 7 (Fig 2). On the final MR, cord swelling resolved in 9 of 9 patients (Figs 1, 2), and cord atrophy developed in 2 of the 9 patients (Fig 3). On the final MR, the hyperintensity on T2-weighted images was no longer evident in 6 of 9 patients (Figs 1 and 2). In 3 patients, the hyperintensity was less evident (Fig 4). The hyperintensity persisted in 1 patient on the 9-month follow-up MR but was less evident at 34 months (Fig 3). This patient's 9-month follow-up MR was our only follow-up study with gadolinium, and a patchy cord enhancement was evident at that time. One of the 9 patients had a small area of hypointensity on T2-weighted images with less hyperintensity.

Table 3 outlines the clinical outcome after treatment in the 10 patients who had follow-up MR. Overall, 8 of the 10 patients had clinical improvement. Two patients had no clinical improvement but remained neurologically stable. Back pain resolved in all 9 patients. Motor function returned to normal in 1 of the 10 patients, improved in 7, and was stable in 2. Sensory signs or symptoms resolved in 3 of the 10 patients, improved in 5, and was stable in 2. Bladder and bowel dysfunction resolved in 2 of 9 patients, improved in 5, and was stable in 2. All treated patients had follow-up angiography confirming that the arteriovenous shunt was closed.

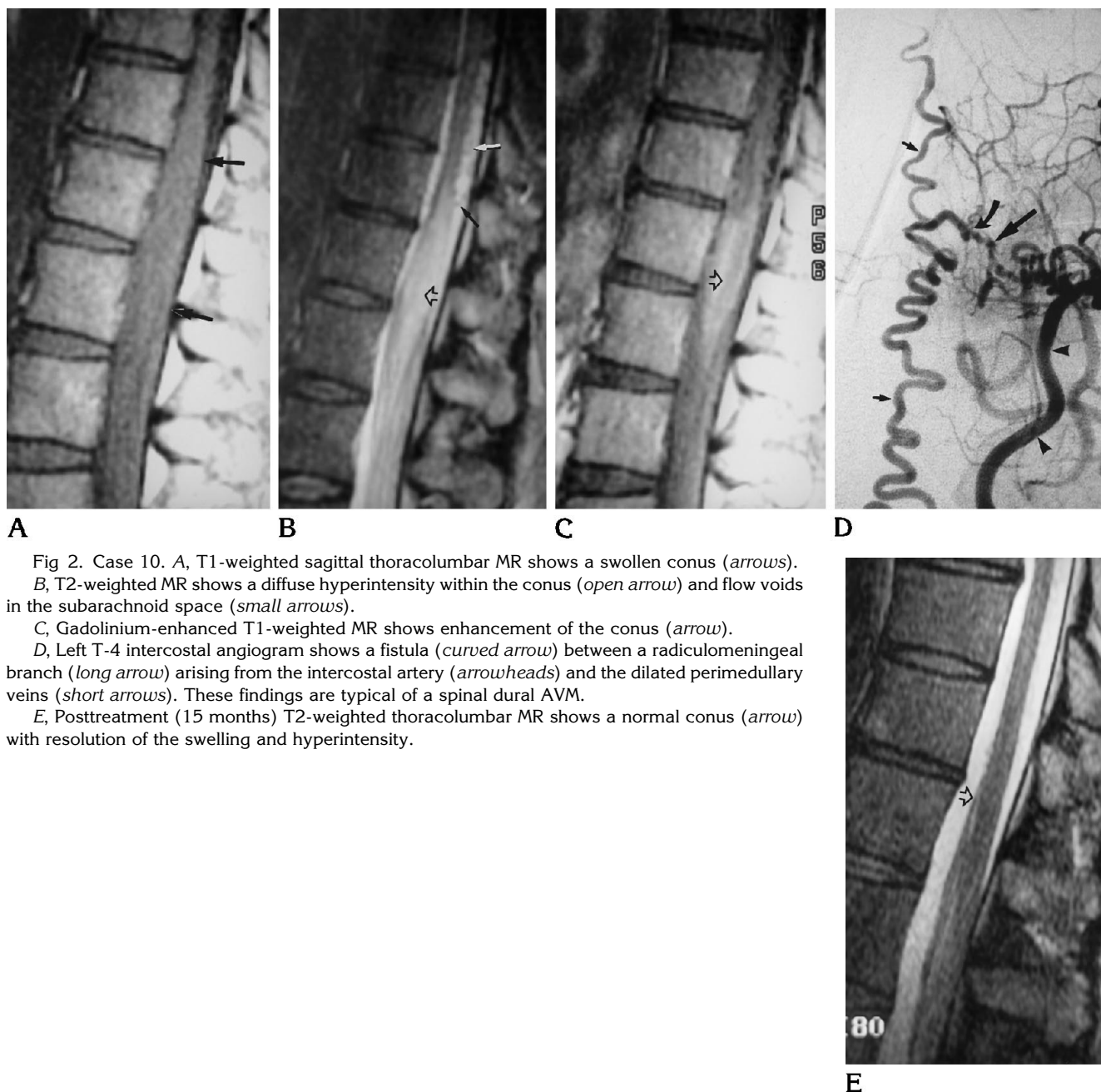


Fig 2. Case 10. A, T1-weighted sagittal thoracolumbar MR shows a swollen conus (arrows). B, T2-weighted MR shows a diffuse hyperintensity within the conus (open arrow) and flow voids in the subarachnoid space (small arrows). C, Gadolinium-enhanced T1-weighted MR shows enhancement of the conus (arrow). D, Left T-4 intercostal angiogram shows a fistula (curved arrow) between a radiculomeningeal branch (long arrow) arising from the intercostal artery (arrowheads) and the dilated perimedullary veins (short arrows). These findings are typical of a spinal dural AVM. E, Posttreatment (15 months) T2-weighted thoracolumbar MR shows a normal conus (arrow) with resolution of the swelling and hyperintensity.

Discussion

Vascular malformations of the spine can be grouped into arteriovenous and venous. The AVMs can be classified according to their arterial supply. Spinal dural AVMs are fed by radiculomeningeal arteries and drain into the perimedullary venous plexus (Fig 2). Spinal cord AVMs are fed by anterior spinal (radiculomedullary) and/or posterior spinal (radiculopial) arteries and drain into the intrinsic medullary and/or extrinsic perimedullary venous system

(1). These cord AVMs may have a nidus or may consist only of a fistula. The nidus usually is intramedullary. The intramedullary AVMs often present in the second or third decades with a sudden onset of a neurologic deficit often attributable to a bleed. The fistulas are often perimedullary or subpial. Epidural arteriovenous fistulas are fed by segmental arteries and drain into epidural and/or paraspinal veins (19). With recent advances in MR, venous malformations or cavernomas can be detected (20).

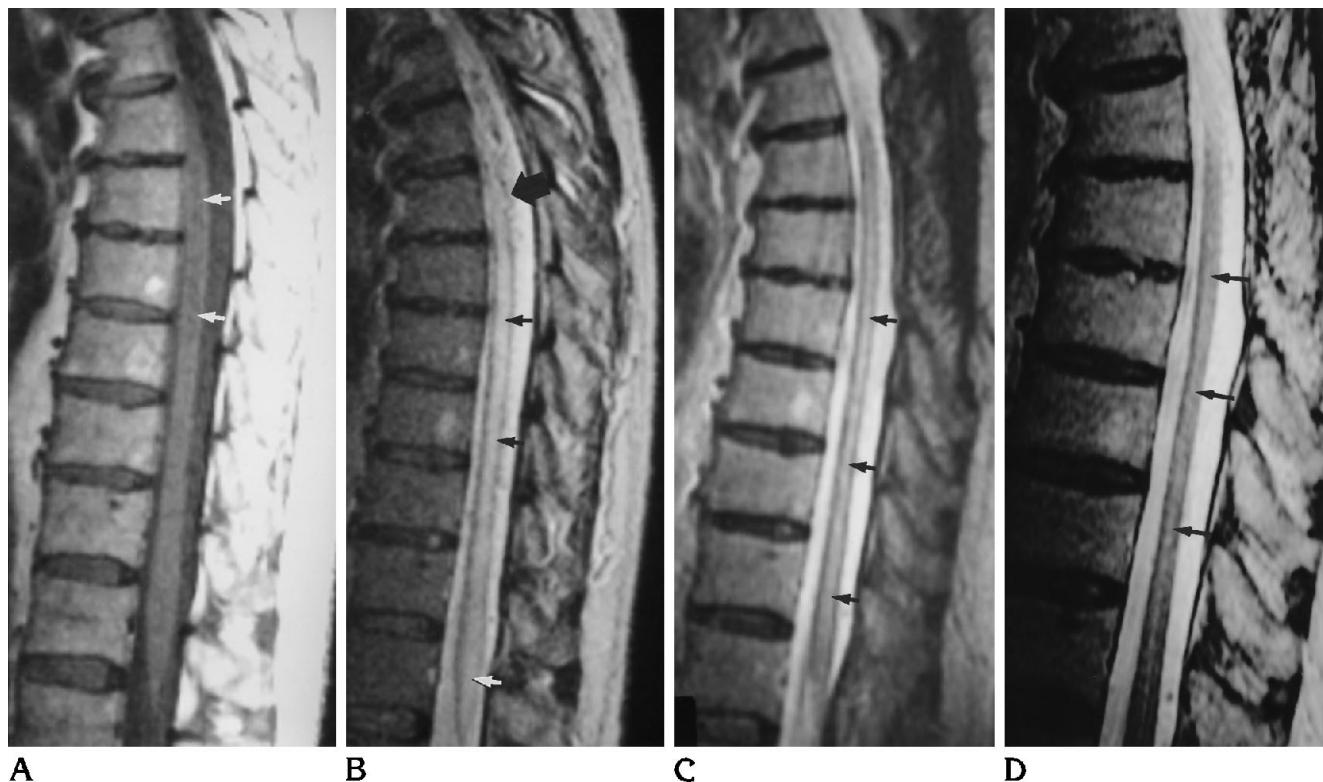

Fig 3. Case 4. A, T1-weighted sagittal thoracolumbar MR shows a subtle hypointensity within the midthoracic cord (*arrows*). B, T2-weighted MR show a dilated flow void (*thick arrow*), indistinct cord margins, and a diffuse hyperintensity within the cord extending up from the conus (*small arrows*). C, Posttreatment (9 months) T2-weighted MR shows that the cord is smaller with more distinct margins. However, the hyperintensity persists (*arrows*). D, At 34 months after treatment, T2-weighted MR shows less intramedullary hyperintensity (*arrows*).

In this review of 17 patients with proved spinal dural AVMs, all had abnormalities on MR. A diffuse hyperintensity on T2-weighted images was seen in the cord in 16 of 17 patients, extending from the conus cephalad to a variable degree. On axial images, the hyperintensity was central involving gray and white matter. This would account for the upper and lower motor neuron findings. The involvement of the conus accounts for the bladder, bowel, and sexual dysfunction. A corresponding subtle hypointensity on T1-weighted images was seen in a few patients. These signal changes are likely the result of chronic ischemia attributable to venous congestion. We found a variable degree of cord enlargement, which likely relates to the amount of edema. In 14 (82%) patients, prominent extramedullary vessels were evident and best seen on proton-density or T2-weighted images or gadolinium-enhanced images (3 of 10 patients). Two patients had "hazy" cord margins that were suspicious for dilated perimedullary vessels.

Myelopathic patients with prominent perimedullary vessels on MR should undergo spinal angiography. In one of our patients, we found a diffuse spinal cord hyperintensity on T2-weighted images with no suggestion of abnormal extramedullary vessels. In these patients, the pattern of hyperintensity on T2-weighted images and the clinical findings must be considered together in determining patient treatment. If the myelopathy is slowly progressive and the hyperintensity is diffuse, extending cephalad from the conus, we would recommend spinal angiography to search for a dural AVM. If the myelopathy is acute and the hyperintensity on T2-weighted images does not involve the conus, then an acute transverse myelopathy is most likely, and a repeat MR, in a few weeks, often will show some resolution (21). Recently, we have found that we have not needed myelography in the work-up for a myelopathy.

Intramedullary spinal cord tumors must be considered in patients with a slowly progressive

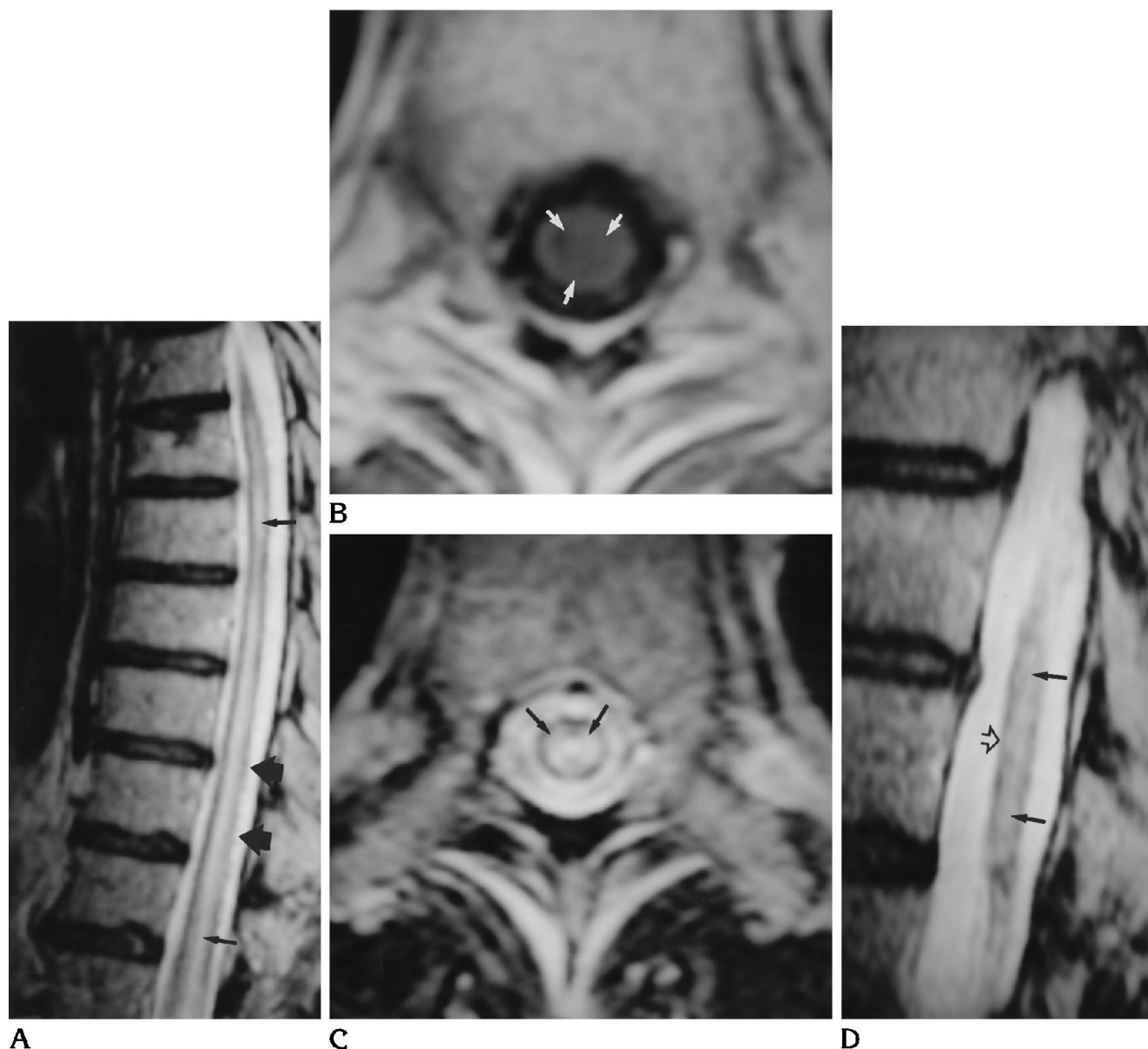


Fig 4. Case 6. A, T2-weighted sagittal thoracic MR shows subtle vessels on the dorsal aspect of the cord (*thick arrows*) and a diffuse intramedullary hyperintensity extending from the conus (*thin arrows*).

B, T1-weighted axial MR shows a central round area of hypointensity within the lower thoracic cord (*arrows*).

C, T2-weighted axial MR shows a corresponding central round area of hyperintensity in the lower thoracic cord (*arrows*). Both white and gray matter are involved.

D, Posttreatment (11 months) T2-weighted sagittal MR shows that the cord, just cephalad to the conus, is smaller (*open arrowhead*), and the hyperintensity (*arrows*) has decreased.

myelopathy. Apart from a small hemangioblastoma, intramedullary tumors usually expand the cord. In distinction from spinal dural AVMs, most tumors have heterogeneous signal changes on both T1-weighted and T2-weighted images (11). Regions of low intensity on T1-weighted images often are seen, and in the series by Dillon et al, five of the six astrocytomas

enhanced inhomogeneously (11). In the same series, four of the five ependymomas had an enhancing mass with well-defined margins. The diffuse, homogeneous hyperintensity on T2-weighted images differentiates dural AVMs from most spinal cord tumors. The patchy or diffuse enhancement pattern of dural AVMs can be similar to astrocytomas. In the presence of cord

TABLE 2: MR findings before and after treatment

Case	MR after Treatment, mo	Prominent Vessels		Cord Swelling		T2 Hyperintensity		Clinical Findings*	
		before	after	before	after	before	after	before	after
4	9	++	No	++	No	++	++	++	+
	34		No		Small		No		+
5	16	++	No	++	No	++	+	++	+
6	11	++	No	++	Small	++	+	++	+
7	34	++	No	++	No	++	No	++	+
8	5	++	+	++	No	++	No	++	+
	17		+		No		No		+
10	4	++	No	++	No	++	No	++	+
11	19	++	No	++	No	++	Hem	++	Normal
13	19	++	+	No	No	Hem	Hem	++	++
16	25	++	+	++	No	++	No	++	++
17	1	++	+	++	No	++	No	++	+
	8		+		No		No		+
	54		No		No		No		+

Note.—Hem indicates T2 hypointensity (hemosiderin); ++, present; and +, present but less evident on MR, or clinically improved.

* Overall assessment; see Table 3 for specific findings.

TABLE 3: Clinical follow-up before treatment and after (at time of last MR)

Case	Back Pain		Motor Deficit		Sensory Signs or Symptoms		Bladder/Bowel Dysfunction	
	before	after	before	after	before	after	before	after
4	++	—	++	+	++	—	++	—
5	++	—	++	+	++	—	++	+
6	++	—	++	+	++	+	++	++
7	++	—	++	+	++	+	++	+
8	++	—	++	+	++	+	++	+
10	++	—	++	+	++	+	++	+
11	++	—	++	—	++	+	++	—
13	—	—	++	++	++	++	—	—
16	++	—	++	++	++	++	++	++
17	++	—	++	+	++	—	++	+

Note.—++ indicates present; + present but clinically improved; and —, absent.

expansion, with intrinsic signal changes, gadolinium administration is useful, because a discrete mass may be found indicating a tumor, or prominent vessels may become evident, suggesting a dural AVM.

The presence of prominent extramedullary vessels, cord enlargement, and a diffuse hyperintensity on T2-weighted images extending from the conus is not pathognomonic of a spinal dural AVM. We have seen perimedullary spinal AVMs produce the same findings, and multiple spinal cord hemangioblastomas can result in extensive arteriovenous shunting resulting in a similar picture. Intracranial dural AVMs can shunt into the perimedullary venous plexus, resulting in a thoracic, congestive myelopathy (8–10).

The presence of cord enhancement in spinal dural AVMs likely represents a breakdown in the blood-cord barrier caused by the venous hypertension, or may be attributable to the venous congestion only. Parenchymal enhancement and hyperintensity on T2-weighted images have been shown in the brain in patients with intracranial dural AVMs with cortical venous reflux, producing a venous congestive encephalopathy (22). Larsson et al believe that the persistence of cord enhancement after treatment of a spinal dural AVM carries a bad prognosis (14). In our follow-up of 10 patients, 1 patient (case 4) had a patchy cord enhancement at 9 months after treatment. Like Larsson's patient, he had an initial clinical improvement after treatment, but was left with a significant disability.

Overall clinical improvement after treatment occurred in 8 of the 10 patients who had follow-up MR. Most of the MR findings were resolved on follow-up MR in this group. In the 2 patients who did not clinically improve, there was no clear indication on follow-up MR that these patients were different from the 8 who had clinical improvement. In 1 of these 2 patients, the cord swelling and hyperintensity on T2-weighted images were resolved on follow-up MR. In the other patient, MR showed hypointensity, likely hemosiderin, on the T2-weighted images on pretreatment and posttreatment MR, but a similar hypointensity was seen on follow-up in a patient who did improve clinically.

Treatment of a spinal dural AVM will result in the complete or partial resolution of the MR findings. This gives supportive evidence that the fistula is closed, but should not preclude follow-up angiography. We recommend a follow-up angiogram to be done approximately 2 to 3 months after surgical or endovascular treatment. This often is the time when clinical improvement begins to plateau. Earlier angiography is required if there is any suggestion that the fistula is not closed.

Despite the location of the spinal dural fistula, cord swelling and hyperintensity on T2-weighted MR always involved the conus extending cephalad. The prominent perimedullary vessels were always found in the thoracic level. Therefore, MR, in the investigation of a possible spinal dural AVM, should focus on the thoracic cord and include the conus.

The MR findings of dilated subarachnoid vessels and a diffuse hyperintensity on T2-weighted images are strongly suggestive of a spinal dural AVM. However, these findings do not help locate the site of the shunt. Provenzale et al used three-dimensional phase-contrast MR angiography to demonstrate the location of a spinal dural AVM after conventional angiography (23). Thorpe et al had some success in locating angiographically proved spinal dural AVMs in four patients, using dynamic gadolinium-enhanced MR (24). Location of dural AVMs with dynamic MR or MR angiography will greatly facilitate spinal angiography. The emphasis during angiography then can be directed to defining the angioarchitecture of the malformation and to endovascular treatment (25). With further improvements in either dynamic

gadolinium-enhanced MR or MR angiography, follow-up angiography may not be necessary.

References

1. Berenstein A, Lasjaunias P. *Surgical Neuroangiography, Vol 5: Endovascular Treatment of Spine and Spinal Cord Lesions*. Heidelberg, Germany: Springer-Verlag; 1993:1-85
2. Djindjian R, Hurth M, Houdart R. *L'angiographie de la moelle epiniere*. Paris, France: Masson; 1970:122-296
3. Merland JJ, Riche MC, Chiras J. Intraspinal extramedullary arteriovenous fistulae draining into the medullary veins. *J Neuroradiol* 1980;7:271-320
4. Rosenblum B, Oldfield EH, Doppman JL, Di Chiro G. Spinal (AVM)s: a comparison of dural arteriovenous fistulas and intradural AVM's in 81 patients. *J Neurosurg* 1987;67:795-802
5. Symon L, Kuyama H, Kendall B. Dural (AVM) of the spine: clinical features and surgical results in 55 cases. *J Neurosurg* 1984;60:238-247
6. Aminoff MJ, Barnard RO, Logue V. The pathophysiology of spinal vascular malformations. *J Neurol Sci* 1974;23:255-263
7. Kendall BE, Logue L. Spinal epidural angiomatous malformation draining into thecal veins. *Neuroradiology* 1977;13:181-189
8. Gobin YP, Rogopoulos A, Aymand A, et al. Endovascular treatment of intracranial arteriovenous fistulas with spinal perimedullary venous drainage. *J Neurosurg* 1992;77:718-723
9. Wrobel CJ, Oldfield EH, Di Chiro G, Tarlov EC, Baker RA, Doppman JL. Myelopathy due to intracranial dural arteriovenous fistulas draining intrathecally into spinal medullary veins. Report of three cases. *J Neurosurg* 1988;69:934-939
10. Willinsky R, TerBrugge K, Lasjaunias P, Montaner W. The variable presentations of craniocervical and cervical dural (AVM). *Surg Neurol* 1990;34:118-123
11. Dillon WP, Norman D, Newton TH, Bolla K, Mark A. Intradural spinal cord lesions: Gd-DTPA-enhanced MR imaging. *Radiology* 1989;170:229-237
12. Doppman JL, Di Chiro G, Dwyer A, Frank J, Oldfield E. Magnetic resonance imaging of spinal (AVM). *J Neurosurg* 1987;66:830-834
13. Dormont D, Gelbert F, Assouline E, et al. MR imaging of spinal cord (AVM) at 0.5 T: study of 34 cases. *AJNR Am J Neuroradiol* 1988;9:833-838
14. Larsson E-M, Desai P, Hardin C, Story J, Jinkins JR. Venous infarction of the spinal cord resulting from dural arteriovenous fistula: MR imaging findings. *AJNR Am J Neuroradiol* 1991;12:739-743
15. Isu T, Iwaasaki Y, Akino M, Koyanagi I, Abe H. Magnetic resonance imaging in cases of spinal dural arteriovenous malformation. *Neurosurgery* 1989;24:919-923
16. Masaryk TJ, Ross JS, Modic MT, Ruff R, Selman W, Ratcheson R. Radiculomeningeal vascular malformations of the spine: MR imaging. *Radiology* 1987;164:845-849
17. Minami S, Sagoh T, Nishimura K, et al. Spinal arteriovenous malformation: MR imaging. *Radiology* 1988;169:109-115
18. Terwey B, Becker H, Thron A, Vahldiek G. Gadolinium-DTPA enhanced MR imaging of spinal dural arteriovenous fistulas. *J Comput Assist Tomogr* 1989;13:30-37
19. Willinsky RA, terBrugge K, Montaner W, Wallace MC, Gentili F. Spinal epidural arteriovenous fistulas: arterial and venous approaches to embolization. *AJNR Am J Neuroradiol* 1993;14:812-817

20. Turjman F, Joly D, Monet O, Faure C, Doyon D, Froment JC. MRI of intramedullary cavernous haemangiomas. *Neuroradiology* 1995;37:297-302
21. Holtas S, Basibuyuk N, Fredriksson K. MRI in acute transverse myelopathy. *Neuroradiology* 1993;35:221-226
22. Willinsky RA, terBrugge K, Montanera W, Mikulis D, Wallace MC. Venous Congestion: an MR finding in dural (AVM) with cortical venous drainage. *AJNR Am J Neuroradiol* 1994;15:1501-1507
23. Provenzale JM, Tien RD, Felsberg G, Hacıen-Bey L. Spinal dural arteriovenous fistula: demonstration using phase contrast MRA. *J Comput Assist Tomogr* 1994;18:811-814
24. Thorpe JW, Kendall BE, MacManus DG, McDonald W, Miller D. Dynamic gadolinium-enhanced MRI in the detection of spinal (AVM). *Neuroradiology* 1994;36:522-529
25. Aggarwal S, Willinsky R, Montanera W, terBrugge K, Wallace MC. Superselective angiography of a spinal dural arteriovenous fistula having a common segmental origin with the artery of Adamkiewicz. *Neuroradiology* 1992;34:352-354