



Discover Generics

Cost-Effective CT & MRI Contrast Agents



FRESENIUS
KABI

WATCH VIDEO

AJNR

MR findings of sclerosing cervicitis.

R J Ernst and R S Cornelius

AJNR Am J Neuroradiol 1995, 16 (3) 507-508

<http://www.ajnr.org/content/16/3/507>

This information is current as
of June 3, 2025.

MR Findings of Sclerosing Cervicitis

Robert J. Ernst and Rebecca S. Cornelius

Summary: The MR appearance of sclerosing cervicitis in the case presented is that of a fusiform mass arising in the lateral neck with vascular encasement. The mass is mildly hyperintense to skeletal muscle on the T1- and T2-weighted images.

Index terms: Neck, inflammation; Sclerosis

Sclerosing cervicitis is an unusual manifestation of idiopathic multifocal fibrosclerosis that includes other entities such as retroperitoneal fibrosis, mediastinal fibrosis, sclerosing cholangitis, Reidel thyroiditis, and orbital fibrosis. Recently the computed tomographic characteristics of sclerosing cervicitis have been described (1). This case report presents the magnetic resonance (MR) findings in a case of sclerosing cervicitis. The clinical and histopathologic findings in this case have been more completely described in another report (2).

Case Report

A 44-year-old white man presented with a left neck mass. Medical history was remarkable only for peptic ulcer disease and lumbar spondylosis. Medications included ranitidine with no history of methysergide or ergot derivatives. Physical examination revealed a smooth, firm left neck mass. Upon palpation of the mass, a vasovagal response was elicited, which resulted in bradycardia, hypotension, and near syncope.

The MR was performed on a General Electric Signa 1.5-T magnet with routine spin-echo imaging. Spin-echo sequences included 600/11/4 (repetition time/echo time/excitations), 2000/30/2, 2000/80/2, and postcontrast images. The study revealed a fusiform mass extending from the distal left common carotid artery superiorly to approximately 2 cm below the skull base (Figs 1–3). The mass was smooth in contour and uniform in signal intensity. The distal left common carotid artery, proximal left external carotid artery, and a significant portion of the cervical left internal carotid artery were involved by the mass. Mild circumferential narrowing of the left common carotid artery and its bifurcation was present. On T1- and T2-weighted images, the mass showed low signal intensity,

which was only slightly hyperintense compared to skeletal muscle. After intravenous gadolinium administration there was inhomogeneous contrast enhancement.

Angiography demonstrated a relatively avascular mass encasing the left common carotid artery and its bifurcation.

The patient underwent complete resection with reconstruction of the left carotid artery using a saphenous vein graft and had an uneventful postoperative course.

Pathologically, the mass was described as dense fibrous tissue with inflammatory infiltrates consisting of predominantly lymphocytes and plasma cells with occasional eosinophils. The fibrous tissue and inflammatory cells surrounded and infiltrated nerve bundles and adjacent adipose tissue. There was no evidence of necrosis, granulomas, or underlying malignant tumor. Histologically, the mass was similar to retroperitoneal and mediastinal fibrosis.

Discussion

Sclerosing cervicitis is a fibrotic lesion of the neck described by Rice et al in 1975 (3). Histologically and pathologically, sclerosing cervicitis is similar to other fibrosing disorders such as retroperitoneal fibrosis and mediastinal fibrosis (4). Histologic findings include dense fibrosis with an inflammatory infiltrate.

The majority of cases of fibrosclerosis are idiopathic. Associated causes include drugs such as methysergide (an ergot derivative), infections including tuberculosis and fungal diseases, neoplasm with associated desmoplastic response, and prior hemorrhage (5). The differential diagnosis of such a mass would include lymphoma and aggressive fibromatosis.

Sequelae of sclerosing cervicitis include vascular compression, nerve entrapment, and symptoms from other areas of involvement in multifocal sclerosis.

MR imaging of sclerosing cervicitis may provide potential advantages compared with CT through use of its multiplanar capabilities. In the


Received February 5, 1993; accepted after revision June 7.
From the University of Cincinnati (Ohio).

Address reprint requests to Robert J. Ernst, MD, Department of Radiology, University of Cincinnati, 234 Goodman St, Cincinnati, OH 45267-0742.

Fig 1. Sagittal T1-weighted image (600/11/1) of the neck reveals a fusiform mass encircling the distal left common carotid artery, bifurcation, and proximal left internal carotid artery.

Fig 2. Axial T2-weighted image (2000/80/2) shows the mass surrounding the left external carotid artery and left internal carotid artery. The left internal carotid artery is slightly reduced in diameter compared with the right internal carotid.

Fig 3. Axial T1-weighted image (600/11/4) after contrast reveals moderate diffuse inhomogeneous enhancement of the mass.



1

2

3

case presented, the smooth contour of the mass with vascular encasement and lack of significant vessel displacement are similar to the radiologic appearance of retroperitoneal fibrosis. Because sclerosing cervicitis is histologically related to retroperitoneal fibrosis, it would seem that the MR characteristics would be similar as well. The MR findings of retroperitoneal fibrosis have been described (5, 6). The mature fibrotic plaque tends to be hypointense on both the T1- and T2-weighted images. High signal has been reported on T2-weighted images and may be associated with either benign or malignant disease. The high signal abnormality in the benign form is felt to represent edema and/or cellular infiltrate (5). Therefore, sclerosing cervicitis probably can exhibit a variable appearance in signal intensity. The exact cause of the prominent contrast enhancement of the mass on MR is uncertain. This may be related to the diffuse

inflammatory infiltrates seen on pathologic sections. The mass was relatively avascular on angiography.

References

1. Smith M, Castillo M, Weissler M. CT findings in a case of exuberant cervical fibrosclerosis. *AJR Am J Roentgenol* 1992;159:1263-1264
2. Portugal LG, Gluckman JL, Biddinger PW. Sclerosing cervicitis: an unusual case of syncope. *Am J Otolaryngol* 1993;14:358-362
3. Rice DH, Batsakis JG, Coulthard SW. Sclerosing cervicitis. *Arch Surg* 1975;110:120-122
4. Esdaile I, Murray D, Hawkins D, MacKenzie R. Idiopathic fibrosis of the lateral compartment of the neck. *Arch Intern Med* 1980;140:1386-1387
5. Amis ES Jr. Retroperitoneal fibrosis. *AJR Am J Roentgenol* 1991;157:321-329
6. Hricak H, Higgins CB, Williams RD. Nuclear magnetic resonance imaging in retroperitoneal fibrosis. *AJR Am J Roentgenol* 1983;141:35-38

Ex: 6238
Se: 1
Im: 2

857

06/18/92
L36.0
MF: 1.0

A
7
0

P
5
0

TR: 600
TE: 11/Pr
S: 0thk/1.0sp
W: 366/L: 192

168

1

Ex: 6238

A80

06/18/92

Set 8

816.0

Im: 24

MFR 1.0

R
5
1

L
6
9

TR: 2000

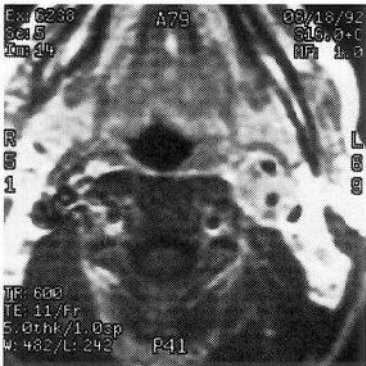TE: 80/Fr

5.0thk/1.0sp

W: 198/L: 98

P40

2



3