



Get Clarity On Generics

Cost-Effective CT & MRI Contrast Agents

 FRESENIUS
KABI

WATCH VIDEO

AJNR

The aryepiglottic fold as a rare location of adenoid cystic carcinoma.

E de Kerviler, N Bely, O Laccourreye, O Clöment, P Halimi and G Fria

AJNR Am J Neuroradiol 1995, 16 (6) 1375-1377

<http://www.ajnr.org/content/16/6/1375>

This information is current as
of August 13, 2025.

The Aryepiglottic Fold as a Rare Location of Adenoid Cystic Carcinoma

Eric de Kerviler, Natacha Bely, Ollivier Laccourreye, Olivier Clément, Philippe Halimi, and Guy Fria

Summary: We report one case of a mass in the aryepiglottic fold seen on CT, which proved to be an adenoid cystic carcinoma. There was nothing specific about the imaging characteristics that would allow it to be confidently differentiated from squamous cell carcinoma.

Index terms: Carcinoma; Larynx, neoplasms

Adenoid cystic carcinomas, previously called *cylindromas*, are uncommon tumors involving the salivary glands. They represent about 35% of malignant salivary tumors. These potentially resectable tumors have different degrees of malignancy. They tend to spread by perineural extension and frequently recur after initial treatment. Such tumors may be suspected when occurring at the usual site of the salivary glands. However, minor salivary glands are found in various locations, extending from the paranasal sinuses to the larynx. We report one case of primary adenoid cystic carcinoma developed from the aryepiglottic fold.

Case Report

A 52-year-old white man had intermittent painful dysphagia. The first symptoms had begun 2 months earlier, without decline of the general status. On physical examination, a left jugular lymph node was palpable. A tumor of the left aryepiglottic fold was noted at time of indirect laryngoscopy. There was no impairment of the laryngeal motion. An enhanced computed tomography (CT) scan of the neck revealed a 2-cm-diameter heterogeneous mass arising from the left aryepiglottic fold (Fig 1). The center of the lesion had low density, whereas a contrast-enhanced irregular rim was seen at the periphery. CT also showed cervical lymph nodes with central low density and peripheral margin enhancement. Pharyngeal endoscopy evidenced a poorly delineated tumor of the left aryepiglottic fold, extending toward the epiglottis, not invading the pharyngeal wall. The lesion was biopsied and all samples demonstrated an undifferentiated carcinoma on histopathologic examination. The patient was initially referred for chemotherapy, but this treatment was stopped after the first sequence because of an acute coronary syndrome. A surgical treatment was decided on, consisting of

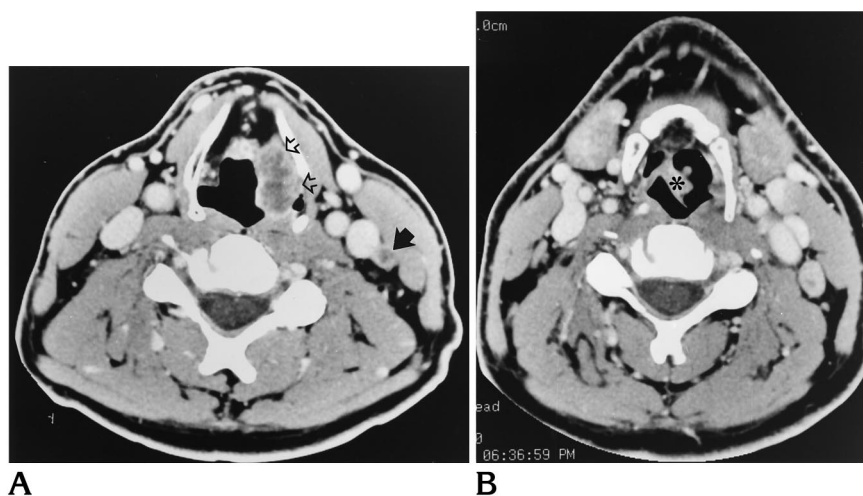


Fig 1. CT scans obtained at the time of diagnosis.

A, Axial CT scan shows a heterogeneous tumor arising from the left aryepiglottic fold (open arrows). The lesion is submucosal, impinging on the airway, and presents poorly defined margins and areas of margin enhancement. An ipsilateral metastatic internal jugular lymph node (arrow) is also clearly seen, with a low density center and peripheral enhancement.

B, Axial CT scan at the level of the hyoid bone shows a thickening of the left side of the epiglottis (asterisk) attributable to an invasive process from the tumor of the left aryepiglottic fold.

Received March 4, 1994; accepted after revision May 18.

From the Department of Radiology, Boucicaut Hospital, Paris, France (E.K., O.C., P.H., G.F.); and the Departments of Radiology (N.B., P.H., G.F.) and Otolaryngology (O.L.), Laënnec Hospital, Paris, France.

Address reprint requests to Eric de Kerviler, MD, Department of Radiology, Laënnec Hospital, 42 rue de Sèvres, 75007 Paris, France.

AJNR 16:1375-1377, Jun 1995 0195-6108/95/1606-1375 © American Society of Neuroradiology

supraglottic laryngectomy with ipsilateral radical neck dissection. Histopathologic examination evidenced an adenoid cystic carcinoma of cribriform type. The limits of removal were free of tumor. However, seven of the eight lymph nodes contained tumor, with ruptured capsule. Three months later, the patient had chest pain and difficulty swallowing, and his clinical status declined. Endoscopy showed a 1-cm-diameter mass arising from the right pharyngeal wall and a paralysis of the left vocal cord. Subsequent CT examination of the neck and the chest evidenced a bilateral local recurrence in association with right internal jugular lymph nodes, bilateral lymph nodes in the tracheoesophageal groove, and pulmonary and pleural metastases (Fig 2). Palliative chemotherapy was decided on the basis of the CT findings. The patient died 1 month later.

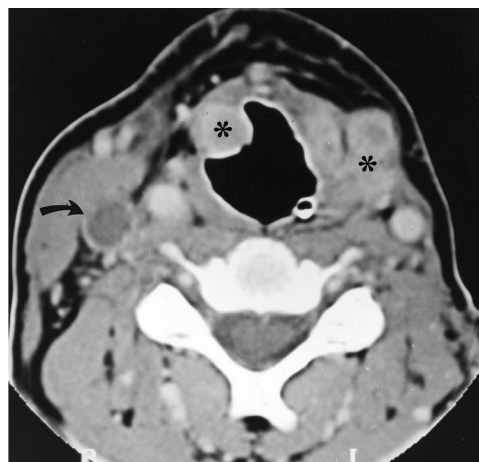Discussion

Of all salivary tumors, 25% to 30% are malignant. Adenoid cystic carcinomas, accounting for 35% of the malignant salivary glands neoplasms, are found mainly at the age of 55 ± 15 years (1, 2). The previous term for this tumor, *cylindroma*, has led to an underestimation of the seriousness of this lesion and for this reason is no longer used. This tumor is definitely not a benign lesion. It tends to have a local extension with perineural and perivascular infiltration and thus must be considered as particularly malignant (3). The only treatment is a radical removal of the tumor in association with radiation therapy, but the prognosis remains poor because of early local recurrence and systemic metastases.

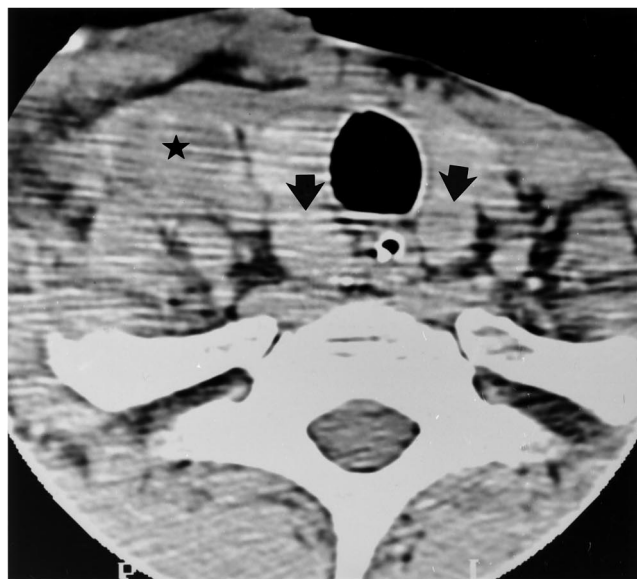Adenoid cystic carcinomas occur relatively often in the minor salivary glands, especially those of the palate, followed by the sublingual, submandibular, and parotid glands (2-4). The minor salivary glands are scattered throughout the oropharyngeal, nasal, sinus, laryngeal, and tracheal mucosa. The aryepiglottic fold forms the boundary between the larynx and the hypopharynx. Each site of the minor salivary glands may be a potential location for an adenoid cystic carcinoma. Recently, a case of pleomorphic adenoma of the epiglottis has been reported (5).

In the largest published series including 174 patients with adenoid cystic carcinomas, one lesion was glottic and two were supraglottic (6). Sigal et al studied 27 patients with adenoid cystic carcinomas with MR imaging. In this series, the lesions were poorly defined with infiltrative margins in 23 cases (6). In our case, a similar

pattern could be observed with CT. Also, the center of the lesion had a low density, a finding that is unusual in other tumors involving this area. Indeed, the main differential diagnosis of adenoid cystic carcinomas was a squamous cell carcinoma, even if the patient was neither a heavy smoker nor a drinker. The CT pattern of squamous cell carcinomas of the pharynx and



A



B

Fig 2. CT scans obtained at the time of recurrence.

A, Axial CT scan at the level of the supraglottic laryngectomy. A 1-cm-diameter tumor arising from the right pharyngeal wall and a large heterogeneous lesion of the left parapharyngeal space are clearly seen (asterisk). A right internal jugular lymph node is also seen, highly suggestive of a metastatic lymph node (curved arrow).

B, Axial CT scan at the level of the thyroid gland demonstrates a large right internal jugular lymph node (star) and bilateral lymph nodes in the tracheoesophageal groove (arrows) causing the vocal cord paralysis.

larynx is often that of a homogeneous tumor, sometimes with necrotic lymph nodes (7).

In conclusion, although the case is extremely rare, the diagnosis of adenoid cystic carcinomas must be considered when aggressive hypopharyngeal or laryngeal tumors are found, especially if the patient is not at risk for squamous cell carcinomas.

References

1. Nascimento AG, Amaral ALP, Prado LAF, Kligerman J, Silveira TRP. Adenoid cystic carcinoma of salivary glands: a study of 61 cases with clinicopathologic correlation. *Cancer* 1986;57:312-319
2. Som PM. Salivary glands. In: Som PM, Bergeron RT, eds. *Head and Neck Imaging*. 2nd ed. St Louis: Mosby-Year Book, 1991:335-336
3. Michaels L. Adenoid cystic carcinomas. In: Michaels L, ed. *Ear, Nose and Throat Histopathology*. Heidelberg: Springer-Verlag, 1987:183-185
4. Spiro RH, Koss LG, Hajdu SI, Strong EW. Tumors of minor salivary origin: a clinicopathologic study in 492 cases. *Cancer* 1973;31:117-129
5. Baptista PM, Garcia-Tapia R, Vazquez JJ. Pleomorphic adenoma of the epiglottis. *J Otolaryngol* 1992;21:355-357
6. Sigal R, Monnet O, de Baere O, et al. Adenoid cystic carcinoma of the head and neck: evaluation with MR imaging and clinicopathologic correlation in 27 patients. *Radiology* 1992;184:95-101
7. Som PM. Detection of metastasis in cervical lymph nodes: CT and MR criteria and differential diagnosis. *Am J Roentgenol* 1992;158:961-969