



Get Clarity On Generics

Cost-Effective CT & MRI Contrast Agents

**FRESENIUS
KABI**

[WATCH VIDEO](#)

AJNR

Spurious hyperfixation of hexamethylpropyleneamine oxime in acute embolic stroke.

S Shintani, S Tsuruoka and Y Satoh

AJNR Am J Neuroradiol 1995, 16 (7) 1532-1535

<http://www.ajnr.org/content/16/7/1532>

This information is current as
of August 7, 2025.

Spurious Hyperfixation of Hexamethylpropyleneamine Oxime in Acute Embolic Stroke

Shuzo Shintani, Shin Tsuruoka, and Yasuhiro Satoh

Summary: A 71-year-old man with atrial fibrillation suddenly had an embolism in the right middle cerebral artery. Single-photon emission CT was performed 4 hours after the onset of stroke and revealed markedly elevated ^{99m}Tc -hexamethylpropyleneamine oxime (HMPAO) uptake in the right frontotemporoparietal region. This area of HMPAO hyperfixation corresponded to the area of infarction, as determined by CT and MR. Our findings showed that HMPAO single-photon emission CT overestimated reflow hyperemia after reperfusion in the acute stage of embolic stroke, as it does in the subacute stage.

Index terms: Brain, infarction; Cerebral embolism; Single-photon emission computed tomography

Brain imaging with single-photon emission computed tomography (SPECT) reflects regional cerebral blood flow and is useful for topographic identification of brain lesions. The distribution of ^{99m}Tc -hexamethylpropyleneamine oxime (HMPAO) in the brain is determined 2 to 3 minutes after it is injected intravenously and remains stable for a period of about 10 hours (1, 2). However, a recent report indicated that SPECT with HMPAO can overestimate reflow hyperemia after spontaneous reperfusion in patients with subacute ischemic stroke (2 to 3 weeks) (3). We investigated SPECT findings in a patient with acute embolic stroke.

Case Report

A 71-year-old man with paroxysmal atrial fibrillation was admitted to our hospital for defibrillation on June 11, 1993. He had had a previous myocardial infarction. His family history was unremarkable.

On day 7, at 9:50 AM left hemiplegia suddenly developed. At the onset of the stroke, his blood pressure was 163/82 mm Hg, and his heart rate was 78 beats per minute and irregular. Neurologic examination revealed flaccid

hemiplegia on the left side of his body, including his face. He was lucid. Deep tendon reflexes were not increased, but the left plantar extensor response was not present. Brain computed tomography (CT) performed at noon, 2 hours after the onset of stroke, showed no abnormalities.

At 2 PM, four hours after the onset of stroke, SPECT with ^{99m}Tc -HMPAO as the tracer was performed. At that time, the patient's blood pressure was 149/95 mm Hg, and his heart rate was 70 to 90 beats per minute. Simultaneous intravenous administration of 2400×10^4 U of tissue plasminogen activator (TPA) was started at the same time. TPA infusion was completed 1 hour later. The SPECT study showed unexpected marked hyperfixation of HMPAO in the right frontotemporoparietal region (Fig 1 A and B). After the SPECT study and the administration of TPA (5 hours after the onset of stroke), the patient showed partial clinical recovery. He was able to extend and flex his left leg at the knee joint, but could not grip with his left hand. At 4:20 PM (6.5 hours after the onset of stroke), a second CT exam revealed faint low-density lesions on the striatocapsular region and on the white matter of the right hemisphere. His left hemiparesis had completely resolved by this time, and he was able to grip with his left hand. A CT exam performed with contrast enhancement the day after the stroke showed markedly low-density lesions on the striatocapsular region and the white matter of the right hemisphere (Fig 1 C and D), but no neurologic sequelae were observed.

Laboratory tests performed on the day the stroke occurred showed the following: red blood cell count, $458 \times 10^4/\text{mm}^3$; hemoglobin, 14.9 g/dL; hematocrit, 43.2%; white blood cell count, $7500/\text{mm}^3$; and platelets, $15.3 \times 10^4/\text{mm}^3$. Blood chemistry tests showed no abnormal findings. Coagulation test results were within normal ranges. Electrocardiography showed atrial fibrillation. A chest x-ray was normal.

A follow-up CT (Fig 1 E and F), 5 days after the onset of stroke, showed almost the same findings as described in Figure 1 C and D. On June 28, 11 days after the onset of stroke, magnetic resonance revealed a marked reduction in size of the lesion on a T1-weighted image (380/15/2

Received June 16, 1994; accepted after revision November 9.

From the Departments of Neurology (S.S.), Neurosurgery (S.T.), and Internal Medicine (Y.S.), Toride Kyodo General Hospital, Toride City, Ibaraki, Japan.

Address reprint requests to Dr Shuzo Shintani, Department of Neurology, Toride Kyodo General Hospital, 5901-1, Terada, Toride City, 302 Ibaraki, Japan.

JNMR 16:1532-1535, Aug 1995 0195-6108/95/1607-1532 © American Society of Neuroradiology

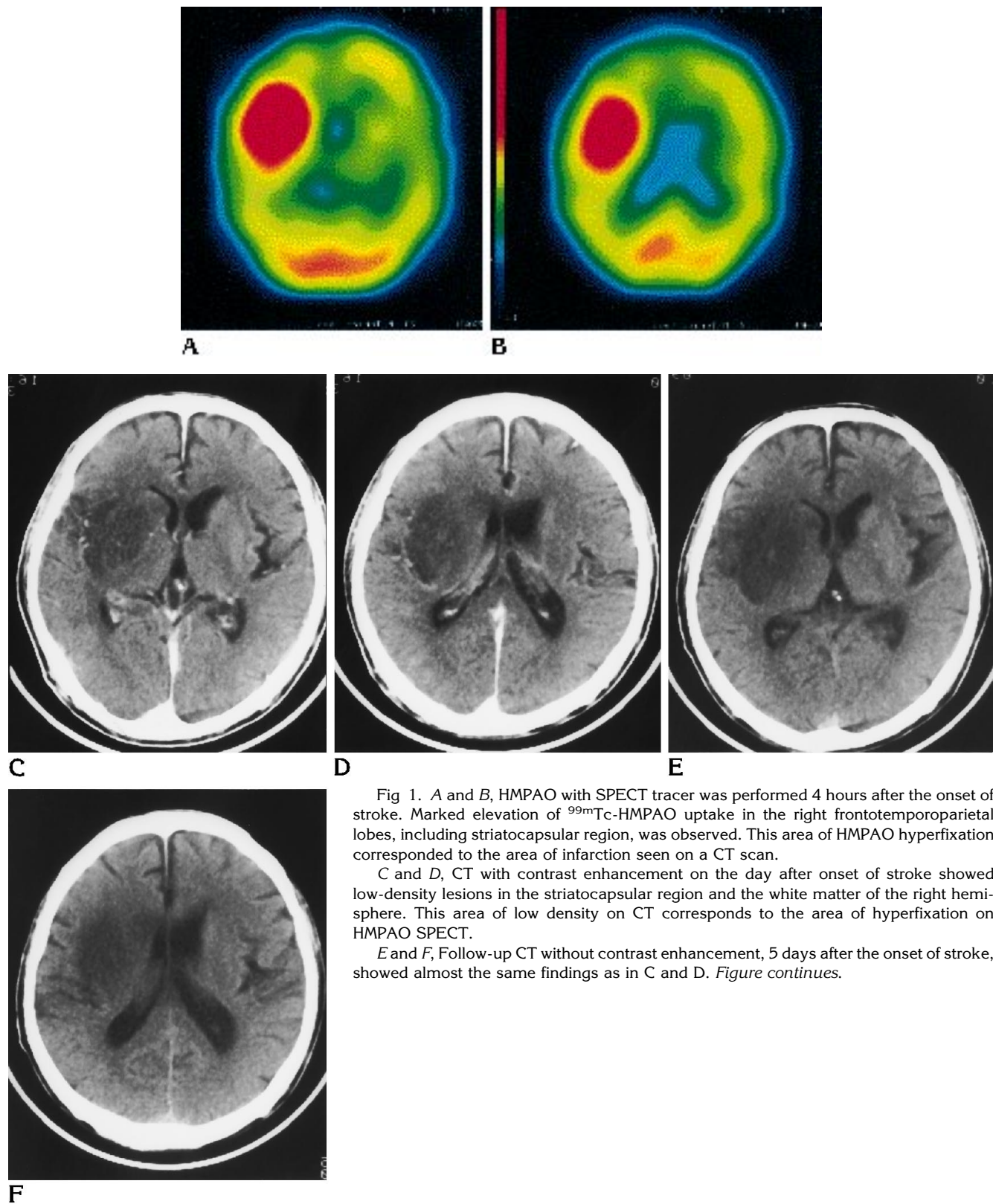
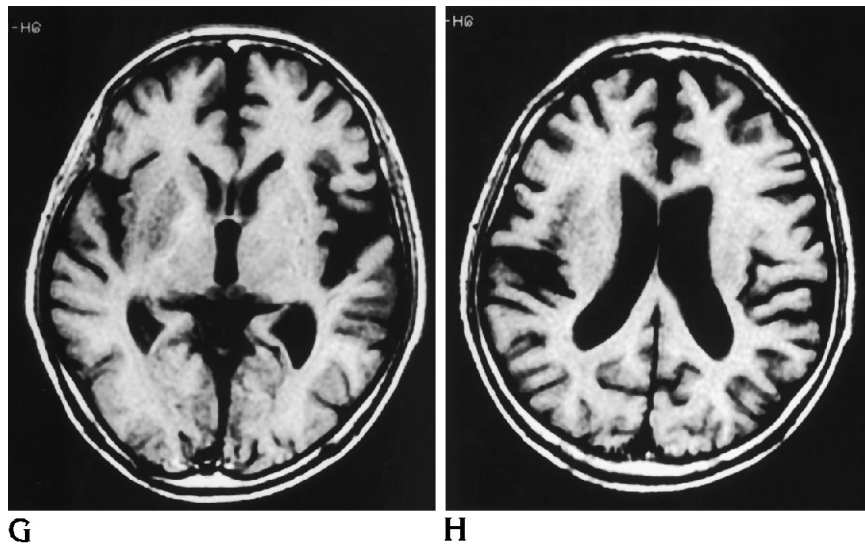


Fig 1. A and B, HMPAO with SPECT tracer was performed 4 hours after the onset of stroke. Marked elevation of ^{99m}Tc -HMPAO uptake in the right frontotemporoparietal lobes, including striatocapsular region, was observed. This area of HMPAO hyperfixation corresponded to the area of infarction seen on a CT scan.

C and D, CT with contrast enhancement on the day after onset of stroke showed low-density lesions in the striatocapsular region and the white matter of the right hemisphere. This area of low density on CT corresponds to the area of hyperfixation on HMPAO SPECT.

E and F, Follow-up CT without contrast enhancement, 5 days after the onset of stroke, showed almost the same findings as in C and D. *Figure continues.*

Fig 1.—continued. *G* and *H*, Magnetic resonance, 11 days after the onset of stroke, revealed a marked reduction in size of the lesion on a T1-weighted image (380/15/2) as compared with the former CT findings. The final extent of infarction was circumscribed within the right putamen and adjacent white matter.



[repetition time/echo time/excitations]) (Fig 1 *G* and *H*) compared with the former CT findings (Fig 1 *C-F*). The lesion of striatocapsular region was circumscribed within the putamen and spared the globus pallidus and internal capsule. The lesion of the white matter was faint and markedly smaller than on prior SPECT and CT studies (Fig 1 *G* and *H*).

Discussion

The clinical course, the presence of atrial fibrillation, and CT findings indicated our patient experienced an embolic stroke in the right middle cerebral artery. The stroke occurred at 9:50 AM. Four hours after the onset of stroke, the intravenous administration of TPA and the SPECT scanning were started simultaneously and were completed 1 hour and 12 minutes later, respectively. The SPECT showed marked hyperfixation of HMPAO in the ischemic region. It remains unclear whether the reperfusion was spontaneous or could be attributed to TPA.

Neuroradiologically, recanalization, spontaneous or secondary to TPA, occurred within 4 hours. Clinically, after the SPECT study and TPA administration, the patient showed a partial recovery. Six and a half hours after the onset of stroke, the neurologic examination showed complete recovery. CTs performed 1 day and 5 days after the onset of stroke (Fig 1 *C-F*) showed large low-density lesions on the striatocapsular region and the white matter of the right hemisphere. However, the MR study, 11 days after the onset of stroke (Fig 1 *G* and *H*), revealed that the final extent of infarction was circumscribed within the putamen and a small region of adjacent white matter.

The progressive development of large, early, CT hypointensities and the final small hypointensity in magnetic resonance after the patient recovered implies that the CT abnormalities were attributable to vasogenic, rather than cytotoxic, edema. There was no blood-brain barrier breakdown in this case. When MCA recanalization takes more than 8 hours, lesions usually extend to the cortex, but early recanalization of embolic MCA occlusions within 8 hours, in conjunction with good transcortical collateralization, is associated with reduced infarct size and a favorable outcome (4).

In this case, SPECT unexpectedly showed marked hyperfixation of HMPAO in the ischemic region during the acute stage of embolic stroke. This area of HMPAO hyperfixation corresponded to the area of ischemia on CT. The area of HMPAO hyperfixation was located in the right frontotemporoparietal lobes, including the striatocapsular region.

Sperling and Lassen reported that HMPAO SPECT grossly exaggerated reflow hyperemia after spontaneous reperfusion. They observed a 25% increase in reperfusion hyperemia compared with the control region in patients with subacute stroke (2 to 3 weeks after onset) (3). In the present case, HMPAO tomography was performed in the acute stage of embolic stroke. Hyperfixation of HMPAO was more marked in our patient than in the patients described in Sperling and Lassen's report (3). Our findings suggest that HMPAO SPECT grossly overestimates reflow hyperemia after reperfusion in the acute stage of embolic stroke as it does in the subacute

stage. SPECT findings here did not represent so-called luxury perfusion (5).

Limburg and Royen found in 6 of 18 cases an increased SPECT uptake in the ischemic region in the subacute phase of ischemic stroke and stated that SPECT performed 2 weeks after stroke showed no relation with any clinical parameter (6). They speculated that this finding might be attributable to reperfusion hyperemia, increased retention related to increased blood-brain barrier permeability, or retention in macrophages and leukocytes (6).

Baird and Donnan reported that increased ^{99m}Tc -HMPAO uptake is much less common during the acute phase (<48 hours) of ischemic stroke and often is associated with tissue preservation (7). They studied a series of 170 consecutive patients within 48 hours of stroke onset and reported that increased ^{99m}Tc -HMPAO uptake was seen in 6.5% of patients. These regions of increased uptake usually had normal CT appearance at 7 to 14 days (7). In 9 of their patients, the area of increased uptake was restricted to a focal area of cerebral cortex. In 2 of their patients, increased uptake extended over middle cerebral artery cortex in the setting of rapid neurologic improvement from a syndrome

of profound hemispheric ischemia (so-called spectacular shrinking deficit) (8). Our present case is similar to these two cases in SPECT and clinical findings.

References

1. Sharp PF, Smith FW, Gemmell HG, et al. Technetium- ^{99m}Tc -HMPAO stereoisomers as potential agents for imaging regional cerebral blood flow: human volunteer studies. *J Nucl Med* 1986;27:171-177
2. Andersen AR. ^{99m}Tc -D, L-hexamethylenepropyleneamine oxime (^{99m}Tc -HMPAO): basic kinetic studies of a tracer of cerebral blood flow. *Cerebrovasc Brain Metab Rev* 1989;1:288-318
3. Sperling B, Lassen NA. Hyperfixation of HMPAO in subacute ischemic stroke leading to spuriously high estimates of cerebral blood flow by SPECT. *Stroke* 1993;24:193-194
4. Ringelstein EB, Biniek R, Weiller C, Ammeling B, Nolte PN. Type and extent of hemispheric brain infarctions and clinical outcome in early and delayed middle cerebral artery recanalization. *Neurology* 1992;42:289-298
5. Lassen NA. The luxury perfusion syndrome and its possible relation to acute metabolic acidosis within the brain. *Lancet* 1966;11:1113-1115
6. Limburg M, Royen EA. Unreliability of rCBF-SPECT in subacute ischemic stroke (letter). *Stroke* 1993;24:1099-1091
7. Baird AE, Donnan GA. Increased ^{99m}Tc -HMPAO in Ischemic Stroke (letter). *Stroke* 1993;24:1261-1262
8. Minematsu K, Yamaguchi T, Omae T. "Spectacular shrinking deficit": rapid recovery from a major hemispheric syndrome by migration of an embolus. *Neurology* 1992;42:157-162