



Get Clarity On Generics

Cost-Effective CT & MRI Contrast Agents



FRESENIUS
KABI

WATCH VIDEO

AJNR

Bilateral retrosomatic clefts at multiple lumbar levels.

M Soleimanpour, M L Gregg and R Paralicci

AJNR Am J Neuroradiol 1995, 16 (8) 1616-1617

<http://www.ajnr.org/content/16/8/1616>

This information is current as
of August 15, 2025.

Bilateral Retrosomatic Clefts at Multiple Lumbar Levels

Mehdi Soleimanpour, Michael L. Gregg, and Raul Paraliticc

Summary: Low back pain developed in a 44-year-old woman with a history of rheumatoid arthritis. Radiographs of the lumbar spine revealed bilateral pedicle defects at L-3, L-4, and L-5, with widening of the spinal canal and spondylolisthesis of L-5 on S-1. CT more clearly demonstrated bilateral retrosomatic clefts at multiple levels.

Index term: Spine, abnormalities and anomalies

Clefts may occur in a variety of locations in the vertebral arch. Retrosomatic clefts occur in the pedicles and have been reported from T-12 through L-5 (1, 2). Five reported cases of retrosomatic clefts were bilateral but did not seem to involve more than one vertebral level (1, 3–5). The following case report describes a woman with bilateral retrosomatic clefts at three consecutive levels.

Case Report

A 44-year-old woman had gradual onset of low back pain over a 1-month period. She reported no previous trauma. Her medical history included a diagnosis of rheumatoid arthritis 16 years earlier. She denied any family history of arthritis or other connective tissue or autoimmune diseases. Physical examination revealed no paresthesias or leg weakness. An antinuclear antibody test was positive with a titer of 1:160 and a homogeneous pattern. Rheumatoid factor was positive with a titer of 1:1280, but anti-DNA antibodies were negative. The erythrocyte sedimentation rate (Westergren) was elevated, at 33 mm/h. Radiographs of the lumbar spine revealed bilateral pedicle defects at the L-3, L-4, and L-5 levels with widening of the spinal canal and anterior spondylolisthesis of L-5 on S-1 (Fig 1A). Computed tomography more clearly demonstrated the bilateral retrosomatic clefts at multiple levels (Fig 1B and C). The patient refused to have flexion and extension views of the lumbar spine.

Discussion

Retrosomatic clefts are defects in the pedicles of the vertebral arch. Clefts may also be seen in the pars interarticularis (spondylolysis), lamina (retroisthmie cleft), or the paraspinous or spinous regions (spina bifida). Most of the reported cases involve women, usually older than 30 years (1). Recognition of retrosomatic clefts is important, because they may be mistaken for traumatic pedicle fractures.

The cause of retrosomatic clefts is uncertain. Many authors believe the defects represent congenital anomalies, (2–4, 6, 7); others claim that fractures may be responsible (5), but many reported cases lack histories of trauma. Likewise, the reported coexistence of other vertebral anomalies also tends to favor a congenital cause. Affected pedicles may be elongated (4), shortened (6), or thickened (7) with coexisting contralateral spondylolysis in the same vertebrae (4, 6), scalloping of T-11 through L-1 vertebrae, and an arachnoid cyst in the lower thoracic region (7).

Retrosomatic clefts in the lumbar spine have been discovered in skeletal collections (5), at autopsy (4), and with radiography (2, 3, 6, 7). The clefts were bilateral in five of these cases. In three cases bilateral clefts were diagnosed radiographically in vivo (1, 3). Figure 1 demonstrates bilateral retrosomatic clefts occurring at three consecutive levels.

Clefts occurring at a single vertebral level without associated disk disease probably have no clinical significance; however, involvement at multiple levels may be significant. Our patient showed generalized widening of the spinal canal with anterior spondylolisthesis of L-5 on S-1. Spinal instability may be present in such cases.

Received March 15, 1994; accepted after revision December 14.

From the Department of Radiology, St Elizabeth Hospital Medical Center, Youngstown, Ohio (M.S.); the Department of Medical Imaging, Miami Valley Hospital, Dayton, Ohio (M.L.G.); and Cobb Radiology, Austell, Ga (R.P.).

Address reprint requests to Mehdi Soleimanpour, MD, Department of Radiology, St Elizabeth Hospital Medical Center, 1044 Belmont Ave, PO Box 1790, Youngstown, OH 44501.

AJNR 16:1616–1617, Sep 1995 0195-6108/95/1608–1616 © American Society of Neuroradiology

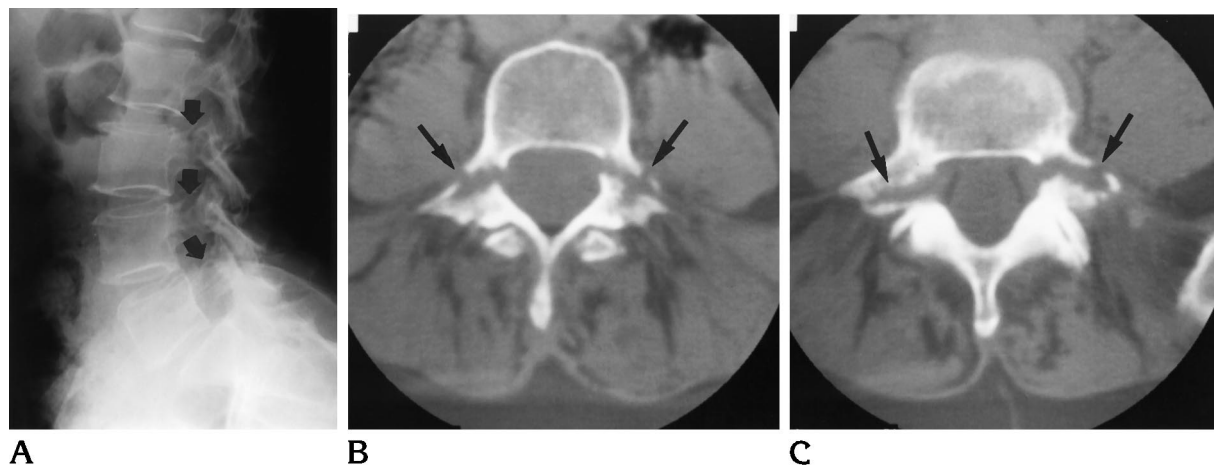


Fig 1. A, Lateral projection of the lumbar spine reveals bilateral pedicle defects at L-3, L-4, and L-5 (arrows). Grade I spondylolisthesis at L5-S1 is also noted.

B, Computed tomogram of the lumbar spine demonstrates the pedicle defects of L-4 (arrows).

C, Bilateral pedicle defects are also seen at L-5 (arrows).

References

1. Johansen JG, McCarty DJ, Haughton VM. Retrosomatic clefts: computed tomographic appearance. *Radiology* 1983;148:447-448
2. Dietemann JL, Macedo R, Medjek L, Babin E, Wackenheim A. Lyse pediculaire bilaterale dans un cas de neurofibromatose. *Ann Radiol* 1981;24:665-667
3. Olsson O. Über eine Spaltenbildung in den Bogenwurzeln des 2 Lendenwirbels. *Acta Radiol* 1948;30:243-248
4. Hammerbeck W. Angeborene Spaltbildung an den Bogenwurzeln des vierten Lendenwirbels (mit besonderer Berücksichtigung der Spondylolisthese). *Fortschr Röntgenstr* 1936;54:144-154
5. Stewart TD. The age incidence of neural arch defects in Alaskan natives, considered from the standpoint of etiology. *J Bone Joint Surg (Am)* 1953;35:937-950
6. Henze E. Eine seltene Lokalisation der konstitutionell bedingten Wirbelbogenspalten. *Fortschr Röntgenstr* 1961;95:140-141
7. Seegelken K, Schulte GA. Spaltbildungen des Wirbelbogens. (Mitteilung der Beobachtung einer retrosomatischen Spalte). *Fortschr Röntgenstr* 1972;116:473-477