



Get Clarity On Generics

Cost-Effective CT & MRI Contrast Agents



FRESENIUS
KABI

WATCH VIDEO

AJNR

MR of malignant optic glioma of adulthood.

W S Millar, L M Tartaglino, R C Sergott, D P Friedman and A E Flanders

AJNR Am J Neuroradiol 1995, 16 (8) 1673-1676

<http://www.ajnr.org/content/16/8/1673>

This information is current as
of August 18, 2025.

MR of Malignant Optic Glioma of Adulthood

William S. Millar, Lisa M. Tartaglino, Robert C. Sergott, David P. Friedman, and Adam E. Flanders

Summary: A case of malignant optic glioma of adulthood is imaged in its early and late stages with high-resolution MR. The images show the mass to arise from the right optic nerve before invasion of the optic chiasm.

Index term: Glioma; Nerves, optic (II)

In adults, malignant optic gliomas are rare, rapidly fatal visual pathway tumors that can mimic optic neuritis in their initial clinical presentation (1). We report the magnetic resonance (MR) imaging appearance of a case of malignant optic glioma of adulthood that originated in the proximal right optic nerve and rapidly progressed to involve the optic chiasm, hypothalamus, ependyma, and left optic nerve. This case report expands on information available on MR characteristics of malignant optic glioma of adulthood (2) and documents the evolution of this rare malignant neoplasm with high-resolution imaging techniques.

Case History

A 60-year-old man presented with a 3-week history of blurred vision in his right eye. Physical examination of the right eye revealed an afferent pupillary defect, visual acuity of 20/100, and papilledema; examination of the left eye was unremarkable. Initial MR images (Fig 1 A–C) showed nonspecific enlargement and enhancement of the right optic nerve consistent with the clinical diagnosis of optic neuritis. A course of intravenous steroids was instituted, but because there was no response, a medial decompression orbitomy was performed. Meningeal biopsy at that time suggested sarcoidosis.

Six weeks later, the patient returned with markedly decreased visual acuity in the right eye and a central retinal artery occlusion. Examination of the left eye remained unremarkable. The patient was again placed on a course of intravenous steroids. Despite the interval surgery and biopsy, a repeat MR study (not shown) revealed no

significant interval change in the morphology and extent of the right optic nerve abnormality.

Approximately 6 months later, the patient presented with mildly decreased visual acuity (20/50) in the left eye. MR images of the orbit and retroorbital regions showed a large mass involving both optic nerves (Fig 1 D,E) and optic chiasm (Fig 1 F) with invasion of the hypothalamus and seeding of the ependyma (Fig 1 E). Excisional biopsy of the right optic nerve was reported as anaplastic astrocytoma. The patient received radiation and chemotherapy but died 5 months later of tumor progression.

Discussion

Gliomas of the optic pathway can be categorized into two groups: (a) the relatively benign optic nerve glioma that typically occurs in the pediatric population and (b) the malignant optic glioma of adulthood (3). The more common benign optic nerve glioma is considered a low-grade astrocytoma (1, 4) and is frequently associated with neurofibromatosis type 1. Malignant optic glioma of adulthood, on the other hand, is an extremely rare optic pathway tumor. The most recent review of the literature (1) found only 30 reported cases since the turn of the century. Patient ages in that review ranged from 22 to 79 years, with a mean age of 52 years. There is no reported association with neurofibromatosis. Malignant optic glioma of adulthood is classified pathologically as either an anaplastic astrocytoma or a glioblastoma multiforme (3). As such, malignant optic glioma of adulthood represents an unusual presentation of a common tumor of the central nervous system.

At initial presentation of the current case of malignant optic glioma of adulthood, the major MR imaging features were mild enlargement and enhancement of the proximal right optic

Received November 7, 1994; accepted after revision March 13, 1995.

From the Department of Radiology, Thomas Jefferson University Hospital, Philadelphia, Pa (W.S.M., L.M.T., D.P.F., A.E.F.) and the Neuro-Ophthalmology Service, Wills Eye Hospital, Philadelphia, Pa (R.C.S.)

Address reprint requests to William S. Millar, MD, Department of Radiology, Columbia-Presbyterian Medical Center, MHB 4-140, 177 Ft Washington Ave, New York, NY 10032

AJNR 16:1673–1676, Sep 1995 0195-6108/95/1608–1673 © American Society of Neuroradiology

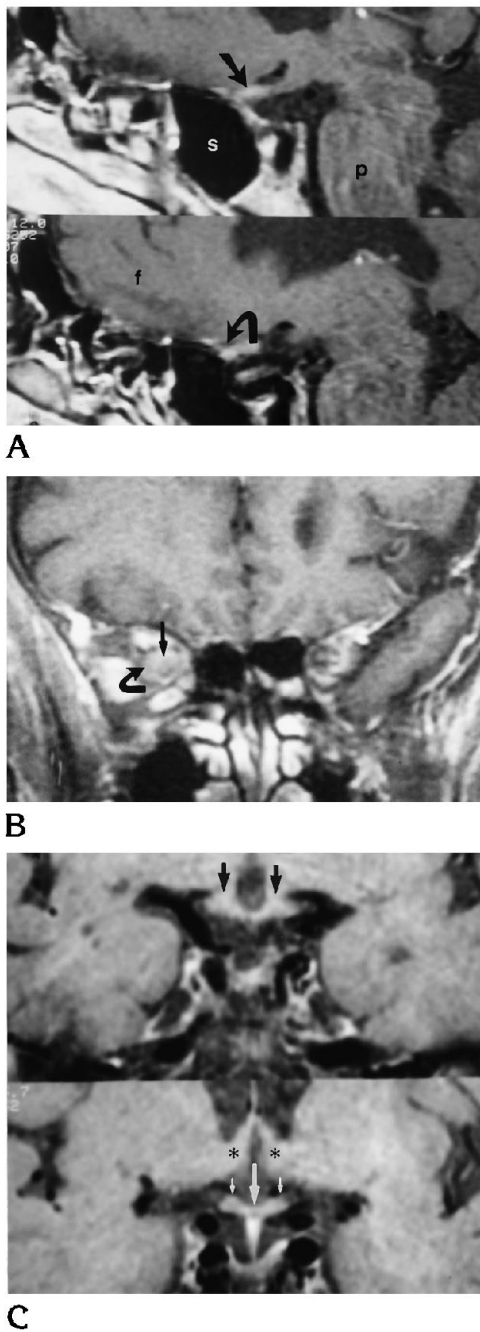


Fig 1. A 60-year-old man with malignant optic glioma of adulthood. A–C, Initial presentation.

A, Contrast-enhanced right parasagittal T1-weighted (800/23/2 [repetition time/echo time/excitations]) MR images show mild enlargement and contrast enhancement of a prechiasmal segment (*straight arrow*) and proximal intracanalicular segment (*curved arrow*) of the right optic nerve. P indicates pons; s, sphenoid sinus; and f, right frontal lobe.)

B, Contrast-enhanced coronal T1-weighted (450/11/2) MR image of the orbital apex with fat-suppression technique shows enlargement and enhancement of right optic nerve (*straight arrow*) as well as abnormal enhancement of optic nerve sheath and adjacent fat (*curved arrow*).

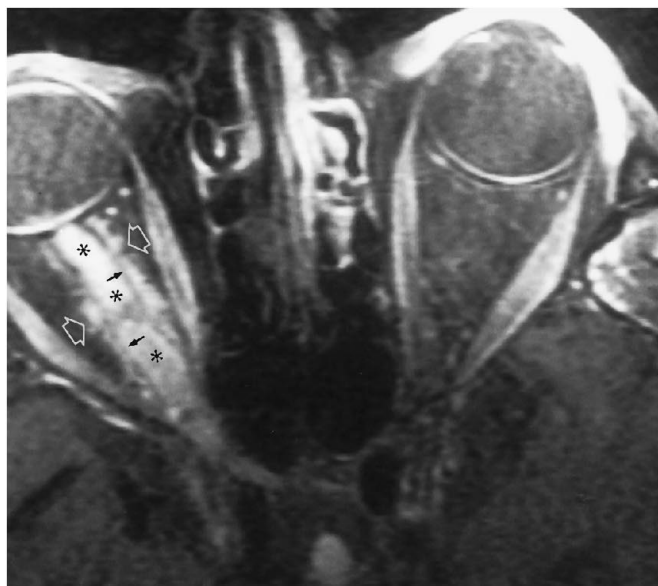
nerve (Fig 1 A,B) without involvement of the optic chiasm (Fig 1C). These features of malignant optic glioma of adulthood in its early stages are nonspecific. Similar findings may be seen in demyelinating conditions such as multiple sclerosis, inflammatory and infectious causes of optic perineuritis, primary low-grade optic nerve gliomas, lymphoma, leukemia, and metastasis (4).

In the current case, 9 months after initial presentation, MR images of malignant optic glioma of adulthood showed an aggressive process, which extensively involved the right optic nerve and sheath (Fig 1D) as well as the proximal left optic nerve (Fig 1E) and optic chiasm (Fig 1F). We found one report of the MR characteristics of a pathologically proved case of malignant optic glioma of adulthood in its later stages in the literature (2). Our case report supports and expands on these findings in late-stage malignant optic glioma of adulthood through the use of contrast enhancement and fat-suppression techniques.

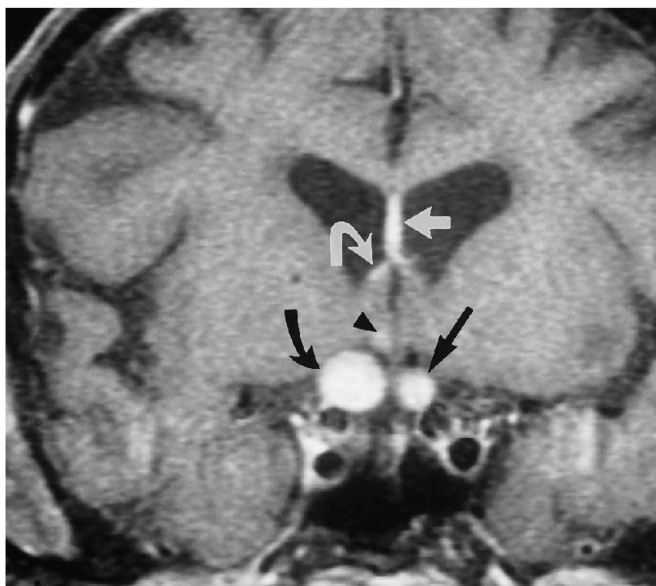
Whereas some pathologic processes enlarge the optic nerve without usually affecting the optic nerve sheath (optic neuritis, optic nerve ischemia), others enlarge the optic nerve sheath without usually affecting the optic nerve (meningioma, pseudotumor) (4, 5). Processes reported to affect frequently both the optic nerve and sheath include optic glioma, perioptic neuritis from infectious and granulomatous causes leukemia, lymphoma, and metastatic disease (4, 5). Those processes that involve both the optic nerve and sheath would be favored in the differential diagnosis of the lesion in this case.

The anatomic point of origin of malignant optic glioma of adulthood has been a source of controversy in the literature (3), largely because of the rarity and rapid progression of malignant optic glioma of adulthood. From the clinical perspective, unocular visual loss suggests origin in the optic nerve, whereas bilateral visual changes imply origin in the optic chiasm (6).

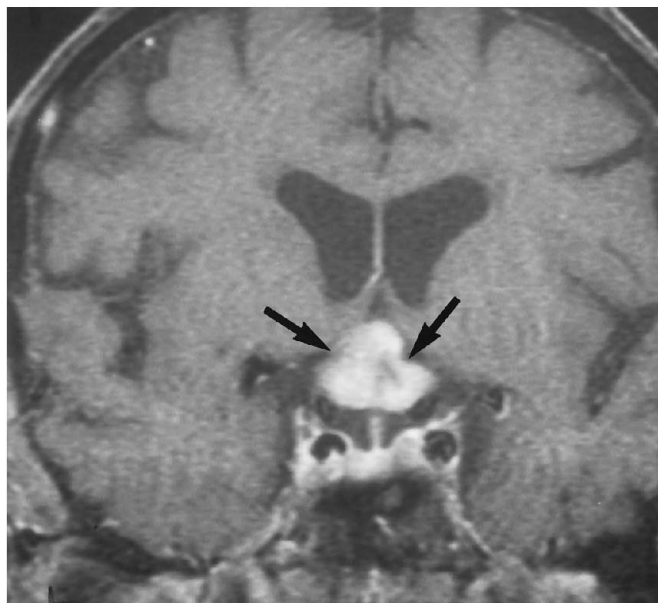
C, Contrast-enhanced coronal T1-weighted (800/23/2) MR images of the optic nerves (*small white arrows*) immediately anterior to the optic chiasm, the optic chiasm (*large white arrow*), and the adjoining posteriorly located optic tracts (*black arrows*) show no evidence of enlargement or contrast enhancement. The hypothalamus (*asterisks*) is uninvolved as well. Slightly more anterior coronal images (not shown) show a mildly enlarged right optic nerve with small medial and lateral foci of peripheral contrast enhancement.



D



E



F

Fig 1, continued.

D-F, Follow-up examination nine months later.

D, Contrast-enhanced axial T1-weighted MR image (650/23/2) of orbits with fat-suppression technique shows enlargement and enhancement of the right optic nerve (asterisks). Spiculated enhancement of intraconal fat (open arrows) adjacent to optic nerve sheath (small closed arrows) is present.

E, Contrast-enhanced coronal T1-weighted MR image (spin-echo 550/14/2) of the retroorbital region with fat-suppression technique reveals homogeneous enhancement of a markedly enlarged right optic nerve (curved black arrow) and a moderately enlarged left optic nerve (straight black arrow). Abnormal enhancement of hypothalamus (arrowhead), septum pellucidum (straight white arrow), and ependyma (curved white arrow) of right lateral ventricle is seen.

F, Contrast-enhanced coronal T1-weighted MR image (spin-echo 550/14/2) shows a large lobulated enhancing mass of the optic chiasm (arrows).

Hypothalamic symptoms, such as polyuria and polydipsia, that may appear late in the clinical course suggest secondary invasion of the hypothalamus by malignant optic glioma of adulthood, rather than a hypothalamic origin of malignant optic glioma of adulthood, as had been suggested in the earlier literature (3, 6). Radiologic proof of malignant optic glioma of adulthood originating in one of the optic nerves rather than the optic chiasm, however, is almost nonexistent. One report (7) with computed tomography and pneumoencephalography find-

ings described a case of malignant optic glioma of adulthood that extensively enlarged the optic nerve but not the optic chiasm. In the current case of malignant optic glioma of adulthood, MR images show an even earlier stage of optic nerve involvement (Fig 1 A,B), again without chiasmal enlargement or enhancement (Fig 1C).

The clinical presentation and evolution in our case is a classic example of the syndrome of malignant optic glioma of adulthood, as defined by Hoyt et al (6). In this syndrome, the physical

signs that would normally raise suspicion for an intraorbital mass are absent, or, when present, occur late in the clinical course and are mild in extent. When an optic nerve is initially involved, the diagnosis of acute optic neuritis is suggested, particularly if a response to intravenous steroids is seen. However, in the syndrome of malignant optic glioma of adulthood, progressive loss of visual acuity, central retinal vein and/or artery occlusion, and monocular blindness occur in rapid succession. Decreased visual acuity in the contralateral eye associated with bilateral optic disk edema suggests chiasmal involvement and can follow as early as 5 to 6 weeks after the initial monocular visual disturbances. Malignant optic glioma of adulthood involving the optic chiasm may then directly invade the hypothalamus, basal ganglia, and internal capsule. Hypothalamic symptoms usually occur late in the clinical course (3). Leptomeningeal and subpial spread of malignant optic glioma of adulthood to the medial temporal lobes and brain stem has been reported at autopsy (7). The current case demonstrates spread of malignant optic glioma of adulthood to the ependyma of the lateral ventricles (Fig 1 E). Previous MR and computed tomography reports of malignant optic glioma of adulthood have not demonstrated this type of spread.

The results of surgery, radiation, and chemotherapy in the treatment of malignant optic glioma of adulthood are extremely disappointing; survival from the time of presentation is usually less than 1 year (2). Consideration of malignant optic glioma of adulthood in the differential diagnosis of optic neuritis, particularly in older patients, may alter the course of an otherwise rapidly fatal malignancy. Because early physical signs of an intraorbital mass are usually absent in the syndrome of malignant optic glioma of adulthood, the role of MR imaging in the early diagnosis of this disease assumes even greater importance.

References

1. Taphoorn MJB, de Vries-Knoppert WAEJ, Ponssen H, Wolbers JG. Malignant optic glioma in adults. *J Neurosurg* 1989;70:277-279
2. Albers GW, Hoyt WF, Forno LS, Shratter LA. Treatment response in malignant optic glioma of adulthood. *Neurology* 1988;1071-1074
3. Harper CG, Stewart-Wynne EG. Malignant optic gliomas in adults. *Arch Neurol* 1978;35:731-735
4. Bilaniuk LT, Atlas SW, Zimmerman RA. The orbit. In: Lee SH, Rao KCVG, Zimmerman RA, eds. *Clinical MRI and CT*. New York, NY: McGraw-Hill; 1992:119-191
5. Rothfus WE, Curtin HD, Slamovits TL, Kennerdell JS. Optic nerve/sheath enlargement. *Radiology* 1984;150:409-415
6. Hoyt WF, Meshel LG, Lessell S, Schatz NJ, Suckling RD. Malignant optic glioma of adulthood. *Brain* 1973;96:121-132
7. Shapiro SK, Shapiro I, Wirtschafter JD, Mastri AR. Malignant optic glioma in an adult. *Minn Med* 1982;65(3):155-159