



## Get Clarity On Generics

Cost-Effective CT & MRI Contrast Agents

 FRESENIUS  
KABI

WATCH VIDEO

# AJNR

## Carcinosarcoma of the salivary gland on CT.

P H Lai, J M Chang, Y Y Hou, S T Chu, S L Lin and C F Yang

*AJNR Am J Neuroradiol* 1995, 16 (8) 1733-1735

<http://www.ajnr.org/content/16/8/1733>

This information is current as  
of August 16, 2025.

---

# Carcinosarcoma of the Salivary Gland on CT

Ping-Hong Lai, Jinn-Ming Chang, You-Yee Hou, Sau-Tung Chu, Shong-Ling Lin, and Chien-Fang Yang

**Summary:** Three cases of carcinosarcoma of the salivary gland, two in the submandibular gland, and one in the parotid, were investigated with CT and exhibited a variety of findings. The density of the tumors was lower than that of normal submandibular tissue. A calcification was found in one case. One case showed extensive lymphadenopathy. The parotid lesion had low central density with an enhancing margin.

**Index terms:** Salivary glands, computed tomography; Salivary glands, neoplasms; Sarcoma

Most malignant salivary gland tumors are carcinomas. The malignant mixed tumor is rare; its overall frequency is less than 2% of all mixed tumors (1). The term *malignant mixed tumor* of the salivary glands has been used to describe three different types of neoplasms. The most common is *carcinoma ex pleomorphic adenoma*, also known as *carcinoma ex mixed tumor* or *carcinoma arising in a mixed tumor*, in which carcinoma and remnants of benign mixed adenoma tissue coexist. This type comprises nearly 99% of malignant mixed tumors. The other two types are rare. One is the *metastasizing mixed tumor*, a mixed tumor with distant metastases in which tissue at both sites has a histologically benign appearance of epithelial and stromal components. The other is *carcinosarcoma*, or *true malignant mixed tumor*, composed of both carcinomatous and sarcomatous elements (1–3).

Carcinosarcoma of the salivary gland is a rare lesion that usually occurs in the parotid gland (1). Other locations including submandibular gland, palate, and tongue have been reported (1, 2). We present three cases of carcinosarcoma of the salivary gland, two in the submandibular gland and one in the parotid gland. Computed tomography (CT) studies were only mentioned in two papers (4, 5); however, we

would present and discuss them from the point of view of radiology.

## Case Reports

### Case 1

A 68-year-old man reported palpable nontender masses of 1 year's duration in the left neck. Sonography of the liver revealed no lesions. Contrast-enhanced CT was performed. A fairly homogeneous mass was visible in the left submandibular gland; its density was slightly lower than that of normal submandibular gland tissue. There was lymphadenopathy in the ipsilateral retronasopharyngeal, deep parotid, jugular, spinal accessory, and supraclavical fossa regions (Fig 1). Total excision of the left submandibular gland with radical neck dissection was performed. The pathologic diagnosis was carcinosarcoma, consisting of sarcomatous and carcinomatous tissue. The biphasic composition of both epithelial ductal carcinoma and mesenchymelike chondrosarcoma was noted. Immunohistochemical stain results showed the epithelial cells positive reactivity to cytokeratin and the spindle cells positive to vimentin and S-100 protein. Lymph nodes also were invaded by the tumor cells of both tissue types. The patient received adjuvant postoperative radiation therapy with total dose of 6000 cGy. Six months later, liver metastases were found by sonography and proved by biopsy.

### Case 2

A 47-year-old man had a left neck mass for 6 months. Noncontrast CT showed an enlarged left submandibular gland with a density lower than that of the normal side and a small calcification. The interface between the lesion and the normal salivary gland tissue was indistinct (Fig 2). The patient received total excision of the left submandibular gland. The pathologic diagnosis was carcinosarcoma. Immunohistochemical stain results showed the epithelial cells positive reactivity to cytokeratin and the spindle cells positive to vimentin. The S-100 protein and actin stains also showed focal positive reactivity. After surgery, the

---

Received August 31, 1994; accepted after revision December 27.

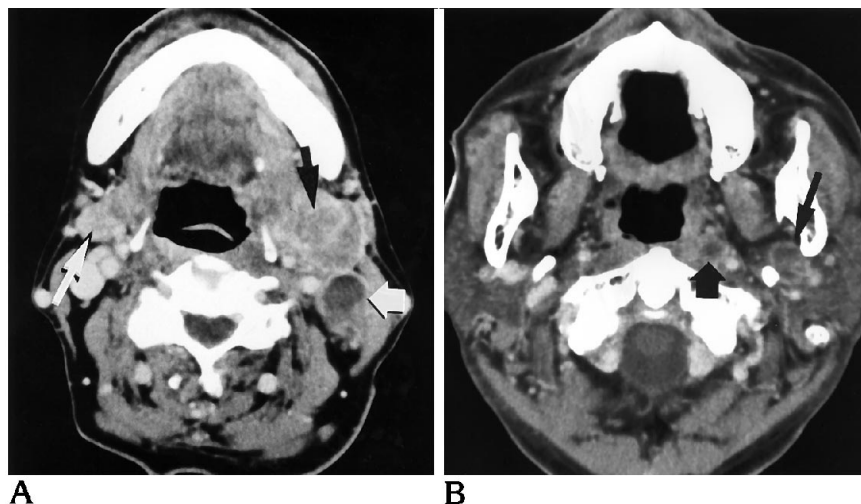
From the Departments of Radiology (P.H.L., J.M.C., C.F.Y.), Otolaryngology (Y.Y.H., S.T.C.), and Pathology (S.L.L.). Kaohsiung Veterans General Hospital, Taiwan, Republic of China.

Address reprint requests to Ping-Hong Lai, MD, Kaohsiung Veterans General Hospital, 386 Tachung First Rd, Kaohsiung, Taiwan 80780, Republic of China.

AJNR 16:1733–1735, Sep 1995 0195-6108/95/1608–1733 © American Society of Neuroradiology

Fig 1. A, Contrast-enhanced CT demonstrates a fairly homogeneous density in the left submandibular gland (*black arrow*) of slightly lower density than that of normal gland on the right side (*thin white arrow*). A small amount of normal residual salivary gland tissue is seen at the anterior margin of the tumor. An adjacent lymph node shows central low density (*thick white arrow*).

B, Involvement of the nodes with central low density in the left retronasopharyngeal area (*thick arrow*) and deep parotid area (*thin arrow*) also is noted.



patient received 6000 cGy of radiotherapy and is doing well with no evidence of disease 1 year later.

### Case 3

A 73-year-old man reported an enlarging mass in the right cheek for 1 year. Contrast-enhanced CT was performed. An enhancing margin with central low density adhering to the masseter muscle was noted in the superficial lobe of parotid gland (Fig 3). Superficial parotidectomy was performed. A tumor involving the adjacent masseter muscle was noted during the surgery. The pathologic diagnosis was carcinosarcoma. Immunohistochemical stain results showed the epithelial cells positive reactivity

to cytokeratin and the spindle cells positive to S-100 protein and actin. After surgery, the patient received 6000 cGy of radiotherapy and was doing well with no evidence of disease within 2 years.

### Discussion

Benign mixed tumors are the most frequently occurring type of salivary gland neoplasms; however, malignant mixed tumors arise much less commonly. Malignant mixed tumor has been classified into three different clinical and pathologic entities by Ellis and Gnepp (6):

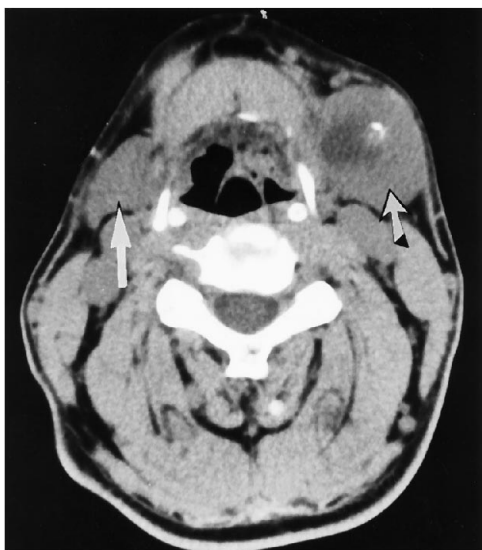


Fig 2. CT without contrast demonstrates the enlarged left submandibular gland with a density lower than that of the normal side (*straight arrow*) and a marginal calcification (*slanted arrow*). The interface between the lesion and the normal salivary gland tissue was indistinct.

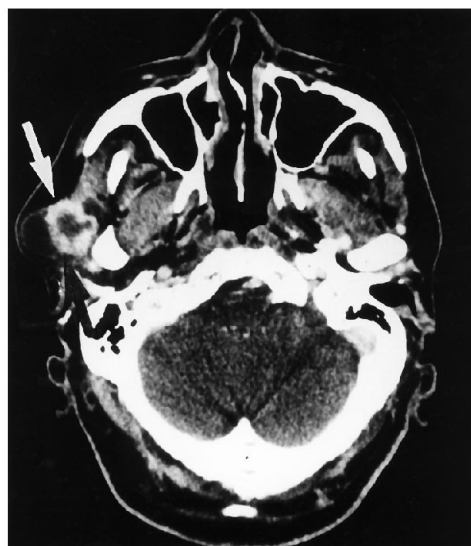


Fig 3. Contrast-enhanced CT demonstrates an enhancing tumor margin (*arrow*) with central low density adhering to the masseter muscle in the superficial lobe of right parotid gland.

(a) carcinoma ex mixed tumor; (b) carcinosarcoma; and (c) metastatic mixed tumor with a benign appearance. Carcinosarcoma, also known as a true malignant mixed tumor, is a tumor in which both the epithelial and stromal components fulfill histologic criteria of malignancy (1–3, 6). These are tumors occurring in midadulthood, commonly in the 6th decade (1, 2).

Immunohistochemical findings of both epithelial and mesenchymal elements have been found (4, 7). Cytokeratin and EMA are epithelial markers, whereas vimentin and S-100 protein are sarcomatous mesenchymal markers. The carcinoma component of these tumors most often is a ductal adenocarcinoma or an undifferentiated carcinoma, whereas chondrosarcoma is the most common sarcomatous component (1, 5, 8). According to the reports of Tortoledo et al (8), the 5-year survival rate with carcinosarcoma is 0%. Another report of Gnepp and Wening (9) shows that the average survival is 29.3 months, and 23% are free of tumors for periods ranging from 5 months to 19 years. No definite association between gross dimensions of the tumor and incidences of recurrence or metastases could be made (8). The modes of metastases are hematogenous and lymphatic. Hematogenous metastases are more common in the lung, bone, and liver. Cervical and hilar lymph node metastases also are common (1, 10). We saw cervical lymph node metastases in the first diagnosis of the first case, and liver metastases also were noted 6 months later. Treatment is commonly surgery, together with radiation therapy and/or chemotherapy.

Our imaging findings are summarized as follows: a fairly homogeneous density slightly lower than that of normal submandibular gland with cervical lymph node metastases in case 1, low-density change and calcification within the tumor of the submandibular gland in case 2, and an enhancing mass with central low density in the parotid gland in case 3. The findings are

somewhat varied when comparing one case with another. The varied histopathologic appearances could be reflected in a varied CT appearance.

There may be cystic change or calcification in the tumor mentioned in the gross specimen (1, 2). Stephen et al (10) described prominent stromal hyalinization, often associated with diffuse areas of calcification, in half of their tumors, whereas occasional tumors had prominent areas of necrosis. This probably explains our findings on CT. The findings are not specific and can be similar to other salivary gland neoplasms. In conclusion, carcinosarcoma of the salivary gland is an extremely rare lesion. These three cases of the rare tumor exhibit varied CT appearances.

## References

1. Gnepp DR. Malignant mixed tumors of the salivary glands: a review. *Pathol Ann* 1993;28:279–328
2. Garner SL, Robinson RA, Maves MD, Barnes CH. Salivary gland carcinosarcoma. *Ann Otol Rhinol Laryngol* 1989;98:611–614
3. Chen KTK, Weinberg RA, Moseley D. Carcinosarcoma of the salivary gland. *Am J Otolaryngol* 1984;5:415–417
4. Bleiweiss IJ, Huvos AG, Lara J, Strong EW. Carcinosarcoma of the submandibular gland. *Cancer* 1992;69:2031–2035
5. Gandour-Edwards RF, Donald PJ, Vogt PJ, Munn R, Min K-W. Carcinosarcoma (malignant mixed tumor) of the parotid: report of a case with a pure rhabdomyosarcoma component. *Head Neck* 1994;16:379–382
6. Ellis GL, Gnepp DR. Unusual salivary gland tumors. In: Gnepp DR, ed. *Pathology of the Head and Neck*. New York, NY: Churchill Livingstone, 1988:623–627
7. Yamashita T, Kameda N, Katayama K, Hiruta N, Nakada M, Takeda Y. True malignant mixed tumor of the submandibular gland. *Acta Pathol Jpn* 1990;40:137–142
8. Tortoledo ME, Luna MA, Batsakis JG. Carcinomas ex pleomorphic adenoma and malignant mixed tumors. *Arch Otolaryngol* 1984;110:172–176
9. Gnepp DR, Wening BM. Malignant mixed tumors. In: Ellis GL, Auclair PL, Gnepp DR, eds. *Surgical Pathology of the Salivary Glands*. Philadelphia, Pa: WB Saunders Co, 1991:357–363
10. Stephen J, Batsakis JG, Luna MA, Heyden UVD, Byers RM. True malignant mixed tumors (carcinosarcoma) of salivary glands. *Oral Surg Oral Med Oral Pathol* 1986;61:597–602