



Get Clarity On Generics

Cost-Effective CT & MRI Contrast Agents



FRESENIUS
KABI

WATCH VIDEO

AJNR

Cardiac sarcoma metastatic to the brain.

G Colon, D J Quint, M Blaivas and J McGillicuddy

AJNR Am J Neuroradiol 1995, 16 (8) 1739-1741

<http://www.ajnr.org/content/16/8/1739.citation>

This information is current as
of August 20, 2025.

Cardiac Sarcoma Metastatic to the Brain

Gary Colon, Douglas J. Quint, Mila Blaivas, and John McGillicuddy

Summary: We present a case of a patient who underwent cardiac transplantation for sarcoma only to relapse with brain metastasis 6 months later.

Index terms: Brain neoplasms, metastatic; Heart; Sarcoma

Cardiac sarcomas are rare primary cardiac tumors. Because of the few reported cases and relatively poor prognosis of primary cardiac sarcomas, the metastatic potential and behavior of these tumors is not fully understood. In one reported case of cardiac sarcoma metastasizing to the brain (1), the primary tumor could not be resected because of the patient's poor medical condition and the concurrent presence of extensive metastatic disease. Our case is that of a patient with a high-grade sarcoma of the heart without evidence of metastatic disease; 6 months after cardiac transplantation she presented with a solitary brain metastasis.

Case Report

A 29-year-old woman presented to our hospital in December 1993 with a 4-hour duration of inability to move her left face, arm, and leg. In February 1993, she had presented to another hospital with congestive heart failure ultimately determined to be caused by a left cardiac atrial mass. In March 1993, she underwent attempted mass resection, but invasion into the myocardium was identified at surgery. Pathologic analysis revealed a pleomorphic, high-grade sarcoma with osteocartilaginous differentiation. In June 1993, at a second outside institution, after a negative work-up for metastatic disease (which included a head computed tomographic scan), the patient underwent cardiac transplantation with attempted complete resection of the tumor. However, the surgical specimen showed invasion by tumor at the resection margins. The patient had no subsequent chemotherapy or radiation therapy and returned to work being treated with immunotherapy. On admission to our institution in December 1993, the patient had a complete left hemiparesis, including her left face,

without visual deficits. Head computed tomography (Fig 1A and B) showed a 4-cm partially enhancing, predominantly hyperdense right frontal region mass. Angiography (Fig 1C), performed to rule out an underlying vascular malformation (or a mycotic aneurysm in this immunosuppressed patient), confirmed the right frontal space-occupying lesion. Magnetic resonance (MR) imaging (Fig 1D–F) redemonstrated the right frontal lobe hemorrhage and clearly revealed the presence of a 2 × 2-cm mass at the periphery of the hemorrhage. Surgery revealed a 2.5 × 2.0-cm superficial, intracerebral tumor contiguous with the pial margin with a small area of dural invasion, which was resected essentially in one piece from the posterior frontal region. Histologic review (Fig 1G) revealed a highly cellular, fibrosarcoma invading into the arachnoid and the adjacent brain parenchyma; it was histologically similar to the cardiac mass that had been partially resected in March 1993. By the 10th postoperative day, the patient had return of almost normal strength and was able to walk with a cane. Approximately 6 weeks after discharge, the patient presented to the emergency department obtunded with a new right hemiparesis. Imaging evaluation revealed extensive local recurrence of tumor in the transplanted heart, a large left middle cerebral artery distribution stroke presumably caused by an embolus from the recurrent cardiac tumor, and a new right occipital metastasis. As per the patient and family's request, the patient was discharged to home hospice care.

Discussion

Benign myxomas are the most common cardiac neoplasms, whereas primary cardiac sarcomas are rare tumors with a prevalence of only 0.0017% to 0.03% in one large postmortem series (2). There are many types of primary cardiac sarcomas, including angiosarcoma, malignant fibrous histiocytoma, leiomyosarcoma, myxosarcoma, fibrosarcoma, rhabdomyosarcoma, and undifferentiated sarcomas. Of the various cardiac sarcomas, fibrosarcoma is

Received August 5, 1994; accepted after revision December 1.

From the Division of Neurosurgery (G.C., J.M.) and the Departments of Radiology (D.J.Q.) and Pathology (M.B.), University of Michigan Hospitals, Ann Arbor.

Address reprint requests to Douglas J. Quint, MD, B1D520B, Neuroradiology, Box 30, Department of Radiology, University of Michigan Hospitals, 1500 E Medical Center Dr, Ann Arbor, MI 48109-0030.

AJNR 16:1739–1741, Sep 1995 0195-6108/95/1608–1739 © American Society of Neuroradiology

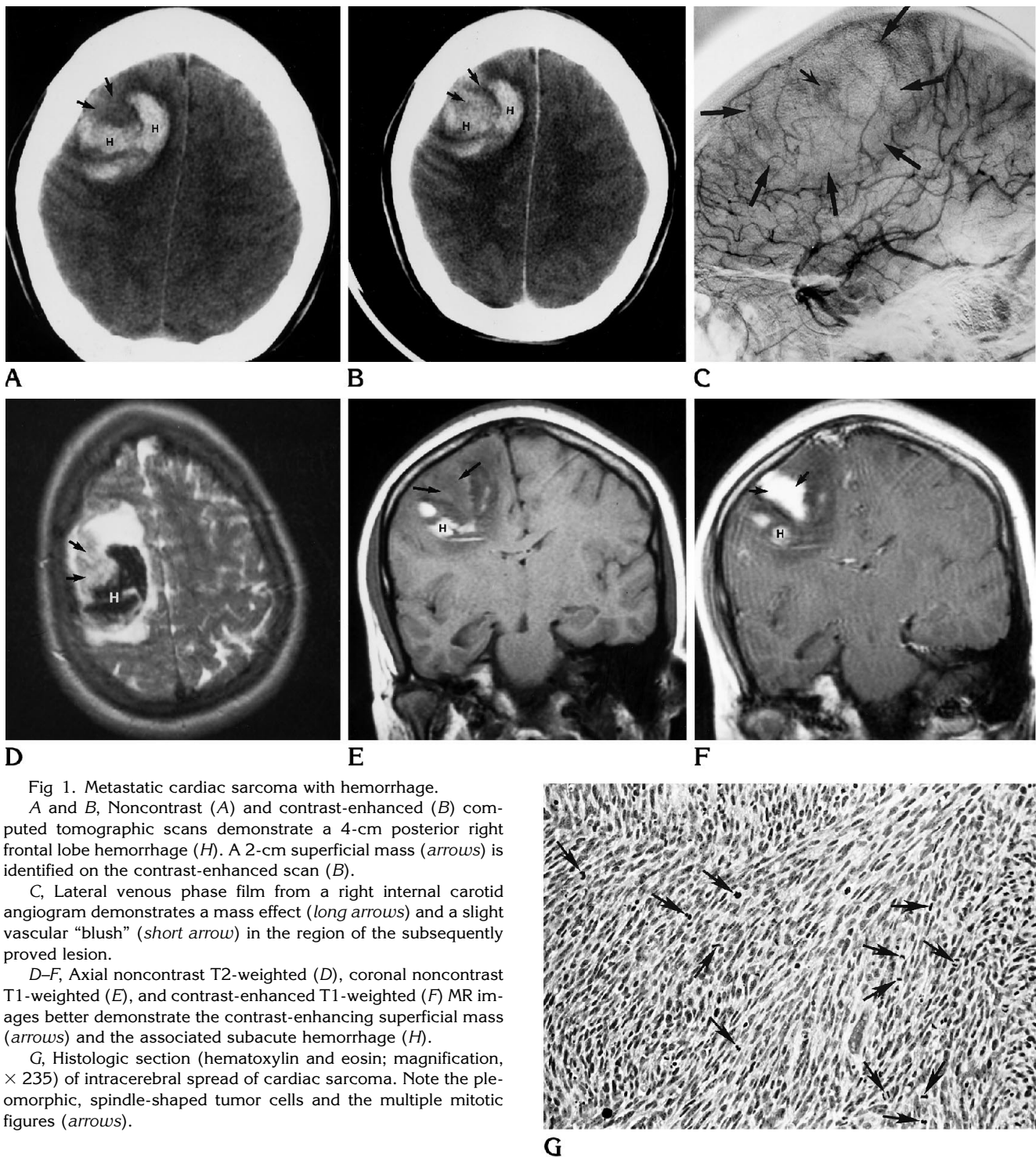


Fig 1. Metastatic cardiac sarcoma with hemorrhage.

A and B, Noncontrast (A) and contrast-enhanced (B) computed tomographic scans demonstrate a 4-cm posterior right frontal lobe hemorrhage (H). A 2-cm superficial mass (arrows) is identified on the contrast-enhanced scan (B).

C, Lateral venous phase film from a right internal carotid angiogram demonstrates a mass effect (long arrows) and a slight vascular "blush" (short arrow) in the region of the subsequently proved lesion.

D-F, Axial noncontrast T2-weighted (D), coronal noncontrast T1-weighted (E), and contrast-enhanced T1-weighted (F) MR images better demonstrate the contrast-enhancing superficial mass (arrows) and the associated subacute hemorrhage (H).

G, Histologic section (hematoxylin and eosin; magnification, $\times 235$) of intracerebral spread of cardiac sarcoma. Note the pleomorphic, spindle-shaped tumor cells and the multiple mitotic figures (arrows).

found in approximately 5% to 15% of patients (3-5). Survival from all cardiac sarcomas is poor, with a median survival of 24 months after complete resection compared with a median survival of only 10 months in patients with incomplete or no tumor resection (2). Radiation

therapy has been shown to have some effect, but the efficacy of current chemotherapeutic regimens is poor (6). Poor prognostic indicators include high numbers of mitotic figures and necrosis on histologic inspection and the presence of metastases (5, 7).

Another case of a primary cardiac sarcoma metastasizing to the brain involved a malignant fibrous histiocytoma of the heart which was widely metastatic at the time of presentation, and resection of the primary cardiac neoplasm was impossible because of the patient's poor medical condition (1). Our case differs from that case in both the histologic type of the sarcoma and the solitary metastatic recurrence of the sarcoma after resection of the primary tumor through cardiac transplantation (although, admittedly, tumor margins were positive at the time of cardiac transplantation). Further imaging evaluation during our patient's initial hospital stay revealed no evidence of either local thoracic recurrence or other more remote areas involved by metastases. However, only 6 weeks later, she did return with extensive cardiac recurrence of her neoplasm and a new presumed brain metastasis.

A similarity between our case and the previously reported cases of cardiac myxomas metastatic to the brain is the presence of intracerebral hemorrhage (8, 9). In fact, Ng and Poon (9) performed a craniotomy with evacuation of an intracerebral hematoma on a patient with a history of previously resected cardiac myxoma. All biopsies from that case at the time of surgery were negative. It was not until 6 months later, when the patient experienced a focal motor seizure, that intracranial metastatic myxoma was discovered during a second operation.

Although the number of reported cardiac myxoma cases metastatic to the brain is too few (only four reported cases) to suggest a mechanism of spread of neoplasm, it is possible that hematogenous spread with intracerebral invasion is a common route of dissemination for both cardiac myxomas and sarcomas. Indeed, cardiac myxoma had been known to present as a hemorrhagic cerebral infarction secondary to myxoma invasion of the vascular wall, resulting in intracranial aneurysm formation (10).

Whether our case represents a belated metastasis from residuum of sarcoma not resected

at the time of transplantation or was present but not of sufficient size to be detected by the initial screening head computed tomography is not known. Because preoperative MR was not performed in this case, it is unknown whether such imaging would have revealed the lesion. However, because it is well known that MR is superior to computed tomography for detection of cerebral metastases, any patient who is scheduled to undergo a major transplantation procedure for an underlying malignant neoplasm, particularly one as aggressive as that present in this case, should have preoperative contrast-enhanced MR imaging to rule out metastases.

Cardiac sarcomas are rare. However, when they do arise, and surgical resection is undertaken, follow-up brain MR should be part of the postoperative care, along with dedicated follow-up thoracic imaging to evaluate for local recurrence.

References

1. Sasaki J, Hayashi N, Nakamura S, et al. Metastatic brain tumor originating from the cardiac sarcoma. *No Shinkei Geka* 1988;16:579-584
2. Poole GV Jr, Meredith JW, Breyer RH, et al. Surgical implications in malignant cardiac disease. *Ann Thorac Surg* 1983;36:484-491
3. Burke AP, Cowan D, Virmani R. Primary sarcomas of the heart. *Cancer* 1992;69:387-395
4. Putnam JB Jr, Sweeney MS, Colon R, et al. Primary cardiac sarcomas. *Ann Thorac Surg* 1992;51:906-910
5. Tazelaar HD, Locke TJ, McGregor CG. Pathology of surgically excised primary cardiac tumors. *Mayo Clin Proc* 1992;67:957-965
6. Turner A, Batrick N. Primary cardiac sarcomas: a report of three cases and a review of the current literature. *Int J Cardiol* 1993;40:115-119
7. Dein JR, Frist WH, Stinson EB, et al. Primary cardiac neoplasms: early and late results of surgical treatment in 42 patients. *J Thorac Cardiovasc Surg* 1987;93:502-511
8. Chozick BS, Ambler MW, Stoll J Jr. Malignant astrocytoma six years after the resection of a cerebral metastatic cardiac myxoma: case report. *Neurosurgery* 1992;30:923-926
9. Ng HK, Poon WS. Cardiac myxoma metastasizing to the brain: case report. *J Neurosurg* 1990;72:295-298
10. Chen HJ, Liou CW, Chen L. Metastatic atrial myxoma presenting as intracranial aneurysms with hemorrhage: case report. *Surg Neurol* 1993;40:61-64