



Transarterial embolization of cerebral arteriovenous malformations: improvement of results with experience.

G Wikholm, C Lundqvist and P Svendsen

AJNR Am J Neuroradiol 1995, 16 (9) 1811-1817

<http://www.ajnr.org/content/16/9/1811>

This information is current as
of August 15, 2025.

Transarterial Embolization of Cerebral Arteriovenous Malformations: Improvement of Results with Experience

Gunnar Wikholm, Christer Lundqvist, and Paul Svendsen

PURPOSE: To present the treatment outcome after embolization of arteriovenous malformations. **METHODS:** All patients with cerebral arteriovenous malformations treated in 1987 and 1988 (27 patients, group I) and in 1992 and 1993 (35 patients, group II) were compared regarding treatment results and clinical outcome. **RESULTS:** Complications of the treatment occurred in 52% of group I and 22% of group II patients. Severe complications occurred in 11% and 0%, respectively. There were no treatment deaths. Thirty percent of the arteriovenous malformations in the first group were totally occluded or made accessible for gamma knife treatment, compared with 69% of the arteriovenous malformations in the second group. The clinical outcome improved from 56% with an excellent or good outcome in group I, to 89% in group II. The follow-up time is much shorter in group II, 1.5 versus 5.5 years in group I. **CONCLUSION:** A definite improvement in treatment outcome has been achieved. The clinical outcome seems to have improved as well, although the shorter follow-up time makes this conclusion less certain.

Index terms: Arteriovenous malformations, cerebral; Arteriovenous malformations, embolization; Efficacy studies

AJNR Am J Neuroradiol 16:1811–1817, October 1995

The discipline of endovascular treatment of cerebrovascular disorders is young. After the works of a handful of pioneers during the 1960s and 1970s (1–5), the methodology started to spread during the 1980s and around 1990 treatment methods became more consistent. Today embolization is an important part of treatment for arteriovenous malformations (AVMs) in many centers. When embolization of AVMs is indicated, two main tactics are used: (a) embolization followed by stereotaxic radiation or surgery if total occlusion is not achieved (6–9) and (b) embolization as a dedicated presurgical measure (10–15).

When studying the development of any new methodology, there is always a learning stage to

take into consideration. If the evolution of the method occurs over several years, changes in clinical indications, as well as technical developments also must be carefully considered. This paper aims to elucidate the impact of these factors on the endovascular treatment, primarily with acrylic glue, of AVMs.

Methods

From 150 consecutive patients treated with embolization for cerebral AVMs during the period between 1987 and 1993, two groups were selected. Group I has 27 patients (13 male and 14 female) treated in 1987 and 1988. Group II has 35 patients (16 male and 19 female) treated in 1992 and 1993. These groups were defined to have a reasonable number of patients in each group with as much time as possible between the two treatment periods.

Most patients were referred by neurosurgeons or a few by neurologists at university hospitals in the referral area (approximately 15 million inhabitants). Most of the patients had been regarded as unsuitable candidates for surgery. After referral, all files and available films were studied and presented at a multidisciplinary conference (neurointerventional, neurosurgery, neurology, and neuroanesthesiology) before the patient was accepted for treatment. During the first period, all embolizations were performed by the senior author (P.S.) and during the second period

Received January 20, 1995; accepted after revision May 15, 1995.

From the Section for Interventional Neuroradiology, Department of Radiology (G.W., P.S.), and the Department of Neurology (C.L.), Sahlgrenska Hospital, Göteborg, Sweden.

Address reprint requests to Gunnar Wikholm, MD, Section for Interventional Neuroradiology, Department of Radiology, Sahlgrenska Hospital, S-41345 Göteborg, Sweden.

AJNR 16:1811–1817, Oct 1995 0195-6108/95/1609–1811

© American Society of Neuroradiology

about half by the same author and the other half by one junior author (G.W.). A number of patients presented at the conference were not treated. The reasons for treatment exclusions are presented in Table 1.

Measurements of the nidus on films were always corrected for magnification. Feeders and veins were not included in the lesion. Volumes were calculated as the product of three perpendicular diameters divided by 2 (16).

Technical Development

During the first period (1987 to 1988) the x-ray equipment was a single plane C-arm unit with fluoroscopy and a cut film changer. A digital unit with 512×512 matrix was added during the period. The initial catheters were very floppy pursil catheters injected through a propulsion chamber with or without calibrated leak balloons. Tracker (Target Therapeutics, Fremont, Calif) catheters were used after 1987. The embolization material was *N*-butyl-2-cyanoacrylate (NBCA, Histacryl Bleu, Melsungen AG, Germany) in 25 patients (in combination with polyvinyl alcohol [Ivalon, Ingenor, Paris, France] in 5 patients). Polyvinyl alcohol alone was used in 2 patients.

The same x-ray equipment mentioned above was used in the first months of the second period (1992 to 1993), but after November 1992, a new digital (1024×1024 matrix) single-plane C-arm unit with improved fluoroscopy and road mapping was used. During this period, the Magic catheter (Balt, Montmorency, France) was the sole catheter used in cerebral vessels. A Tracker catheter was used when meningeal feeders to a brain AVM were embolized. The embolization material during this period was NBCA in all but one patient in whom only polyvinyl alcohol was used and only in the external circulation.

Medical Treatment

In 1993, all patients regarded as being at increased risk for complications because of sudden hemodynamic changes induced by embolization were prophylactically treated with a special regimen. Patients selected for this regimen were those who had angiographic evidence of large shunts with vascular steal. The regimen included arterial pressure monitoring and blood pressure control with beta-blocking agents (metoprolol) aimed at a mean systemic arterial pressure of 70 to 80 mm Hg. The patients also received steroids (betamethasone) beginning with 8 mg with a phase-out schedule over 1 week. If signs of ischemic complication were observed, intravenous treatment with a calcium channel blocker (nimodipine, 10 to 20 mL/h) was initiated.

Aims and Strategy for Embolization

Our objective for treatment has, in all but a few instances, been the total occlusion of all shunts in the AVM to eliminate the risk of hemorrhage. In some patients, reduction of vascular steal has been the aim. Total occlusion has been achieved by embolization alone, but more

TABLE 1: Reasons for exclusion from treatment with embolization

	Group I (1987 to 1988)	Group II (1992 to 1993)
No reply to treatment offer	5	0
Patient declined embolization	3	3
Recommended for radiation	5	1
Complicated vascular anatomy	4	4
Old age	3	1
Total number excluded	20	9

TABLE 2: Comparison of a few parameters in the two groups treated with embolization

	Group I (1987 to 1988)	Group II (1992 to 1993)
Number of patients	27	35
Male/female	13/14	16/19
Age, y*	39 \pm 14, 8–66	33 \pm 17, 6–67
Left side AVM	59%	57%
Largest AVM diameter, mm*	41 \pm 16, 10–80	37 \pm 17, 10–90
AVM volume, mL*	27 \pm 28, 1–111	17 \pm 18, 1–74
AVM volume > 10 mL	70%	71%
Spetzler grade†	3.4 \pm 0.8	2.9 \pm 1
AVM involved eloquent area (Spetzler)	66%	77%

* Age, diameter, and volume given as mean \pm SD, range.

† Spetzler grade given as mean \pm SD.

often in combination with other modalities. We have mostly relied on gamma knife treatment for combined therapy. The radiation has been performed not in our hospital but at a national center.

Clinical Outcome

Each patient was clinically examined and interviewed by a neurologist at the end of the study. The same neurologist studied all files, making certain all complications of the treatment were considered in this evaluation. A complication is defined as a negative event occurring during treatment or within 4 weeks thereafter. Treatment complication grades are defined as *slight*, a definite clinical finding not impairing the patient's lifestyle; *moderate*, deficit with a minor influence on the patient's lifestyle; and *severe*, deficit with a marked influence on the patient's lifestyle. Most patients with a severe complication still are functioning independently. The definitions of the different categories of final outcome are *excellent*, patient returned to previous lifestyle without new deficit; *good*, patient returned to previous lifestyle but with a minor deficit; *fair*, because of a new deficit, patient could not return to previous lifestyle but could lead an independent life; *poor*, because of a new deficit, patient is dependent on others for daily living; *death from embolization*, death at or within 4

TABLE 3: Immediate outcome of embolization

	Group I (1987 to 1988) n = 27	Group II (1992 to 1993) n = 35
Total occlusion by embolization only	3 (11%)	7 (20%)
Patients accepted for radiation after embolization	5 (19%)	17 (49%)
Decreased symptoms, AVM not totally occluded	5 (19%)	3 (9%)
Increased risk of embolization or patient declined further embolization	9 (33%)	3 (9%)
Patients operated on after embolization	5 (19%)	4 (11%)
Other	0 (0%)	1 (3%)*

*Patient from abroad; treatment to continue in home country.

weeks of treatment; *death from AVM*, death caused by AVM activity more than 4 weeks after treatment; and *death from other cause*, non-AVM-related death. This closely follows the definitions used by Heros (17).

Results

The two groups have several factors in common (Table 2). The difference in mean volumes depends on a few very large AVMs in group I (111, 83, 80, and 78 mL) all being larger than the largest in group II. If the three largest are excluded, the volume figures for group I are 19 ± 17 mL (0.5 to 78).

The immediate results of the endovascular treatment are presented in Table 3. The outcomes were definitely better in group II. The category "Decreased symptoms, not totally occluded" contains patients with considerable reduction of neurologic symptoms, headache, epilepsy, or memory disturbance. Operations were performed as planned procedures in two instances in group I and in three in group II. Hemorrhage complicating embolization prompted emergency surgery in one patient in each group, and hemorrhage more than 4 weeks after embolization was the reason for surgery in two patients in group I.

Complications of embolization are presented in Table 4. Complications in group I were in two instances caused by hemorrhage during and in three instances caused by hemorrhage 1 to 4 days after embolization. On 10 occasions, the complication was attributable to an ischemic event from overflow of embolization material,

spasm, thrombosis, or expansive edema. The complications in group II were in two instances attributable to hemorrhage a few hours and 2 days after embolization, respectively. The remaining six were attributable to ischemic events.

Available angiographic follow-up for patients in whom eventual total obliteration of the AVM could be expected is presented in Table 5. The clinical outcomes also are presented.

The final clinical outcome is presented in Table 6. The patients in group I who died from AVM events had large malformations (61 to 80 mm largest diameter). There was one patient with grade 3, one patient with grade 4, and three patients with grade 5 AVMs, according to Spetzler's classification (18). Treatment attempts were made on these five patients before we realized that it would not be possible to occlude totally or decrease such AVMs to a size suitable for gamma knife treatment. Embolization did not significantly decrease AVM size except in one patient (50% reduction of size). In one patient, only polyvinyl alcohol embolization in the external circulation was performed. The patients died 3.5 ± 1.9 (0.5 to 5) years after embolization.

In terms of lesion size, the main difference in the two groups depends on AVMs with a diameter between 31 and 40 mm (Fig 1). The latter group would be expected to have a better outcome than the former group. It is of interest to determine whether the observed treatment improvements are valid for the larger AVMs as well. The results of this comparison are presented in Tables 7 through 10 and show that the improvement in outcome is valid for this group also.

No patient in either of the two groups with an AVM totally occluded by embolization alone or having been referred for gamma knife treatment has had any hemorrhage.

TABLE 4: Complications of embolization

Complication	Group I (1987 to 1988) n = 27	Group II (1992 to 1993) n = 35
None	13 (48%)	27 (77%)
Slight	7 (26%)	4 (11%)
Moderate	4 (15%)	4 (11%)
Severe	3 (11%)	0 (0%)
Death	0 (0%)	0 (0%)

TABLE 5: Angiographic follow-up and clinical outcome of patients in whom permanent obliteration of the AVM could be expected

	Group I (1987 to 1988)	Group II (1992 to 1993)
Total occlusion by embolization alone	Total number: 3 2 patients had 100% occlusion after 78 and 63 mo (angiography), 1 patient refused angiography	Total number: 7 6 patients had 100% occlusion at 11 ± 9 mo (range, 6–24) (angiography), 1 patient refused angiography
Clinical Outcome	3 excellent outcome	6 excellent, 1 good outcome
Combined treatment, embolization gamma knife treatment	Total number: 5 2 patients had 100% occlusion at 30 mo, 2 patients had 80% occlusion at 40 mo, 1 patient not angiographed (suicide)	Total number: 17 4 patients had 95% to 100% occlusion at 24 mo, 10 patients are waiting for 2-y angiography, 3 patients are accepted for but not yet radiated
Outcome	3 excellent, 1 good outcome, 1 committed suicide (good outcome from embolization)	15 excellent, 1 good, and 1 fair outcome
Combined treatment, embolization-surgery	Total number: 5 1 patient had no AVM left at 3 mo; 1 patient had most of AVM left at 12 mo, operated on because of SAH after embolization; 3 patients not angiographed	Total number: 4 2 patients had no AVM left at angiography after 1 and 6 mo, 2 patients not angiographed
Outcome	2 excellent, planned surgery 1 fair, natural course SAH* 1 poor, complication (SAH)† 1 dead, natural course SAH*	2 excellent, planned surgery 1 fair, complication (SAH)† 1 poor, planned surgery

* Subarachnoid hemorrhage (SAH) occurring more than 4 weeks after embolization.

† Subarachnoid hemorrhage occurring within 4 weeks after embolization.

TABLE 6: Clinical outcome at the end of the study

	Group I (1987 to 1988) n = 27	Group II (1992 to 1993) n = 35
Mean follow-up time, y	5.5	1.5
Excellent	11 (41%)	29 (83%)
Good	4 (15%)	2 (6%)
Fair	6 (22%)	3 (9%)
Poor	1 (4%)	1 (3%)
Death from embolization	0 (0%)	0 (0%)
Death from AVM hemorrhage	5 (19%)	0 (0%)

Discussion

Despite the fact that worldwide thousands of patients are being treated with embolization of cerebral AVMs, relatively few publications presenting the results of consecutive patient series have appeared in the literature (7, 19–21). Most publications present various subgroups and special problems. The present series is also selected. It consists of all patients treated during the first 2 and the last 2 years of a longer study.

Fig 1. AVM size in the two patient groups. The main difference in lesion diameter affects the middle group (31 to 40 mm).

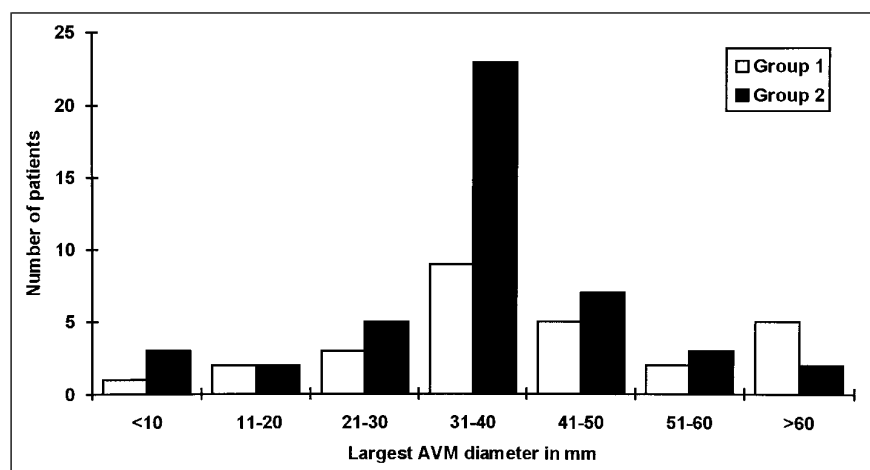


TABLE 7: Comparison of AVMs > 40 mm in the two groups

AVMs > 40 mm	Group I (1987 to 1988)	Group II (1992 to 1993)
Number	12	12
Largest diameter, mm*	56 ± 13 (42–80)	54 ± 14 (42–90)
Volume, mL*	47 ± 33 (8–111)	34 ± 20 (14–74)
	37 ± 25 (8–80)†	
Spetzler grade‡	3.7 ± 0.9	3.6 ± 0.8

*Mean ± SD, range.

† Volumes when two very large AVMs (111 and 83 mL) were excluded from group I.

‡ Mean ± SD.

TABLE 8: Complications of embolization in patients with AVMs larger than 40 mm

Complication	Group I (1987 to 1988)	Group II (1992 to 1993)
None	4 (33%)	8 (67%)
Slight	5 (42%)	2 (17%)
Moderate	2 (17%)	2 (17%)
Severe	1 (8%)	0 (0%)
Death	0 (0%)	0 (0%)
Total	12 (100%)	12 (100%)

The only objective of the selection has been to make it possible to study the effect of time on direct treatment results, complications of embolization, and final clinical outcome in one center.

The presented material shows that it has been possible for us to improve progressively the outcome for patients harboring an AVM, regarding both direct treatment results and the rate of complications. These results also seem to be valid for a group of large AVMs (>40 mm) (Tables 7 through 10), although this group is rather small.

The results regarding embolization complications and direct embolization outcome are final and, while the clinical results are not yet final, it will take several more years for the clinical outcomes to become final. The definitions of complications of treatment are vague. One reason is the problem of defining the patient's level of function in the acute hospital phase and during sick leave. Most deficits becoming apparent a few hours after embolization are transient, and function in these cases is often fully restored. So-called permanent deficits also are subject to restitution, as is the rule for many neurologic injuries (17).

TABLE 9: Result of endovascular treatment for AVMs > 40 mm

	Group I (1987 to 1988)	Group II (1992 to 1993)
Total occlusion by embolization only	0 (0%)	0 (0%)
Patients accepted for radiation after embolization	2 (17%)	5 (42%)
Decreased symptoms, not totally occluded	3 (25%)	3 (25%)
Increased embolization risk or patient declined further embolization	6 (50%)	2 (17%)
Patients operated on after embolization*	1 (8%)	1 (8%)
Other	0 (0%)	1 (8%)†
Total	12 (100%)	12 (100%)

* Patient in group I operated on because of a natural course hemorrhage. Patient in group II operated on because of hemorrhage as a complication of embolization.

† Patient to continue treatment in home country.

When comparing these results with others, one must keep in mind differences between study groups. AVMs suitable for gamma knife treatment are small; most centers accept no AVM larger than 3 cm or 10 mL, because the obliteration frequency is inversely correlated to AVM volume (22). Radiation treatment often is regarded as less traumatic to the patient, and few small AVMs are referred to us. Moreover, we usually refer those patients to a gamma knife center (Table 1). In group I, we had one patient and in group II, three patients with AVMs smaller than or equal to 10 mm. All of these were totally occluded (checked by angiography after 6 to 12 months) without complications and with an excellent clinical result.

Comparison with neurosurgical studies also is complicated, because most of our AVMs were referred by neurosurgeons who considered the lesions unsuitable for surgery because of size or location. When compared with the best neurosurgical series (which is representative for the person who has performed the surgery), our later results (group II) seem to be equally good regarding clinical outcome in a group of about equal surgical complexity (Spetzler grade) (14, 17, 23). There is an important difference, however: if angiography shows total extirpation of an AVM after surgery, the patient is regarded as being rid of the disease. It is hoped that the same is valid after total occlusion by embolization or embolization combined with gamma knife treatment. In 15 patients with AVMs totally

TABLE 10: Final clinical outcome for patients with AVMs > 40 mm

	Group I (1987 to 1988)	Group II (1992 to 1993)
Follow-up time, y	5	1
Excellent	3 (25%)	10 (83%)
Good	3 (25%)	1 (8%)
Fair	1 (8%)	1 (8%)
Poor	0 (0%)	0 (0%)
Death from embolization	0 (0%)	0 (0%)
Death from AVM event	5 (42%)	0 (0%)
Death from other cause	0 (0%)	0 (0%)
Total	12 (100%)	12 (100%)

occluded by embolization alone, followed with angiography for 5 to 45 months, occlusions were permanent and the clinical course stable (24). We still do not have many patients in whom total occlusion is verified by long-time follow-up with angiography. This fact leaves us open to criticism, of course. Another important point is what happens in the time interval between initiation of treatment and total occlusion. We do not have much data at present, but none of our patients with total occlusion through embolization or attainable in combination with gamma knife treatment has bled.

The difference in deaths from AVM events in our two groups could be partly the difference in follow-up time. All five patients in group I who eventually died had large, complicated AVMs. Only one of them was decreased in size by embolization. Another was embolized only with polyvinyl alcohol in the external carotid territory. Still, we are concerned about the high mortality and cannot exclude the possibility that embolization played a negative role in these patients. When reviewing patients with AVMs not totally occluded, Viñuela did not find any increased mortality (25). The follow-up time in that report was much shorter, though, and AVM is a "slow" disease with many years between hemorrhages (26). We hope that our poor results in this respect are a chance finding.

Despite differences in follow-up time, there has definitely been an improvement in the treatment results of AVMs over time, especially regarding complications of the treatment and the direct treatment outcome. All the proposed factors (technical development, medical treatment, and operator skill) probably have contributed to this evolution. It is not possible to separate their individual impact.

References

1. Luessenhop AJ, Spence WT. Artificial embolization of cerebral arteries: report of use in a case of arteriovenous malformation. *JAMA* 1960;172:1153-1155
2. Kricheff II, Madayag M, Braunstein P. Transfemoral catheter embolization of cerebral and posterior fossa arteriovenous malformations. *Radiology* 1972;103:107-111
3. Serbinenko FA. Balloon catheterization and occlusion of major cerebral vessels. *J Neurosurg* 1974;41:125-145
4. Kerber C. Intracranial cyanoacrylate: a new catheter therapy for arteriovenous malformations. *Invest Radiol* 1975;10(letter):536-538
5. Wolpert SM, Stein BM. Catheter embolization of intracranial arteriovenous malformations as an aid to surgical excision. *Neuroradiology* 1975;10:73-85
6. Dawson RC III, Tarr RW, Hecht ST, et al. Treatment of arteriovenous malformations of the brain with combined embolization and stereotactic radiosurgery: results after 1 and 2 years. *AJNR Am J Neuroradiol* 1990;11:857-864
7. Fournier D, Terbrugge KG, Willinsky R, Lasjaunias P, Montanera W. Endovascular treatment of intracerebral arteriovenous malformations: experience in 49 cases. *J Neurosurg* 1991;75:228-233
8. Benati A. Interventional neuroradiology for the treatment of inaccessible arteriovenous malformations. *Acta Neurochir (Wien)* 1992;118:76-79
9. Guo WY, Wikholm G, Karlsson B, Lindquist C, Svendsen P, Ericson K. Combined embolization and gamma knife radiosurgery for cerebral arteriovenous malformations. *Acta Radiol* 1993;34:600-606
10. Pelz DM, Fox AJ, Viñuela F, Drake CC, Ferguson GG. Preoperative embolization of brain AVMs with isobutyl-2 cyanoacrylate. *AJNR Am J Neuroradiol* 1988;9:757-764
11. Purdy PD, Samson D, Batjer HH, Risser RC. Preoperative embolization of cerebral arteriovenous malformations with polyvinyl alcohol particles: experience in 51 adults. *AJNR Am J Neuroradiol* 1990;11:501-510
12. Viñuela F, Dion JE, Duckwiler G, et al. Combined endovascular embolization and surgery in the management of cerebral arteriovenous malformations: experience with 101 cases. *J Neurosurg* 1991;75:856-864
13. Spetzler RF, Martin NA, Carter LP, et al. Surgical management of large AVMs by staged embolization and operative excision. *J Neurosurg* 1987;67:17-28
14. Hamilton MG, Spetzler RF. The prospective application of a grading system for arteriovenous malformations. *Neurosurgery* 1994;34:2-7
15. Nakstad PH, Nornes H. Superselective angiography, embolization and surgery in treatment of arteriovenous malformations of the brain. *Neuroradiology* 1994;36:410-413
16. Pasqualin A, Barone G, Cioffi F, Rosta L, Scienza R, Da Pian R. The relevance of anatomic and hemodynamic factors to a classification of cerebral arteriovenous malformations. *Neurosurgery* 1991;28:370-379
17. Heros RC, Korosue K, Diebold PM. Surgical excision of cerebral arteriovenous malformations: late results. *Neurosurgery* 1990;26:570-577
18. Spetzler RF, Martin NA. A proposed grading system for arteriovenous malformations. *J Neurosurg* 1986;65:476-483
19. Lasjaunias P, Manelfe C, Terbrugge K, Lopez Ibor L. Endovascular treatment of cerebral arteriovenous malformations. *Neurosurg Rev* 1986;9:265-275
20. Merland JJ, Rufenacht D, Laurent A, Guimaraens L. Endovascular treatment with isobutyl cyanoacrylate in patients with arteriovenous malformation of the brain: indications, results and complications. *Acta Radiol Suppl* 1986;369:621-622

21. Berthelsen B, Löfgren J, Svendsen P. Embolization of cerebral arteriovenous malformations with bucrylate. *Acta Radiol* 1990; 31:13-21
22. Steiner L, Lindquist C, Steiner M. Radiosurgery. In: Symon L, ed. *Advances and Technical Standards in Neurosurgery*. Vienna: Springer-Verlag; 1992:19-102
23. Hernesniemi J, Keranen T. Microsurgical treatment of arteriovenous malformations of the brain in a defined population. *Surg Neurol* 1990;33:384-390
24. Wikholm G. Occlusion of cerebral arteriovenous malformations with N-butyl cyano-acrylate is permanent. *AJNR Am J Neuroradiol* 1995;16:479-482
25. Viñuela F, Fox AJ, Pelz D, Debrun G. Angiographic follow-up of large cerebral AVMs incompletely embolized with isobutyl-2-cyanoacrylate. *AJNR Am J Neuroradiol* 1986;7:919-925
26. Ondra SL, Troupp H, George ED, Schwab K. The natural history of symptomatic arteriovenous malformations of the brain: a 24-year follow-up assessment. *J Neurosurg* 1990;73:387-391