



Get Clarity On Generics

Cost-Effective CT & MRI Contrast Agents



FRESENIUS
KABI

WATCH VIDEO

AJNR

Intracarotid blood pressure changes during contrast medium injection.

H Saitoh, K Hayakawa, K Nishimura, Y Okuno, C Murayama, T Miyazawa, B F Zieroth and Y Shimizu

AJNR Am J Neuroradiol 1996, 17 (1) 51-54

<http://www.ajnr.org/content/17/1/51>

This information is current as
of August 11, 2025.

Intracarotid Blood Pressure Changes during Contrast Medium Injection

Hidekazu Saitoh, Katsumi Hayakawa, Kazumasa Nishimura, Yoshishige Okuno, Chie Murayama, Tomoaki Miyazawa, Bernhart F. Zieroth, and Yoshihiko Shimizu

PURPOSE: To investigate changes in blood pressure during intracarotid injection of contrast material. **METHODS:** Two catheters were inserted into the ipsilateral common carotid artery of dogs. The proximal catheter was used for injection of contrast material and the other was positioned distally to monitor blood pressure. **RESULTS:** Distal intracarotid pressure rose significantly during injection of contrast material at all rates (5, 7, and 10 mL/s) and at all doses (0.2, 0.5, 0.7, and 1.0 mL/kg). In addition, these blood pressure elevations were shown to be correlated with injection rates and doses. Even when the pressure-monitoring coaxial catheter was advanced into smaller arteries, no decline in the impact of injection was observed. **CONCLUSION:** Intracarotid injection of contrast material causes a temporal elevation of cerebral blood pressure in dogs.

Index terms: Cerebral angiography, contrast media; Contrast media, effects; Animal studies

AJNR Am J Neuroradiol 17:51-54, January 1996

Although cerebral angiography is necessary for the early diagnosis of ruptured intracranial aneurysm, reruptures associated with the angiographic procedure have been reported as a serious complication (1-3). This study has a close bearing on the subject of whether early cerebral angiography within 6 hours after subarachnoid hemorrhage should or should not be performed. In a recent study (1) of 42 cases of subarachnoid hemorrhage, two aneurysms (5%) reruptured as a result of angiography within 6 hours after the initial episode, which is close to the rate of spontaneous rerupture within 6 hours. We therefore believe that early angiography, which enables early surgical treatment, should not necessarily be discouraged. However, the intracarotid pressure changes during injection of contrast material have not fully been documented. One report (4) claimed that the

injection of contrast material causes no pressure changes in humans. Nevertheless, in addition to the fact that aneurysms have been reported to rerupture during injections, we sometimes experience reflux of contrast material into the posterior circulation, suggesting elevation of intracarotid blood pressure (Fig 1).

The objectives of this study were to investigate whether standard injections of contrast material elevate intracarotid pressure and, if so, how much the increase in intracarotid pressure depends on the injection flow rate, the dose injected, and the size of the artery.

Materials and Methods

Protocol 1

First, we investigated the relationship between blood pressure changes and injection rate and dose of contrast material in 14 adult mongrel dogs (average weight of about 10 kg; range, 8 to 13 kg). Each animal was premedicated with 0.5 mg of atropine sulfate intramuscularly followed by intravenous pentobarbital sodium (25 to 30 mg/kg body weight) for general anesthesia. Intratracheal intubation was performed. A 5F to 6F short sheath was inserted into the femoral arteries for a 5F injection catheter (Anthrion, Headhunter type, Toray, Tokyo) on one side and a 5F or 5.5F pressure-monitoring catheter (Anthrion, Straight type, Toray, Tokyo) on the other. Systemic blood pressure was monitored constantly via the sheath and every trial was carried out while systemic blood pressure

Received February 23, 1995; accepted after revision July 10.

From the Department of Radiology, Kyoto City Hospital, Kyoto, Japan (H.S., K.H., K.N., Y.O.); the Department of Research, Nihon Shering KK, Kyoto, Japan (C.M., T.M., B.F.Z.); and the Research Center for Biomedical Engineering, Kyoto University, Kyoto, Japan (Y.S.).

Address reprint requests to Hidekazu Saitoh, MD, Department of Radiology, Kyoto City Hospital, 1-2 Higashi-takada-cho, Mibu, Nakagyo-ku, Kyoto 604, Japan.

AJNR 17:51-54, Jan 1996 0195-6108/96/1701-0051

© American Society of Neuroradiology

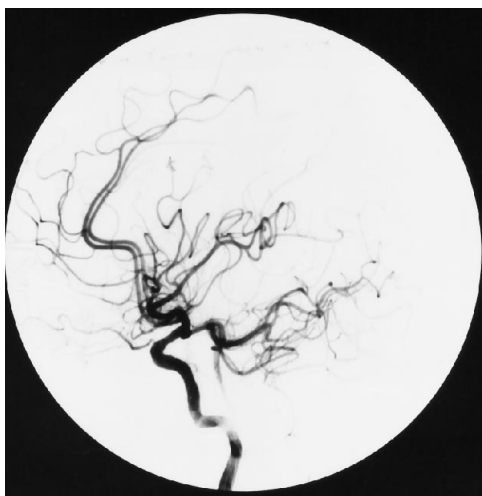

Fig 1. Angiogram shows reflux of contrast medium into the basilar artery during internal carotid angiography. This patient had no stenosis of the vertebral and subclavian arteries.

was stable. The injection catheter tip was placed at the C5-6 level in the common carotid artery and the monitoring catheter tip was placed at the ipsilateral mid C-2 level in the common carotid artery. An automatic power injector (Contrac 4E, Siemens, Germany) was used for the injection of contrast material.

Intracarotid pressure changes and their durations were monitored with a fixed injection dose (0.5 mL/kg) and different injection rates (5, 7, and 10 mL/s). We also monitored pressure changes and durations at a fixed injection rate of 5 mL/s and at different injection doses (0.2, 0.5, 0.7, and 1.0 mL/kg). Two different contrast agents, 300 mg I/mL iopamidol (Iopamiron, Schering, Germany) and 320 mg I/mL meglumine/sodium ioxaglate (Hexabrix, Guerbet, France), plus saline were used as injection materials. The viscosities of Iopamiron 300, Hexabrix 320, and saline are about 4.4 cp, 7.5 cp, and 0.7 cp, respectively.

We recorded the pressure measurements by pulse mode using a multichannel recorder (Rectigraph-8K, NEC-Sanei, Japan). We defined blood pressure change (mm Hg) as the difference between the average of the preinjection systolic blood pressure and the maximal elevation during injection (Fig 2). Duration (in seconds) was defined as the sum of the periods when the blood pressure was higher than the average preinjection systolic blood pressure. The results are expressed as mean \pm 1 SD, and differences between them were analyzed using the one-sample and the two-sample *t* tests. Differences at *P* values of less than .05 were considered significant.

Protocol 2

These experiments were conducted in five beagle dogs (average weight of about 10 kg; range, 8 to 12 kg) to determine whether blood pressure changes depend on artery size. The procedure was the same as described above,

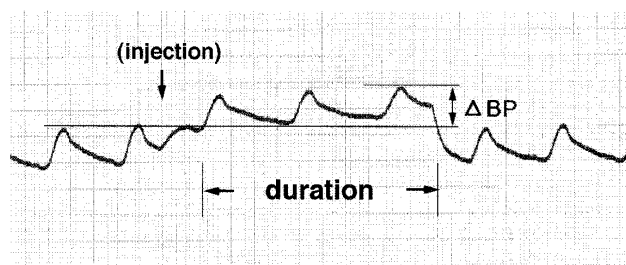


Fig 2. Graph depicts measurements of intracarotid blood pressure recorded by pulse mode. Blood pressure elevation (ΔBP) and its duration are shown during and after injection (arrows).

except for the use of a 2F coaxial pressure-monitoring catheter (Mikro-tip catheter, Millar Instruments, Inc, Houston, Tex), which has an ultraminiature pressure sensor at its distal end. Blood pressure measuring sites were at the C-2 level in the common carotid artery, the proximal and distal (as far as possible) portions of the external carotid artery, and, if possible, the proximal and distal portions of the internal carotid artery (Fig 3). Injection rate and dose of contrast material were fixed at 5 mL/s and 0.5 mL/kg. Analysis of variance was used to statistically analyze the results.

An important technical matter is how the blood pressure changes in small arteries were measured. When coaxial catheters were displaced or wedged by the impact of the injection, we could not get correct measurements. The Mikro-tip catheter, which has a pressure sensor at the tip, was better in this regard than the other coaxial catheters,

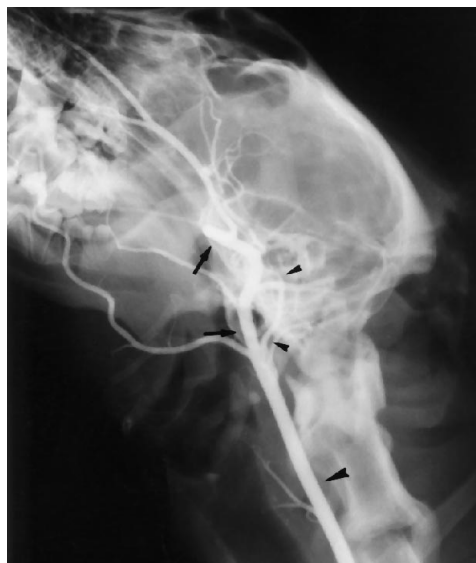

Fig 3. Carotid angiogram in a dog. Blood pressure monitoring sites are at the C-2 level in the common carotid artery (large arrowhead), the proximal and distal portions of the external carotid artery (arrows), and, when possible, the proximal and distal portions of the internal carotid artery (small arrowheads). In dogs, the internal carotid artery is very small compared with the external carotid artery.

TABLE 1: Injection Rate and Change in Blood Pressure, mean \pm 1 SD, mm Hg

	Injection Rate, mL/s		
	5.0	7.0	10.0
loxaglate	58.3 \pm 29.4 (n = 14)	85.7 \pm 42.2 (n = 7)	...
lopamidol	53.6 \pm 25.5 (n = 7)	77.9 \pm 33.8 (n = 7)	125.3 \pm 46.8 (n = 6)
Saline	41.8 \pm 21.7 (n = 7)	64.9 \pm 26.8 (n = 7)	...

which have no built-in sensor. Only data from properly positioned and nonwedged catheters were analyzed.

Results

At a constant injection dose of 0.5 mL/kg, intracarotid contrast medium and saline injections at all rates (5, 7, and 10 mL/s) caused statistically significant ($P < .05$) blood pressure elevation (41.8 to 125.3 mm Hg) at the distal carotid site (Table 1). When iopamidol was injected, the change in blood pressure was greater ($P < .05$) at 10 mL/s than at 5 mL/s. The duration of blood pressure changes ranged from 0.91 to 1.32 seconds (Table 2). Because the injection dose was constant, faster rates required less injection time. The duration of blood pressure elevation at 10 mL/s was less ($P < .05$) than it was at 5 and 7 mL/s.

At a constant injection rate of 5 mL/s, all doses of intracarotid contrast medium and saline (0.2, 0.5, 0.7, and 1.0 mL/kg) produced statistically significant ($P < .05$) blood pressure elevations (22.4 to 77.4 mm Hg) (Table 3). Ioxaglate doses of 0.5 and 0.7 mL/kg caused a greater change in blood pressure ($P < .05$) than did the 0.2 mL/kg dose. Duration of blood pressure elevation ranged from 0.47 to 2.73 sec-

onds (Table 4). All larger doses resulted in significantly ($P < .05$) longer durations.

All data from the last experiment in relation to artery size and changes in blood pressure are shown in Table 5. Mean lumen diameters of the common carotid arteries at the C-2 level, the proximal and distal external carotid arteries, and the proximal and distal internal carotid arteries were 4.0, 3.4, 3.1, 1.8, and 1.0 mm (about 100%, 85%, 78%, 45%, and 25% of the lumen diameter at the injection site), respectively. Using analysis of variance ($P < .05$), we found significant differences in blood pressure changes among certain dogs, but no significant differences in blood pressure changes among the arteries.

All local blood pressure changes were independent of systemic blood pressure because simultaneous monitoring showed no systemic blood pressure change during injections. We also confirmed that there was no vasospasm or catheter (injection or measuring) wedging during injections by observing both forward and backward free flow of contrast material fluoroscopically as well as by certifying the pulse mode, which would have become flat if the catheter tip were wedged. Therefore, the system

TABLE 2: Injection Rate and Duration of Change in Blood Pressure, mean \pm 1 SD, seconds

	Injection Rate, mL/s		
	5.0	7.0	10.0
loxaglate	1.27 \pm 0.32 (n = 14)	1.21 \pm 0.17 (n = 7)	...
lopamidol	1.32 \pm 0.28 (n = 7)	1.16 \pm 0.13 (n = 7)	0.91 \pm 0.11 (n = 6)
Saline	1.15 \pm 0.32 (n = 7)	1.00 \pm 0.16 (n = 7)	...

TABLE 3: Injection Dose and Change in Blood Pressure, mean \pm 1 SD, mm Hg

	Injection Dose, mL/kg			
	0.2	0.5	0.7	1.0
loxaglate	22.0 \pm 17.4 (n = 6)	58.3 \pm 29.4 (n = 14)	86.3 \pm 41.2 (n = 7)	...
lopamidol	...	53.6 \pm 25.5 (n = 7)	66.4 \pm 26.4 (n = 7)	77.4 \pm 34.3 (n = 6)
Saline	...	41.8 \pm 21.7 (n = 7)	49.8 \pm 14.5 (n = 7)	...

TABLE 4: Injection Dose and Duration of Change in Blood Pressure, mean \pm 1 SD, seconds

	Injection Dose, mL/kg			
	0.2	0.5	0.7	1.0
Ioxaglate	0.47 \pm 0.20 (n = 6)	1.27 \pm 0.32 (n = 14)	2.23 \pm 0.23 (n = 7)	...
Iopamidol	...	1.32 \pm 0.28 (n = 7)	1.91 \pm 0.16 (n = 7)	2.73 \pm 0.37 (n = 6)
Saline	...	1.15 \pm 0.32 (n = 7)	1.78 \pm 0.28 (n = 7)	...

TABLE 5: Monitor Sites and Change in Blood Pressure, mm Hg, at a Constant Injection Rate and Dose

	Dog A	Dog B	Dog C	Dog D	Dog E
Distal CCA	24	32	26	52	50
Proximal ECA	24	24	32	56	62
Distal ECA	18	26	46	64	68
Proximal ICA	20	28	...	64	62
Distal ICA	24	74

Note.—CCA = common carotid artery, ECA = external carotid artery, ICA = internal carotid artery.

was open to pressure gradients proximally as well as distally, so the gradients were rapidly dissipated.

Discussion

It has been important for angiographers to know whether intracarotid injections of contrast material cause significant blood pressure elevation in patients with ruptured intracranial aneurysms, whose rerupture carries a high mortality rate (1). Such determinations are not easy, because cerebral blood flow changes are complicated by the interaction of many factors, including artery size and branching, peripheral anastomoses, the circle of Willis, autoregulation, pulsation, blood viscosity, and so forth.

Saline injections raise pressure less than contrast material does, presumably because viscosities of contrast media are much higher than that of saline. Therefore, according to Poiseuille's law, an automatic power injector needs a more forceful injection in the case of contrast medium than in the case of saline to maintain the same flow rate. Although in vivo studies are desirable, only a few studies on the effect of contrast injections on cerebral arteries have been reported. Lin et al (5) reported elevation of carotid artery blood pressure during retrograde brachial angiography in humans. In a study with

Doppler sonography in humans, Stoeter et al (6) also reported an increase in both internal and external carotid blood flow during cerebral angiography.

On the basis of these reports and our own findings, we believe that the pressure effects of contrast injections can easily be transmitted along the cervical portion of the carotid artery. In addition, our study showed a positive correlation between blood pressure changes and injection rate and dose of contrast material. Furthermore, the changes in blood pressure did not decrease, even in the distal internal carotid artery of the dog, which is a rather minor branch compared with the external carotid artery (about 1 mm in diameter). These findings suggest that standard injection rates and doses of contrast material could also cause some elevation of intracranial blood pressure in humans. Whether these pressure changes are significant enough to recommend a change in technique when investigating the cause of subarachnoid hemorrhage is a subject for further investigation.

References

1. Saitoh H, Hayakawa K, Nishimura K, et al. Rerupture of cerebral aneurysms during angiography. *AJNR Am J Neuroradiol* 1995;16:539-542
2. Arthur BD, Barry NF. Cerebral aneurysm rupture during angiography with confirmation by computed tomography. *Surg Neurol* 1980;13:19-26
3. Itoh S, Kwak R, Emori T, et al. Risk factors of cerebral aneurysm rerupture during angiography (in Japanese with English abstract). *No Shinkei Geka* 1986;13:399-407.
4. Iwasaki S, Taoka T, Nakagawa H, Fukusumi A, Ohishi H, Uchida H. Intracranial arterial pressure change during contrast material injection in carotid angiography (abstr). *Radiology* 1993;189(P):401
5. Lin JP, Kricheff II, Chase NE. Blood pressure changes during retrograde brachial angiography. *Radiology* 1964;83:640-646
6. Stoeter P, Prey N, Hoffmann C, Budingen HJ, Bergleiter R. Doppler sonographic examination of the arterial flow in the carotid and supratrochlear arteries during carotid angiography. *Neuroradiology* 1984;26:199-207