

Generic Contrast Agents

Our portfolio is growing to serve you better. Now you have a *choice*.



FRESENIUS
KABI

[VIEW CATALOG](#)

AJNR

Cystic papillary adenocarcinoma of the submandibular gland in a child.

E J Czarnecki, E M Spickler, M Keohane and W Roennecke

AJNR Am J Neuroradiol 1996, 17 (6) 1038-1040

<http://www.ajnr.org/content/17/6/1038>

This information is current as
of May 29, 2025.

Cystic Papillary Adenocarcinoma of the Submandibular Gland in a Child

Edward J. Czarnecki, Eric M. Spickler, Mary Keohane, and Werner Roennecke

Summary: A 12-year-old boy reported that a mass in his left jaw had been growing slowly for 8 months. Axial and coronal contrast-enhanced spiral CT showed a 5-cm cystic mass within an enhancing, mildly enlarged left submandibular gland. Excisional biopsy revealed a cystic papillary adenocarcinoma of the left submandibular gland, very rare in children.

Index terms: Carcinoma; Children, neoplasms; Salivary glands, neoplasms

Malignant tumors of the salivary gland are rare in children (1). We report the spiral computed tomography (CT) findings of an unusual case of cystic papillary adenocarcinoma of the submandibular gland in a child.

Case Report

A 12-year-old boy had a 2-month history of a left-sided jaw mass that was slowly increasing in size. Physical examination by his pediatrician revealed a soft, mobile, 4-cm lesion within the region of the left submandibular triangle. The patient was afebrile, and his white blood cell count was normal. The pediatrician thought that the mass was most likely related to lymph node enlargement and placed the patient on antibiotics. The patient was referred to an oral surgeon, who found no odontogenic source of infection, and the patient was lost to follow-up. Approximately 6 months later he was seen by an otorhinolaryngologist.

At this time, the patient stated that the mass had been slowly increasing in size over the last 8 months. He reported no fever or significant pain related to the mass. Physical examination revealed a soft, slightly tender, 5-cm mass centered in the left submandibular triangle and two small lymph nodes. Laboratory evaluation showed the white blood cell count to be within normal limits. The patient was referred for contrast-enhanced CT examination. Axial and coronal contrast-enhanced spiral CT scans revealed a 5-cm cystic mass within an enhancing, mildly enlarged left submandibular gland. The adjacent fascial planes were indistinct. Also visible were unenlarged lymph nodes in the left submandibular triangle, the internal jug-

ular chain bilaterally (level 3), and the left posterior triangle (level 5) (Fig 1A and B).

An excisional biopsy was done of the left submandibular gland and the two small lymph nodes of the submandibular triangle. Histologic examination of the biopsy specimen revealed a cystic papillary adenocarcinoma of the left submandibular gland (Fig 1C). The tumor extended to the biopsy margins. Since remaining tumor could not be confidently excluded, another operation was performed with a wide local excision and dissection of the lymph nodes in the upper part of the neck, which showed no evidence of residual or metastatic tumor. No adjunctive therapy was pursued.

Discussion

Salivary gland tumors in children are extremely rare (1). However, the likelihood that a salivary gland mass is malignant is much greater in children than it is in adults. Approximately 35% of salivary gland masses in children are malignant. The vast majority of childhood salivary gland masses occur in the parotid gland, with 10% occurring in the submandibular gland and less than 5% occurring within the minor salivary glands. Hemangiomas of the parotid gland account for 50% of all salivary gland masses in children. These lesions are usually diagnosed within the first 2 years of life. Excluding hemangiomas, the most common tumors include mucoepidermoid carcinomas and pleomorphic adenomas and lymphangiomas, followed by acinic cell carcinomas, undifferentiated carcinomas, adenocarcinomas, and adenoid cystic carcinomas (2). Other malignant tumors occurring in the salivary glands include squamous cell carcinomas, sarcomas, lymphomas, and metastatic neuroblastomas. Autoimmune inflammatory masses and chronic sialoadenitis can mimic malignant tumors of the

Received July 24, 1995; accepted after revision October 16.

From the Departments of Diagnostic Radiology (E.J.C., E.M.S.), Pathology (M.K.), and Otorhinolaryngology (W.R.), Henry Ford Hospital, Detroit, Mich.

Address reprint requests to Eric M. Spickler, Department of Diagnostic Radiology, Division of Neuroradiology, 2799 W Grand Blvd, Detroit, MI 48202.

AJNR 17:1038-1040, Jun 1996 0195-6108/96/1706-1038 © American Society of Neuroradiology

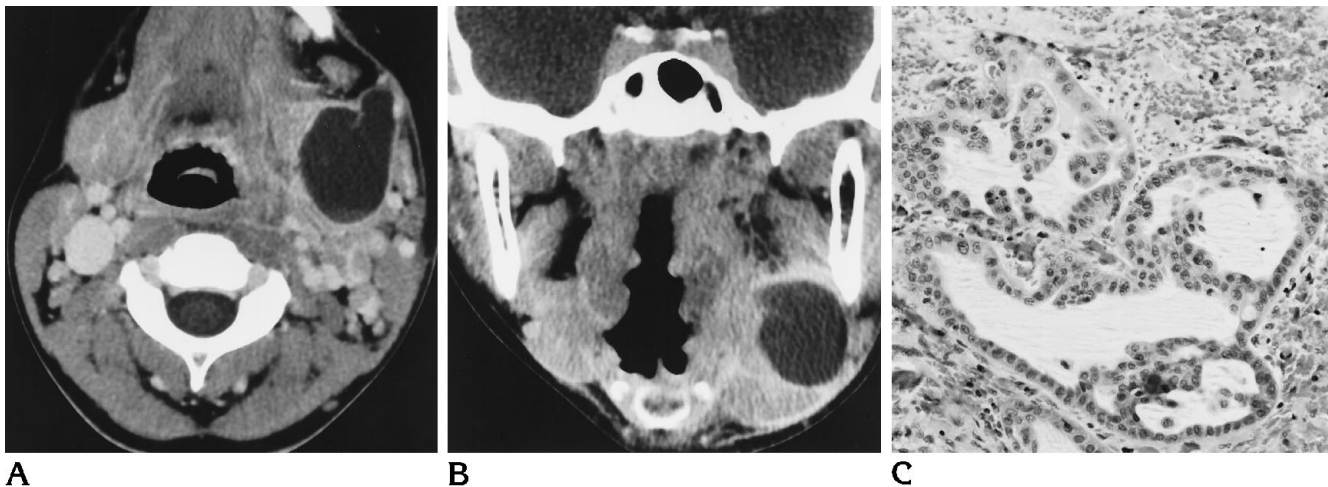


Fig 1. Twelve-year-old boy with an 8-month history of a slowly growing mass in the left side of the jaw.

A, Axial contrast-enhanced spiral CT scan at the level of the submandibular space shows an irregular, 5-cm cystic mass arising from the left submandibular gland. Marginal enhancement is present. The carotid sheath structures are displaced posteriorly. Unenlarged lymph nodes are visible in the left submandibular triangle, left posterior triangle, and mid-internal jugular chain bilaterally.

B, Coronal contrast-enhanced spiral CT scan shows the mass abutting the mandible without invasion of the bone. Fat stranding is seen in the left parapharyngeal space.

C, Photomicrograph shows an infiltrating glandular structure lined by cuboidal epithelium with cribriforming, indicative of papillary adenocarcinoma (hematoxylin-eosin stain).

salivary gland. Sialolithiasis with sialoceles formation is rare in children.

Most neck masses in children are benign. These include congenital lesions, such as hemangiomas, branchial cleft cysts, and lymphangiomas, or acquired infectious lymph node enlargement. Malignant neck lesions in children are most often leukemic/lymphomatous tumors, and the next most common are rhabdomyosarcomas and salivary gland tumors.

Clinical and laboratory evaluation is often inconclusive in determining the origin of a neck mass. Clinical features such as pain, rapid growth, firmness, or lymph node enlargement should alert the physician to the possibility of malignancy. However, slow growth and lack of symptoms do not necessarily imply a benign lesion, as evidenced by this case.

Contrast-enhanced CT and magnetic resonance (MR) imaging are the examinations of choice for evaluating mass lesions of the salivary glands and neck. Imaging is important for verifying the presence of a mass; determining its relationship to the salivary gland and adjacent structures; determining whether the mass is well circumscribed or infiltrating; ascertaining whether it is solid, necrotic, or cystic in nature; and discovering whether there is bilateral disease and lymph node enlargement (3). Imaging characteristics of submandibular malignant lesions include an irregular and poorly defined

border, heterogeneous internal structure, invasion of surrounding tissues, and lymph node metastases (4). Although these findings are suggestive of malignancy, they are nonspecific. The previously mentioned benign neck masses, including hemangioma, branchial cleft cyst, lymphangioma, and reactive lymph node enlargement, can exhibit these characteristics if complicated by infection or hemorrhage. Malignant salivary gland tumors can be solid, cystic, or necrotic. Macroscopic calcification and hemorrhage are rare.

Salivary gland adenocarcinomas are extremely rare in children. They are morphologically diverse tumors that continue to pose problems in classification. Most can be identified as solid, papillary, or mucinous in appearance. Prognosis in adults is related to the histologic grade of the tumor (5). Given the small number reported in children, there is insufficient information to assign prognostic criteria except to say that infiltrating lesions or those that appear in conjunction with metastatic disease do poorly.

Although rare, a significant proportion of major salivary gland tumors in children are malignant. Neck masses in children should be evaluated with contrast-enhanced CT or MR imaging. If a lesion is shown to arise from a major salivary gland, the differential consideration of a malignant tumor of the salivary gland

should be raised so that the appropriate intervention can be pursued.

References

1. Batsakis JG. *Tumors of the Head and Neck*. 2nd ed. Baltimore, Md: Williams & Wilkins; 1979:1-75
2. Rasp G, Permanetter W. Malignant salivary gland tumors: squamous cell carcinoma of the submandibular gland in a child. *Am J Otolaryngol* 1992;13:109-112
3. Som PM, Bergeron RT. *Head and Neck Imaging*. 2nd ed. St Louis, Mo: Mosby; 1991:288-289
4. Yasomoto M, Shiboya H, Suzuki S, et al. Computer tomography and ultrasonography in submandibular tumors. *Clin Radiol* 1992; 46:114-120
5. Spiro RH, Huvos AG, Strong EW. Adenocarcinoma of salivary origin: clinicopathologic study of 204 patients. *Am J Surg* 1982; 144:423-431