

# Generic Contrast Agents

Our portfolio is growing to serve you better. Now you have a *choice*.



FRESENIUS  
KABI

[VIEW CATALOG](#)

# AJNR

## **MR of recurrent high-grade astrocytomas after intralesional immunotherapy.**

M M Smith, J E Thompson, M Castillo, S Cush, S K Mukherji, C H Miller and K B Quattrocchi

*AJNR Am J Neuroradiol* 1996, 17 (6) 1065-1071

<http://www.ajnr.org/content/17/6/1065>

This information is current as  
of May 24, 2025.

# MR of Recurrent High-Grade Astrocytomas after Intralesional Immunotherapy

Michelle M. Smith, Jill E. Thompson, Mauricio Castillo, Sharon Cush, Suresh K. Mukherji, Claramae H. Miller, and Keith B. Quattrocchi

**PURPOSE:** To describe the MR findings in six patients with recurrent cerebral astrocytomas before, immediately after, and 3 months after local immunotherapy with tumor-infiltrating lymphocytes and interleukin-2. **METHODS:** Contrast-enhanced MR studies were obtained in six patients (three with anaplastic astrocytoma and three with glioblastoma multiforme) at the time of tumor recurrence, after a second resection and placement of an Ommaya catheter, at the end of immunotherapy, and thereafter at 3-month intervals. These MR studies were reviewed with special attention to pattern and degree of enhancement, edema, and mass effect. **RESULTS:** In three patients, gross total removal of recurrent tumor was achieved and postimmunotherapy MR studies showed a flare phenomenon characterized by increased nodular enhancement, increased edema, and mass effect. On the 3-month follow-up examination, these findings had resolved, and no further tumor recurrence was seen during the following 12-month period. Neither of the two patients who had subtotal resection had a flare phenomenon. In one of these patients, the tumor was stable at the 12-month follow-up; the other patient had recurrent tumor at the 6-month follow-up. In the last patient, who also had subtotal tumor resection and progressive enhancement after immunotherapy, tumor progression was rapid. **CONCLUSION:** After local immunotherapy, increased enhancement, edema, and mass effect are most likely the result of a flare phenomenon, but because rapid tumor progression may produce similar features, follow-up MR studies are indispensable. The flare phenomenon resolved by 3 months in all patients.

**Index terms:** Astrocytoma; Brain neoplasms, magnetic resonance; Immunotherapy

*AJNR Am J Neuroradiol* 17:1065–1071, June 1996

High-grade astrocytomas generally respond poorly to surgery, radiation therapy, and chemotherapy. Median survival time for patients with these tumors ranges from 37 to 60 weeks, with a 90% mortality rate 2 years after diagnosis (1, 2). Recurrent tumor occurs locally, usually within 2 to 3 cm of the original surgical resection. In view of this poor response to conventional therapies, augmentation of the host's immune response to tumor through cellular adoptive immunotherapy has the potential to improve the chances of survival. Adoptive im-

muno-therapy with autologous lymphokine activated killer (LAK) cells or tumor-infiltrating lymphocytes (TILs) has been shown to be successful in treating patients with widely metastatic solid tumors, including renal cell carcinoma and melanoma (3, 4). There is evidence supporting the idea of regional immunotherapy for treatment of malignant cerebral astrocytomas (2, 5). Although cellular immune function may be suppressed in patients with malignant astrocytomas, peritumoral lymphocytic infiltrates are present, and increased density correlates with improved prognosis (2, 6). Both LAK cells and TILs have been expanded in vitro and used for regional immunotherapy of malignant astrocytomas (7–9). A combination of TILs and interleukin-2 (aldesleukin) therapy appears to modify further the host's immune system and to increase the likelihood of tumor regression.

We present the MR imaging findings in six patients who, after gross total resection of tu-

---

Received November 2, 1995; accepted after revision January 23, 1996.

From the Department of Radiology (M.M.S., J.E.T., M.C., S.K.M.) and the Division of Neurosurgery (S.C., C.H.M., K.B.Q.), University of North Carolina School of Medicine, Chapel Hill.

Address reprint requests to M. Castillo, MD, Department of Radiology, CB 7510, 3324 Old Infirmary, Chapel Hill, NC 27599.

*AJNR* 17:1065–1071, Jun 1996 0195-6108/96/1706-1065

© American Society of Neuroradiology

Intralesional immunotherapy data for six patients with recurrent astrocytoma

Patient	Age, y/Sex	Diagnosis	Type of Resection	Flare Response on MR Study Immediately after Immunotherapy?	Follow-up MR Findings after Immunotherapy
1	35/F	L frontal anaplastic astrocytoma	Gross total resection	yes	No recurrence at 15 mo
2	47/M	R temporal glioblastoma multiforme	Subtotal resection	yes	Stable at 18 mo
3	70/F	R frontoparietal glioblastoma multiforme	Gross total resection	yes	No recurrence at 13 mo
4	41/F	L frontal glioblastoma multiforme	Gross total resection	yes	No recurrence at 4 mo
5	30/M	L temporal anaplastic astrocytoma	Gross total resection	no	No recurrence at 12 mo
6	48/F	L temporal anaplastic astrocytoma	Subtotal resection	no	Tumor recurrence at 7 mo

mors and chemotherapy/irradiation, had tumor recurrence and underwent a second resection and placement of an Ommaya catheter through which TILs were administered.

## Subjects and Methods

Our study group included two men and four women, 30 to 70 years old, three with malignant cerebral astrocytomas (anaplastic astrocytoma) and three with glioblastoma multiforme. In all patients, serial contrast-enhanced magnetic resonance (MR) imaging studies obtained at 3-month intervals showed progressive tumor growth within 1 year after primary surgical resection and chemotherapy (intraarterial cisplatin, carmustine [BCNU], and procarbazine) and external-beam irradiation (5940 cGy over 7 weeks).

Before TILs and interleukin-2 therapy, all patients gave written consent as dictated by our Institutional Review Board. Exclusion criteria for this therapy included coagulopathy; granulocytopenia; impaired immune function not attributable to a malignant lesion in the central nervous system; severe cardiac, pulmonary, or renal dysfunction; and pregnancy. All patients had a repeat craniotomy with the goal of gross total resection of recurrent tumor and for placement of an Ommaya catheter with its tip in the surgical bed. The catheter was connected to a reservoir located subcutaneously (over the craniotomy site) to facilitate infusion of TILs and interleukin-2. Tumor specimens were separated into three parts: one was used for TILs production, one for tumor culture and in vitro TILs culture stimulation, and one was frozen for future in vitro studies. Patients were eligible for in vitro TILs treatment 8 weeks after surgery if more than  $4 \times 10^9$  cells were expanded. The sequence of MR studies was dictated by a larger brain tumor treatment protocol being held at our institution in which these six patients were initially enrolled. A baseline postoperative contrast-enhanced MR study was obtained before immunotherapy (8 weeks after the second surgery). The treatment schedule consisted of biweekly infusions of  $1 \times 10^9$  TILs and infusions of a maximally tolerated dose of interleukin-2 (between  $1 \times 10^5$  IU per dose and  $1.2 \times 10^6$  IU per dose every Monday, Wednesday, and Friday) for a 4-week period, during which the patients

remained hospitalized. None of our patients received steroids, as these may have adverse effects on the desired inflammatory response in the tumor bed.

Outcome assessments by means of contrast-enhanced MR studies and neurologic examinations were made at the conclusion of immunotherapy, at 6 weeks, and thereafter at 3-month intervals. All MR studies consisted of sagittal and axial noncontrast T1-weighted images (500/16/1 [repetition time/echo time/excitations]), axial T2-weighted images (2300/20–80/1), and immediate post-contrast (0.1 mmol/kg) coronal and axial T1-weighted images obtained with the above parameters. All studies were done using two different 1.5-T units. Retrospective, subjective analysis of all images was done independently by four neuroradiologists (differences resolved by consensus) with special attention to degree of enhancement, size of the lesion, amount of surrounding T2 signal abnormalities, and mass effect.

## Results

In three of our patients, a comparison of MR studies obtained before placement of the Ommaya catheter with those obtained 2 to 3 months earlier showed progressive enhancement, edema, and mass effect, compatible with recurrent tumor (Table). All recurrent tumors were located in the frontal lobes (two on the left side, one on the right); one was an anaplastic astrocytoma and the other two were glioblastoma multiforme. In all three patients, MR studies obtained 8 weeks after the second surgery, after successful expansion of TILs and before TILs/interleukin-2 therapy, showed near-total resolution of previous findings, compatible with gross tumor resection. Repeat MR contrast-enhanced studies obtained at the end of the TILs/interleukin-2 4-week treatment period showed significantly increased, irregular, and nodular contrast enhancement along the margins of the surgical bed, increased perilesional T2 signal intensity compatible with edema, and mass ef-

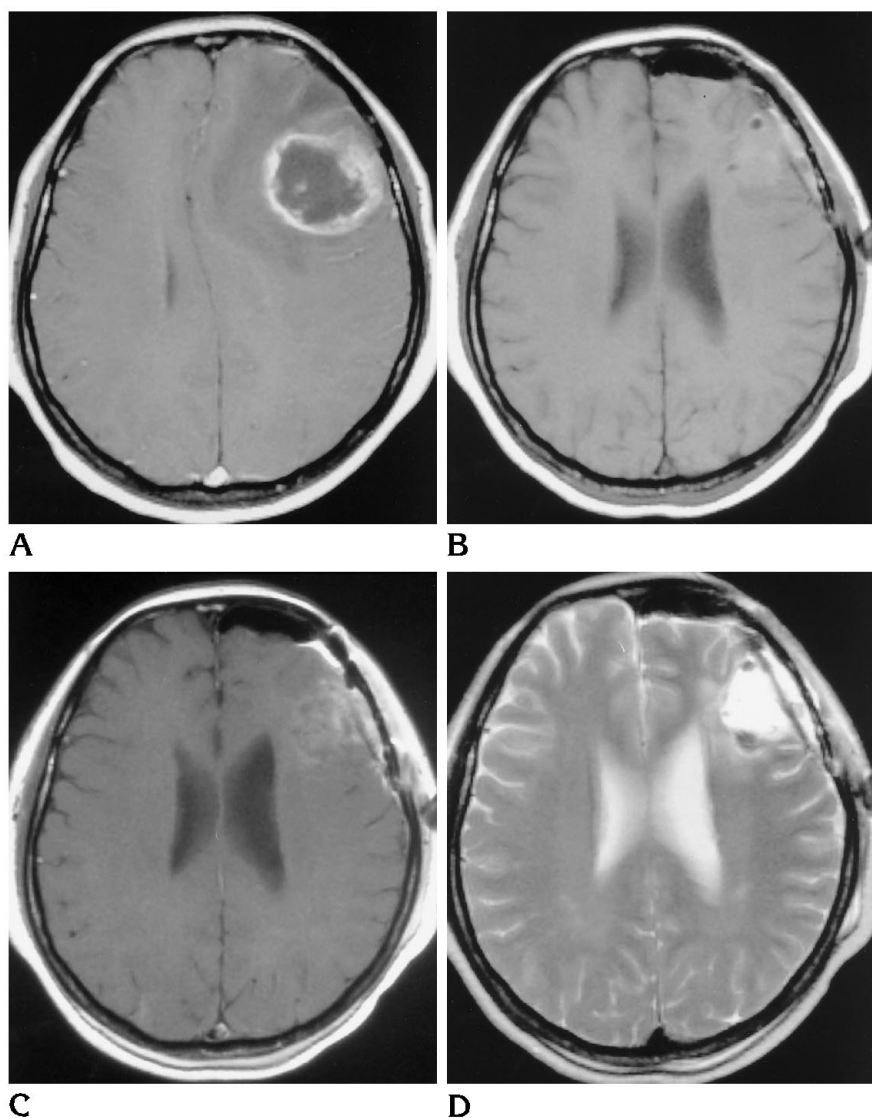


Fig 1. Case 4: flare phenomenon with resolution after immunotherapy.

A, Postcontrast T1-weighted MR image shows irregular ring-enhancing lesion in left frontal lobe and surrounding edema with mass effect compatible with recurrent glioblastoma multiforme.

B, Precontrast T1-weighted MR image 8 weeks after second resection and placement of Ommaya catheter shows subtle hyperintensity in surgical bed (blood?).

C, Corresponding postcontrast T1-weighted MR image shows mild enhancement in surgical bed and dura under the craniotomy.

D, Corresponding T2-weighted image shows hyperintensity in surgical bed and small extraaxial fluid collection under the craniotomy. (*Figure continues.*)

fect upon neighboring structures (Fig 1A-F). On the second 3-month follow-up contrast-enhanced MR study after the conclusion of TILs/interleukin-2 therapy, all MR abnormalities had resolved (Fig 1G and H). All subsequent follow-up MR studies, up to 15 months after immunotherapy, have shown no further tumor recurrence.

In two patients, recurrent glioblastoma multiforme and anaplastic astrocytoma (left and right temporal lobes) were resected for a second time and an Ommaya catheter was placed. Subtotal tumor resection was performed in one patient after the second surgery, and the MR study after the 4-week course of immunotherapy showed unchanged contrast enhancement and edema (Fig 2A-C). Follow-up MR studies

up to 12 months after immunotherapy showed decreased lesion size (Fig 2D). In the second patient, a postsurgical contrast-enhanced MR study showed no significant change in the degree of enhancement/edema as compared with the previous MR study, because only partial resection was accomplished owing to the location of the mass. An MR study obtained after TILs/interleukin-2 therapy showed no change in the lesion. The most recent MR study, obtained 6 months after immunotherapy, showed progression of the tumor.

In the last patient, the MR study obtained before placement of the Ommaya catheter showed recurrence of a right temporal glioblastoma multiforme (Fig 3A). Subtotal tumor resection was accomplished during the second

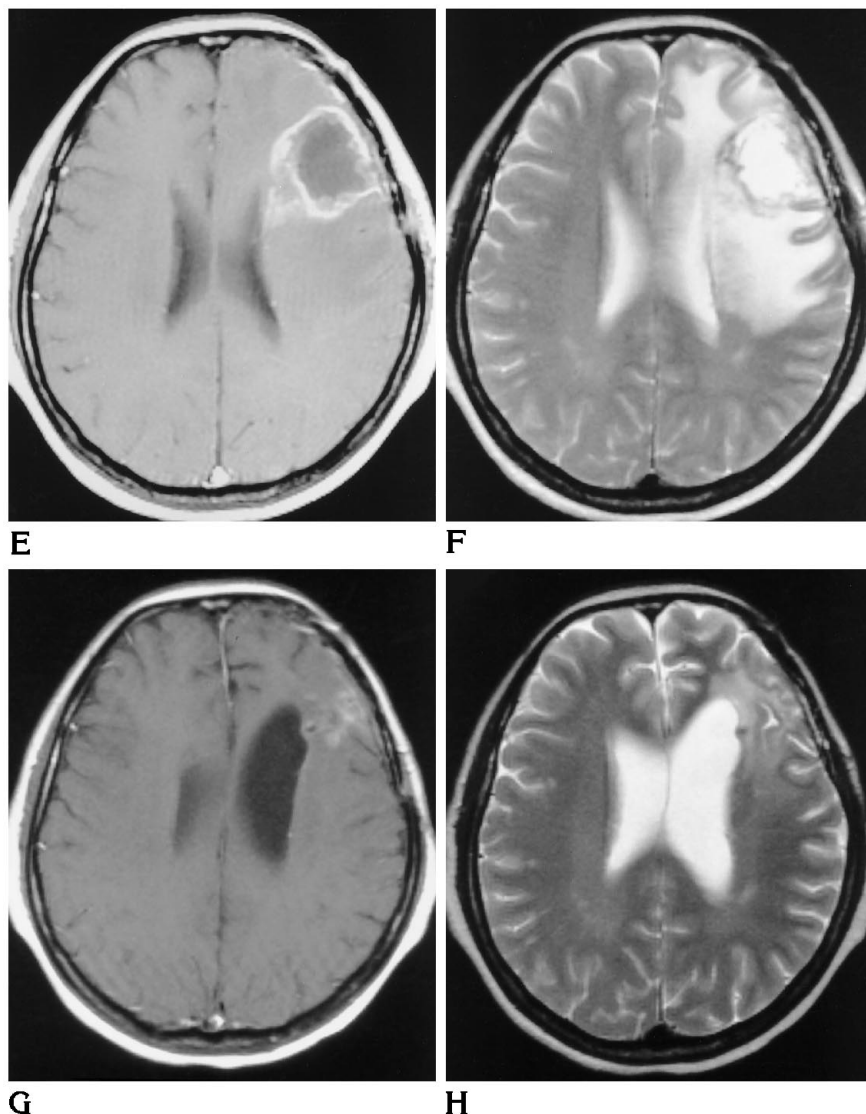
Fig 1, *continued*.

*E*, Postcontrast T1-weighted MR image (comparable level to *B* through *D*) obtained at end of 4-week immunotherapy period shows considerable ring enhancement at surgical site. There is no mass effect.

*F*, Corresponding T2-weighted image shows lesion with considerable increased signal intensity in surrounding white matter but comparably little mass effect.

*G*, Postcontrast T1-weighted MR image at similar level but obtained 3 months after completion of immunotherapy shows almost complete resolution of abnormality with residual enhancement, indicating that previous abnormality was most likely due to flare phenomenon resulting from immunotherapy. Note absence of mass effect and compensatory dilatation of left lateral ventricle.

*H*, Corresponding T2-weighted image shows marked resolution of white matter signal abnormalities and loss of tissue volume at surgical site.



surgery (Fig 3B). The MR study obtained after TILs/interleukin-2 therapy showed increased masslike enhancement in the surgical bed in addition to surrounding edema and midline shift to the left (Fig 3C). The last MR study available in this patient was obtained 3 months after immunotherapy and showed marked tumor progression with involvement of the contralateral cerebral hemisphere via corpus callosum extension (Fig 3D). This patient has declined further follow-up studies.

## Discussion

Immunotherapy regimens can have a significant impact on advanced cancer in some patients. Initially, high-dose interleukin-2 therapy

was used to modify the host's immune system and to induce tumor regressions (1). Later studies showed that LAK cells in combination with interleukin-2 could be adoptively transferred in large numbers for cancer therapy (2). Recently, TILs have been isolated from tumors and expanded in culture in the presence of interleukin-2 for systemic adoptive immunotherapy (3, 4). TILs appear to have important advantages over LAK cells in the treatment of malignant tumors. TILs are 50 to 100 times more cytotoxic to autologous tumors than LAK cells (3, 9, 10). TILs are also highly specific, owing to the requirement that tumor antigen fragments be complexed with specific classes of major histocompatibility proteins (11-14). TILs offer advantages in terms of research aimed at under-

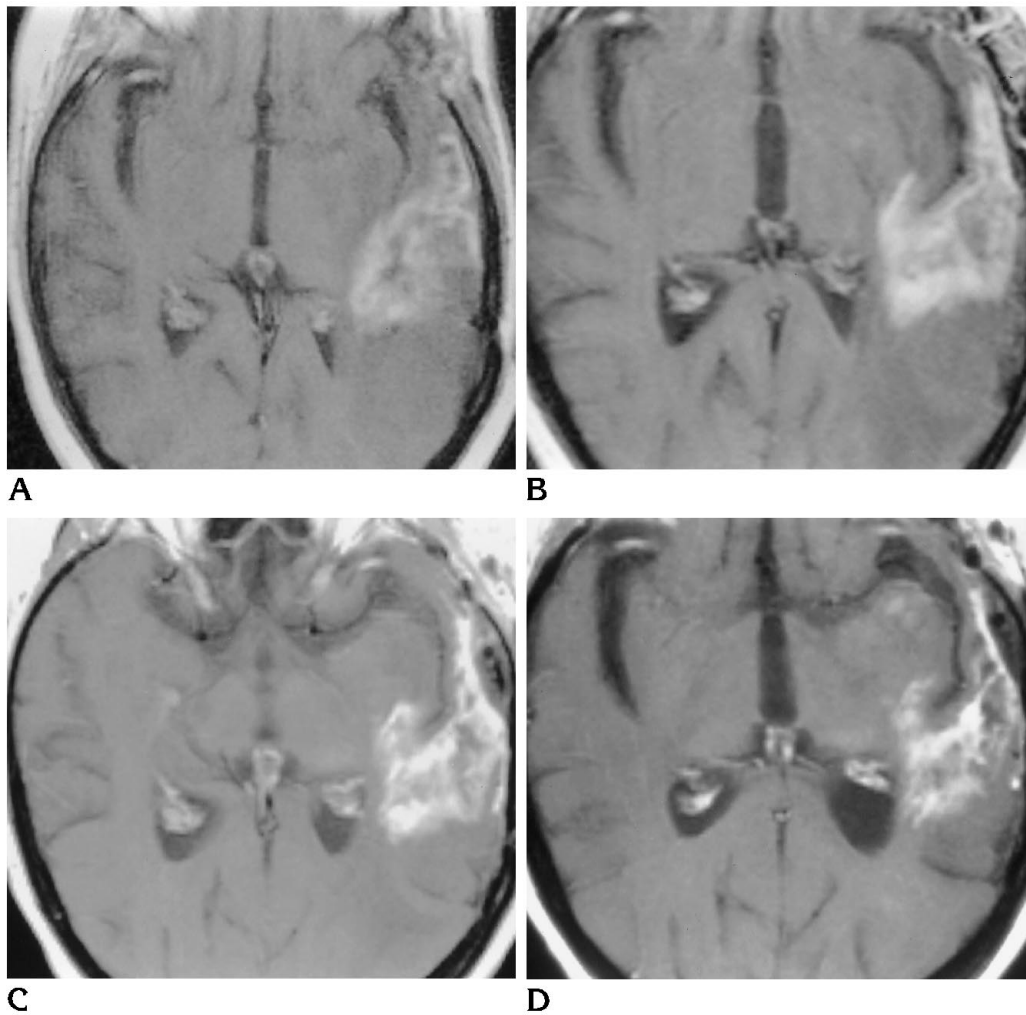


Fig 2. Case 6: absence of flare phenomenon after immunotherapy.

A, Axial postcontrast T1-weighted MR image shows recurrent enhancing left temporal glioblastoma multiforme 6 months after initial surgery.

B, Axial postcontrast T1-weighted MR image in a similar plane as A but 8 weeks after second surgery and placement of Ommaya catheter. Because of fear of significant postsurgical neurologic deficits, only a minimal tumor resection was feasible. The enhancing lesion is almost identical in appearance to that in A.

C, Axial postcontrast T1-weighted MR image at similar level as A and B but after 4-week immunotherapy period shows enhancing left temporal lesion basically unchanged (no flare).

D, Postcontrast T1-weighted MR image 3 months after immunotherapy shows decreased size, enhancement, and mass effect from left temporal lesion. There are two questionable areas of enhancement in the anterior aspect of the left temporal lobe.

standing the mechanisms of oncogenesis and antigenicity of malignant cerebral astrocytomas (15). In a clinical trial using tumor-stimulated lymphocytes for treatment of malignant astrocytomas, two of five patients who received intratumoral injections of  $10^8$  to  $10^9$  cells had more than a 50% reduction in tumor burden (9). Adoptive immunotherapy is usually administered in combination with interleukin-2, as the latter appears to be necessary for maintenance of cellular cytotoxicity.

Imaging studies in the six patients in our study displayed the spectrum of MR findings in response to intralesional immunotherapy with TILs and interleukin-2. In four patients treated with TILs/interleukin-2, MR findings showed apparent worsening in the tumor regions immediately after completion of immunotherapy. Three of the four patients with this flare response had gross total tumor resection, and follow-up MR studies showed reduction in the size of the lesions after immunotherapy. Two of these three

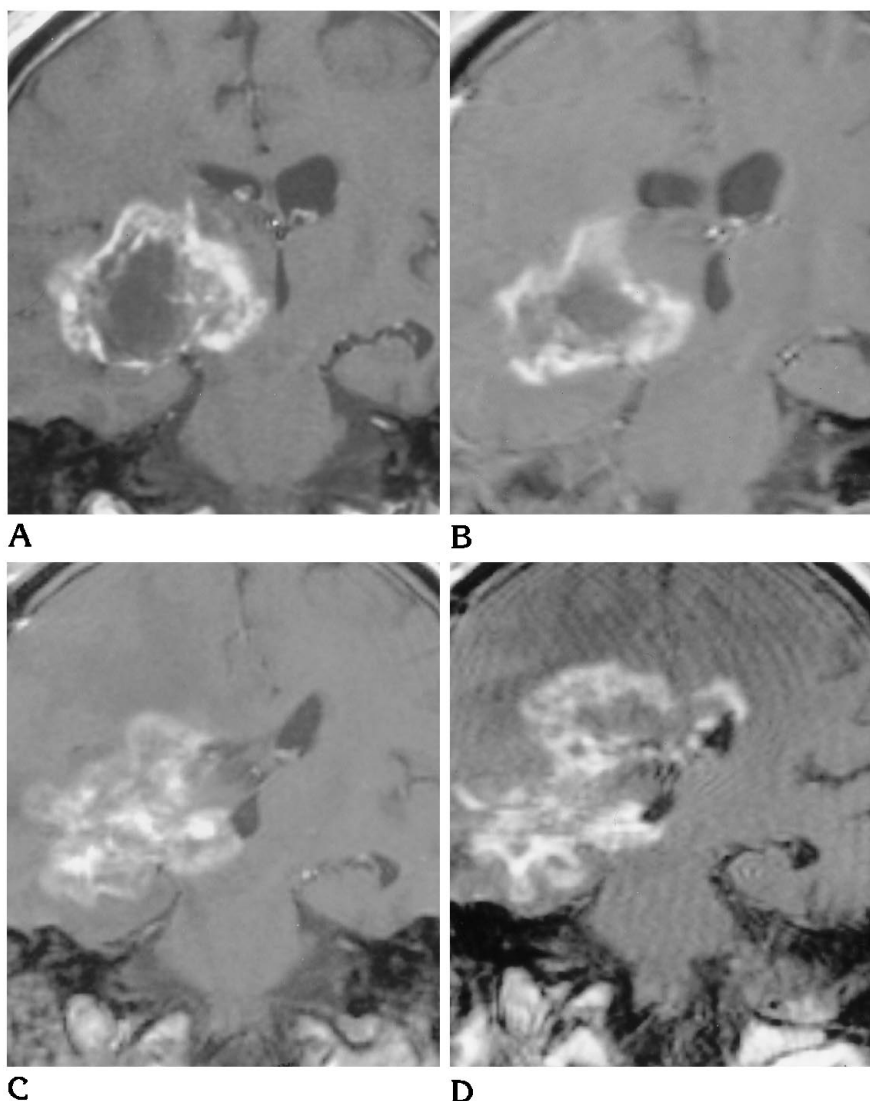
Fig 3. Case 2: progressive tumor despite immunotherapy.

A, Coronal postcontrast T1-weighted MR image shows recurrent tumor in right temporal lobe 8 months after initial surgery. The initial histologic finding was anaplastic astrocytoma.

B, Coronal postcontrast T1-weighted MR image at similar level as A 8 weeks after second tumor resection and placement of Ommaya catheter shows enhancing residual abnormality (tumor?) in right temporal region. Note that size of lesion is slightly smaller than in A and there is less mass effect upon third ventricle.

C, Postcontrast T1-weighted MR image at similar level as A and B after 4-week immunotherapy period. There is increased size, enhancement, and mass effect of lesion. Note early involvement of right lateral ventricle. On the basis of this study it is not possible to determine whether findings are related to flare phenomenon or tumor progression.

D, Coronal postcontrast T1-weighted MR image 3 months after C shows significant extension of lesion to lateral ventricles and across corpus callosum, compatible with tumor progression. Further treatment was not deemed beneficial and the illness was considered terminal.



are considered to be in remission and are now off all therapy, and the third patient is completing a final course of adjuvant chemotherapy. The fourth patient who had a flare response had subtotal tumor resection and rapid progression of tumor after immunotherapy. Two of the patients who were treated with immunotherapy had no flare response.

The purpose of this article is not to assess the response of cerebral astrocytomas to TILs/interleukin-2 therapy but rather to report our initial posttreatment MR findings, which we hope will serve as baseline for future studies. Note that considerable clinical improvement was seen only in those cases in which the second surgery achieved gross total tumor resection in combination with immunotherapy. On the basis of our findings, we propose that worsening of

the MR findings after immunotherapy may represent a flare response in these patients and should not be assumed to imply progression or recurrence of tumor. Because the flare response was seen to resolve rapidly on follow-up MR studies (3 months in our patients), we believe it may be related to peritumoral inflammation resulting from cytolytic activity of the infused lymphocytes against the tumor. Local side effects (of which the flare response is one) documented in patients with metastatic disease to the brain treated with immunotherapy include induction of capillary leak syndrome, induction of marked lymphocytic infiltration, and elaboration of cytokines in response to interleukin-2 (16). There have been some suggestions that the presence of this inflammatory response may be a favorable prognostic sign (17). It is

possible that patients with this type of response will fare better eventually.

Flare responses should disappear by 3 months, and persistent enhancement should be regarded as highly suggestive of tumor progression, as was the case in one of our patients. The two patients who were treated with TILs/interleukin-2 but who did not have a flare response have had different clinical courses; one has had tumor remission (at least partial) and is stable 12 months after immunotherapy, the other has had tumor progression, remains on a chemotherapy regimen, and was considered terminally ill at the time of this writing. In our last patient, increased enhancement, edema, and mass effect were documented after immunotherapy, and because follow-up studies showed rapid tumor progression, it is unclear whether the initial findings are related to flare phenomenon, tumor recurrence, or a combination of both. Because all our patients had recurrent tumors, we cannot comment on the postimmunotherapy appearance of new tumors.

In summary, worsening of the MR findings after TILs/interleukin-2 therapy may be due either to a flare phenomenon or to tumor progression. Alterations in patient treatment during the initial 3 months after intralesional therapy should be made with caution. In our patients, the flare effect resolved 3 months after therapy while true tumor progression did not. Some patients did not have a flare response. Although preliminary data suggest that patients with a positive flare response may have a better prognosis, further studies are needed to prove this observation.

## References

1. Green SB, Byar DP, Walker MD, et al. Comparisons of carmustine, procarbazine, and high-dose methylprednisolone as additions to surgery and radiotherapy for the treatment of malignant gliomas. *Cancer Treat Rep* 1983;67:121-132
2. Meischer S, Whaiteside TL, de Tribolet N, von Fleidner V. In situ characterization, clonogenic potential and antitumor cytolytic activity of a T-lymphocyte clone derived from a patient with gliosarcoma. *J Neurosurg* 1988;69:751-759
3. Rosenberg SA. The adoptive immunotherapy of cancer using the transfer of activated lymphoid cells and interleukin-2. *Semin Oncol* 1986;13:200-206
4. Rosenberg SA, Packard BS, Aebersold PM, et al. Use of tumor infiltrating lymphocytes and interleukin-2 in the immunotherapy of patients with metastatic melanoma: a preliminary report. *N Engl J Med* 1988;319:1676-1680
5. Apuzzo MLJ, Mitchell MS. Immunological aspects of intrinsic glial tumors. *J Neurosurg* 1981;55:1-18
6. Brooks WH, Marksbery WR, Gupta GD, et al. Relationship of lymphocyte invasion and survival of brain tumor patients. *Ann Neurol* 1978;4:219-224
7. Barba D, Saris SC, Holder CC, Rosenberg SA, Oldfield EH. Intratumoral LAK cell and interleukin-2 therapy of human gliomas. *J Neurosurg* 1989;70:175-180
8. Merchant RE, Merchant LH, Cook SHS, McViciar DW, Young HF. Intralesional infusion of lymphokine-activated killer (LAK) cells and recombinant interleukin-2 (IL-2) for the treatment of patients with malignant brain tumor. *Neurosurgery* 1988;23:725-731
9. Kitahara T, Osama W, Yamaura A, et al. Establishment of an IL-2 dependent cytotoxic T-cell line specific for autologous brain tumor and its intratumoral administration for therapy of the tumor. *J Neurooncol* 1992;4:329-336
10. Rosenberg SA, Lotze M, Yang J, et al. Experience with the use of high-dose interleukin-2 in the treatment of 652 cancer patients. *Ann Surg* 1989;210:474-485
11. Rosenberg SA, Lotze M, Muul L, et al. A progress report on the treatment of 157 patients with advanced cancer using lymphokine-activated killer cells and interleukin-2 or high-dose interleukin-2 alone. *N Engl J Med* 1987;316:889-897
12. Muul L, Speiss E, Rosenberg SA. Identification of specific cytolytic responses against autologous tumor in human beings bearing malignant melanoma. *J Immunol* 1987;138:989-995
13. Topalian S, Solomon D, Rosenberg SA. Tumor-specific autolysis by lymphocytes infiltrating human melanomas. *J Immunol* 1989;142:3714-3725
14. Monaco J. A model of MHC class-I restriction of antigen processing. *Immunol Today* 1992;13:173-179
15. Boon T. Towards a genetic analysis of tumor rejection antigens. *Adv Cancer Res* 1992;58:179-210
16. Chang AE, Shu S. Immunotherapy with sensitized lymphocytes. *Cancer Invest* 1992;10:357-369
17. Vose BM, Moore M. Human tumor-infiltrating lymphocytes: a marker of host response. *Semin Hematol* 1985;22:27-40