

Generic Contrast Agents

Our portfolio is growing to serve you better. Now you have a *choice*.



FRESENIUS
KABI

[VIEW CATALOG](#)

AJNR

Dural arteriovenous fistula at the craniocervical junction with perimedullary venous drainage.

M Mascalchi, F Scazzari, D Prosetti, G Ferrito, F Salvi and N Quilici

AJNR Am J Neuroradiol 1996, 17 (6) 1137-1141

<http://www.ajnr.org/content/17/6/1137>

This information is current as
of May 27, 2025.

Dural Arteriovenous Fistula at the Craniocervical Junction with Perimedullary Venous Drainage

Mario Mascalchi, Fabio Scazzari, Daniele Prosetti, Giampiero Ferrito, Fabrizio Salvi, and Nello Quilici

Summary: MR imaging showed swelling and diffuse signal changes in the spinal cord in two patients with progressive myelopathy. MR angiography revealed slow-flow perimedullary vessels extending to the skull base, which are consistent with drainage vessels of a dural arteriovenous fistula at the craniocervical junction. This fistula was subsequently seen in both patients on selective arteriograms of the ascending pharyngeal and vertebral arteries.

Index terms: Fistula, arteriovenous; Skull, base; Spinal cord, myelopathy

Dural arteriovenous fistulas at the craniocervical junction may be accompanied by progressive myelopathy caused by drainage into perimedullary veins (1–8). Diagnosis of this uncommon type of dural arteriovenous fistula may be challenging; in fact, findings at myelography and magnetic resonance (MR) imaging resemble those of spinal dural arteriovenous fistulas, and results of spinal arteriography are negative (3, 7).

MR angiography is a useful complement to MR imaging in the evaluation of spinal vascular lesions (9). We describe two patients with progressive myelopathy in whom findings at MR imaging and MR angiography were suggestive of a dural arteriovenous fistula at the craniocervical junction.

Case Report

Case 1

A 69-year-old man with a history of head trauma at age 25 underwent MR imaging of the thoracolumbar spine at 0.5 T because of paresthesias in the lower limbs, urinary retention, and progressive gait disturbance, beginning 4 years earlier. The neurologic examination showed moderate paraparesis, bilateral foot drop, clonus of the ankles, and global hypesthesia below T-9. The upper and midtho-

racic portions of the spinal cord were mildly enlarged and showed diffuse, increased signal intensity on spin density-weighted and T2-weighted MR images below T-3 (Fig 1A). The conus medullaris was spared. After intravenous injection of gadopentetate dimeglumine (0.1 mmol/kg), tiny, faintly enhanced perimedullary serpiginous structures were noted. After injection of an additional 0.2 mmol/kg of contrast material, MR angiography of the thoracic spine was performed with the use of a two-dimensional phase contrast technique (9). Only the image modulus was reconstructed. Sagittal acquisitions of a 15-mm-thick section with low (6 cm/s) flow-encoding velocity along the craniocaudal, anteroposterior, and left-right flow axis showed an abnormally enlarged serpiginous vessel posterior to the area of intramedullary signal change (Fig 1B). The vessel had a median position in coronal acquisitions. Selective arteriography of all the spinal vascular pedicles below T-3 failed to detect abnormal intraspinal vessels. MR examination of the cervical spine at 0.5 T showed mild scalloping of the posterior surface of the cord. Triple-dose contrast-enhanced MR angiography of the cervical spine performed with a two-dimensional phase-contrast technique showed that the median retromedullary serpiginous vessel had reached the skull base (Fig 1C and D). Selective arteriography of the craniocervical arteries (Fig 1E–G) showed a dural arteriovenous fistula at the inner outlet of the left condylar channel that was fed by the left ascending pharyngeal artery and by a meningeal branch of the left vertebral artery, and drained into a retromedullary vein. With a posterior upper cervical approach, the intradural vein draining the fistula was clipped and excised. The patient improved after surgery.

Case 2

A 53-year-old man had a 2-year history of pain in the lower limbs, progressive gait difficulty, and paresthesias in the right hand. The neurologic examination showed spastic tetraparesis, weakness of the right leg, diffusely increased deep tendon reflexes, bilateral clonus of the ankles, and Lhermitte sign. MR imaging of the cervical spine at 0.5 T showed spondylotic changes at C-5 and swelling

Received July 11, 1995; accepted after revision October 24.

From the Cattedra di Radiologia, Università di Pisa (M.M.), the Department of Neuroradiology, Ospedali Riuniti, Livorno (F.Sc., D.P., G.F., N.Q.), and the Division of Neurology, Ospedale Bellaria, Bologna (F.Sa.), Italy.

Address reprint requests to Mario Mascalchi, MD, PhD, Cattedra di Radiologia, Università di Pisa, Via Roma 67, 56126 Pisa, Italy.

AJNR 17:1137–1141, Jun 1996 0195-6108/96/1706-1137 © American Society of Neuroradiology

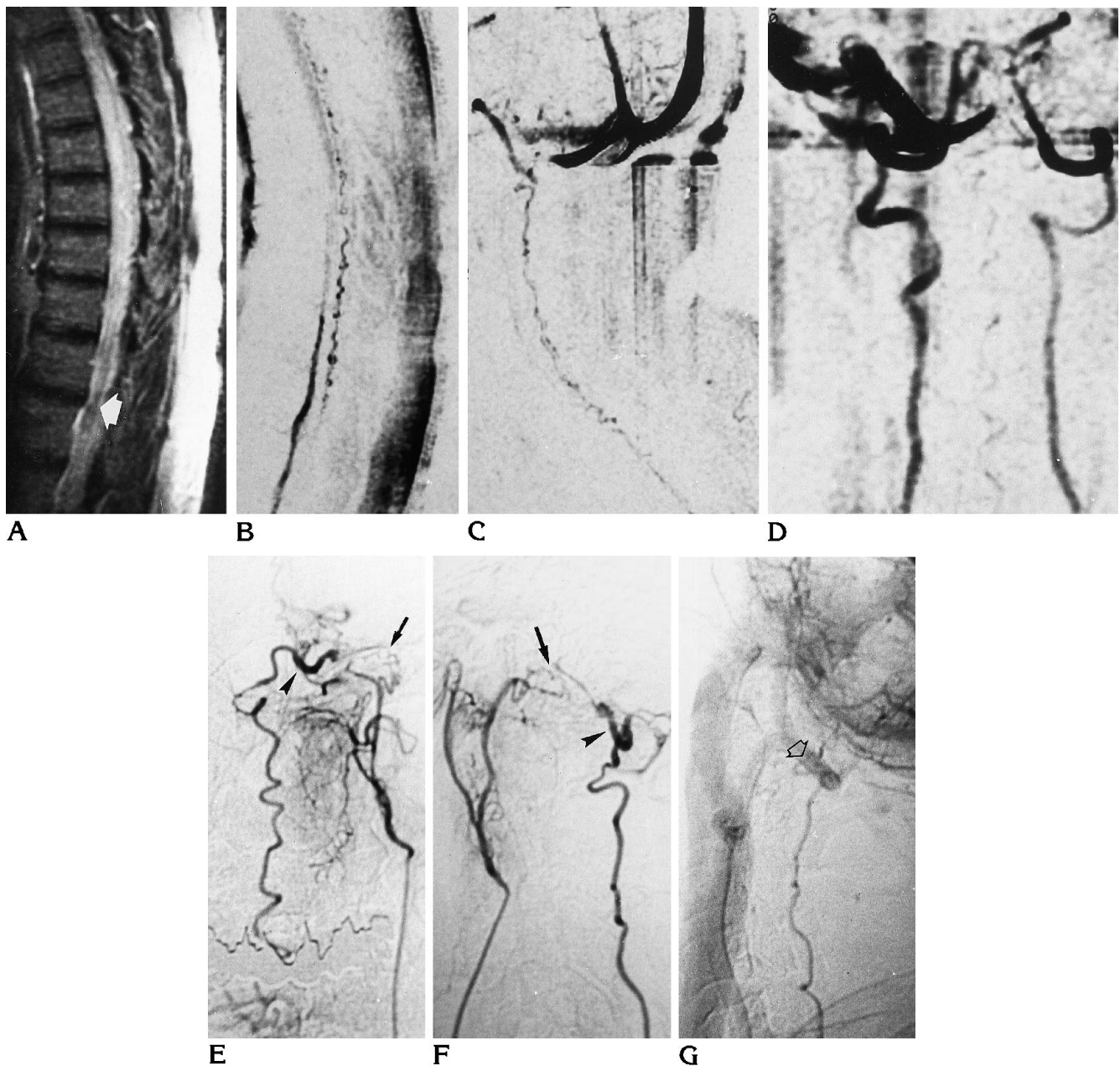


Fig 1. Case 1: 69-year-old man.

A, Sagittal T2-weighted (1750/100/2 [repetition time/echo time/excitations]) spin-echo MR image shows mild swelling and diffuse high signal intensity of the midthoracic spinal cord. The conus medullaris is normal (*arrow*).

B, Two-dimensional phase-contrast MR angiogram of the thoracic spine acquired in the sagittal plane with a gradient-echo sequence (60/27/32) and a 30° flip angle shows an abnormal retromedullary serpiginous vessel.

C and D, Two-dimensional phase-contrast MR angiograms of the cervical spine acquired in the sagittal (C) and coronal (D) plane with a gradient-echo sequence (60/27/32) and a 30° flip angle reveal that the retromedullary serpiginous vessel reaches the skull base.

Anteroposterior (E) and lateral (F) angiographic projections (intermediate phases) after selective injections of the left ascending pharyngeal artery show the fistula (*arrow*) and the draining vein, which is slightly enlarged in its proximal portion (*arrowhead*).

G, Lateral angiographic projection (late phase) after selective injection of the left vertebral artery also shows the retromedullary draining vein (*arrow*).

of the spinal cord with diffusely increased signal intensity on spin density-weighted and T2-weighted images from the bulbomedullary junction to C-7 (Fig 2A). After intravenous injection of gadopentetate dimeglumine (0.1 mmol/kg), tiny, enhanced serpiginous structures anterior and posterior to the cord were noted (Fig 2B). MR angiography of the cervical spine was performed at 1.5 T after administration of contrast material (0.3 mmol/kg) using a three-dimensional phase-contrast technique in the coronal plane with low (6 cm/s) flow-encoding velocity along the craniocaudad, anteroposterior, and left-right axis. The collapsed anteroposterior view of the image modulus showed an abnormally dilated serpiginous vessel that had a median position in the cervical region and approached the left condylar region (Fig 2C). Reconstruction of the image phase of a single-section 15-mm-thick two-dimensional phase-contrast MR angiogram in the sagittal and coronal planes with 6 cm/s velocity encoding along the craniocaudad axis showed caudad flow in the perimedullary vessels (Fig 2D). Selective arteriography (Fig 2E and F) showed a dural arteriovenous fistula at the inner outlet of the left condylar channel fed by the left ascending pharyngeal artery. The fistula drained primarily into the cervical anteromedullary veins and, through multiple anastomoses, into the retromedullary veins. The fistula was occluded by endovascular injection of glue, which produced prompt relief of the patient's symptoms.

Discussion

A combination of enhanced perimedullary vessels with swelling and diffuse signal changes of the spinal cord with or without intramedullary contrast enhancement is characteristic of spinal dural arteriovenous fistula (6, 9). However, detection of these vessels may be difficult on MR images, and missing them may defer myelography or angiography or even lead to biopsy or surgery because of suspected spinal cord tumor (10).

Spinal MR angiography was a useful complement to MR imaging in our two patients, because it established the presence of abnormally dilated slow-flow perimedullary vessels. Moreover, extension of these vessels to the skull base, as seen on spinal MR angiograms, pointed to the possibility of an underlying craniocervical junction dural arteriovenous fistula. This suspicion was considerably strengthened in one patient by the craniocaudad direction of flow in the perimedullary vessels in the phase reconstruction of MR angiography. Craniocervical junction dural arteriovenous fistulas were ultimately seen in both patients on selective arteriograms of the craniocervical vessels. MR angiography failed to show the dural fistula and its arterial

feeders in our patients. This is in line with a previous study (9) and is not surprising, since the arterial feeder of a spinal dural arteriovenous fistula is usually not dilated and the fistula itself can be microscopic (6).

We were impressed by the different levels of clinical deficit and spinal cord signal changes on MR images in our two patients, in whom the dural arteriovenous fistulas were located at the same site with similar patterns of arterial nourishment.

In the patient with paraparesis and signal changes in the thoracic cord, the venous drainage of the fistula involved cervical retromedullary veins, whereas in the patient with tetraparesis and signal changes in the cervical cord, the drainage involved primarily anterior cervical perimedullary veins. A review of 18 cases of intracranial or craniocervical junction dural arteriovenous fistulas with perimedullary drainage (1-8) revealed that 4 of 5 patients with apparent drainage in cervical retromedullary veins had paraparesis and only one had tetraparesis. Conversely, 11 of 13 patients with drainage in the anterior and posterior perimedullary veins had tetraparesis and two had paraparesis. These data suggest that recruitment of the anterior versus posterior perimedullary cervical veins may be relevant to determine the level of spinal cord dysfunction. At variance with this supposition are the numerous anastomoses of the perimedullary veins and the existence of transmedullary anastomotic veins (11) that make unlikely an exclusively anterior or posterior perimedullary venous engorgement.

Another possibly relevant factor to explain the clinical and MR imaging differences in our patients is the convergent or divergent arrangement of the perimedullary veins at the cervicothoracic junction (11, 12). In the convergent pattern, the venous blood of the cervicothoracic cord joins the cervical perimedullary venous system through longitudinal anterior and posterior collectors normally exhibiting cranial-caudad flow. In the divergent pattern, it takes a transverse course through radicular veins, draining in a segmentary fashion to the external vertebral plexus. In craniocervical junction dural arteriovenous fistulas, flow in the perimedullary cervical veins is reversed, starting a condition of perimedullary and intramedullary venous hypertension. The latter, because of gravity, is expected to be more pronounced at lower levels of the spinal cord and is assumed to be the

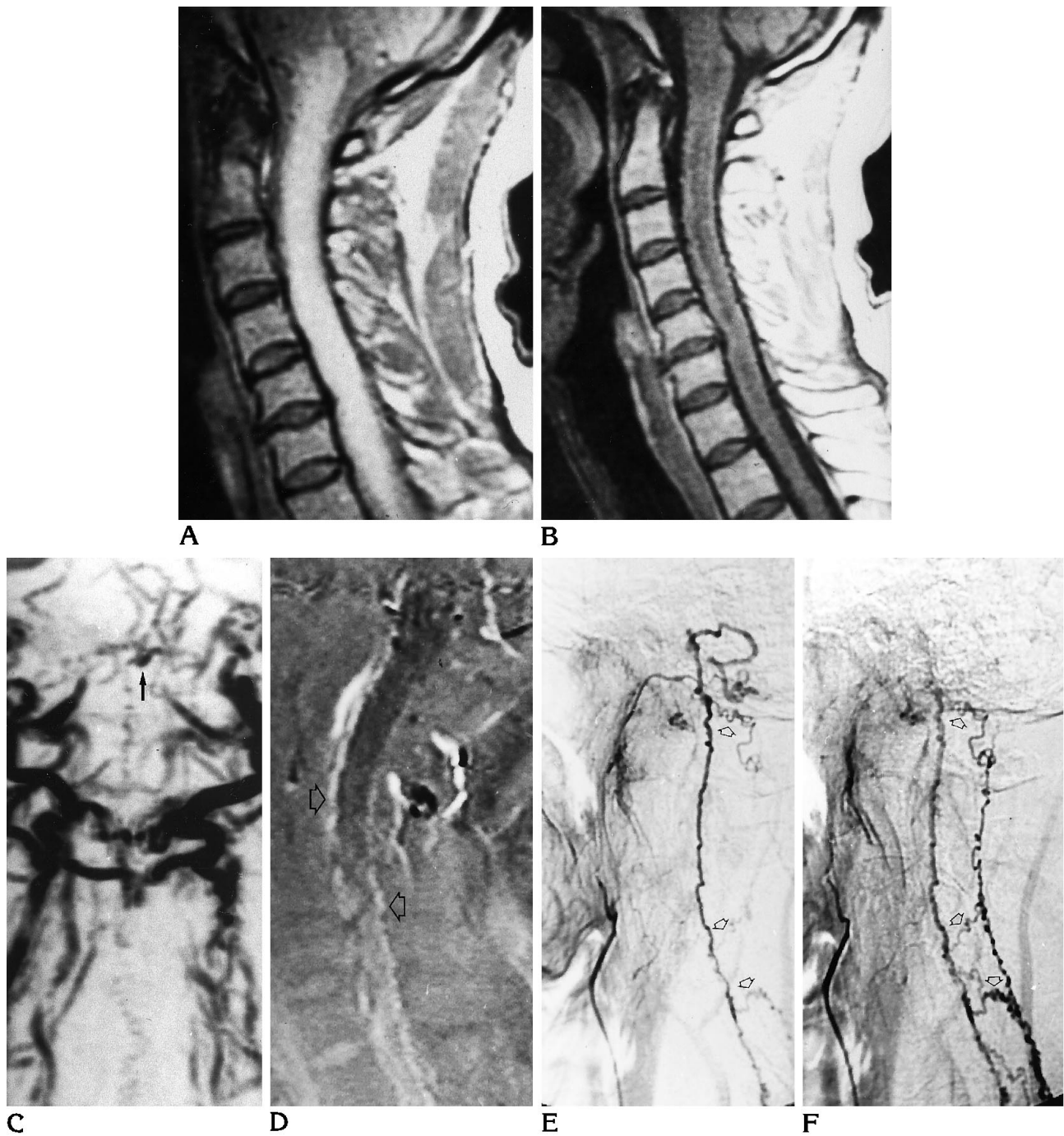


Fig 2. Case 2: 53-year-old man.

A, Sagittal spin density-weighted (2000/40/2) spin-echo image shows diffusely increased signal intensity in the cervical spinal cord from the medulla to C-7.

B, Contrast-enhanced sagittal T1-weighted (400/20/4) spin-echo image shows enlarged and slightly hypointense cervical spinal cord with tiny enhancing anteromedullary and retromedullary structures.

C, Collapsed view of modulus-reconstructed three-dimensional phase-contrast MR angiogram acquired in the coronal plane with a gradient-echo sequence (29/11/2) and a 25° flip angle shows the median serpiginous vessel, which extends to the skull base, where it bends toward the left side (arrow).

D, On phase reconstruction of sagittal two-dimensional phase-contrast MR angiogram with superior-inferior 5 cm/s flow-encoding gradient obtained with a gradient-echo sequence (33/14/16) and a 20° flip angle, signal within the perimedullary vessels is bright (arrows), consistent with a craniocaudal direction of flow.

Intermediate (E) and late (F) phases of lateral angiographic projection after selective injection of left ascending pharyngeal artery show initial filling of the anteromedullary cervical veins and later involvement of the retromedullary veins through multiple anastomoses (arrows).

cause of cord edema that is seen at MR imaging and that is responsible for neurologic dysfunction (11). A convergent pattern may facilitate propagation of the venous hypertension to a lower level of the spinal cord. This pattern may be assumed in our first patient, in whom edema involved the midthoracic cord. Conversely, a divergent arrangement may actually arrest the transmission of the venous hypertension to the thoracic spinal cord and promote edematous changes in the cervical spinal cord, as occurred in our second patient.

In conclusion, our observations indicate that MR angiography may be helpful in the diagnosis of craniocervical junction dural arteriovenous fistulas with perimedullary drainage and that selective injections of the craniocervical arteries must be included in the arteriographic protocol when spinal vascular malformation is strongly suspected. Moreover, these cases reinforce the view that the pattern of venous drainage of dural arteriovenous fistulas is the principal determinant of their clinical presentation (6).

References

1. Woimant F, Merland JJ, Riché MC, et al. Syndrome bulbo-médullaire en rapport avec une fistule artério-veineuse meningée du sinus latéral à drainage veineux médullaire. *Rev Neurol* 1982; 138:559-566
2. Symon L, Kuyama H, Kendall B. Dural arteriovenous malformations of the spine: clinical features and surgical results in 55 cases. *J Neurosurg* 1984;60:238-247
3. Gaensler EHL, Jackson DE, Halbach VV. Arteriovenous fistulas of the cervicomedullary junction as a cause of myelopathy: radiographic findings in two cases. *AJNR Am J Neuroradiol* 1990;11: 518-521
4. Willinsky R, Terbrugge K, Lasjaunias P, Montanera W. The variable presentation of the craniocervical and cervical dural arteriovenous malformations. *Surg Neurol* 1990;34:118-123
5. Rivierez M, Gazengel J, Chiras J, et al. Les fistules artérioveineuses vertebro-durales du tron occipital à drainage médullaire: deux observations. *Neurochirurgie* 1991;37:179-184
6. Berenstein A, Lasjaunias P. *Endovascular Treatment of Spine and Spinal Cord Lesions: Surgical Neuro-Angiography*. Berlin: Springer-Verlag 1992;V:1-85
7. Versari PP, D'Aliberti G, Talamonti G, Branca V, Boccardi E, Collice M. Progressive myelopathy caused by intracranial dural arteriovenous fistula: report of two cases and review of the literature. *Neurosurgery* 1993;33:914-918
8. Cognard C, Gobin YP, Pierot L, et al. Cerebral dural arteriovenous fistulas: clinical and angiographic correlation with a revised classification of venous drainage. *Radiology* 1995;194:671-680
9. Mascalchi M, Bianchi MC, Quilici N, et al. MR angiography of spinal vascular malformations. *AJNR Am J Neuroradiol* 1995;16: 289-297
10. Montine TJ, O'Keane JC, Eskin TA, et al. Vascular malformations presenting as spinal cord neoplasms: case report. *Neurosurgery* 1995;36:194-198
11. Lasjaunias P, Berenstein A. *Functional Vascular Anatomy of Brain, Spinal Cord and Spine: Surgical Neuro-Angiography*. Berlin: Springer-Verlag, 1990;III:15-87
12. Moes P, Maillot C. Les veines superficielles de la moelle épinière chez l'homme. Essai de systématisation. *Arch Anat Hist Embryol* 1981;64:5-110