



## Discover Generics

Cost-Effective CT & MRI Contrast Agents



WATCH VIDEO

# AJNR

### **Intensity of MR contrast enhancement does not correspond to clinical and electroneurographic findings in acute inflammatory facial nerve palsy.**

S Sartoretti-Schefer, P Brändle, W Wichmann and A Valavanis

*AJNR Am J Neuroradiol* 1996, 17 (7) 1229-1236

<http://www.ajnr.org/content/17/7/1229>

This information is current as of June 4, 2025.

# Intensity of MR Contrast Enhancement Does Not Correspond to Clinical and Electroneurographic Findings in Acute Inflammatory Facial Nerve Palsy

Sabine Sartoretti-Schefer, Peter Brändle, Werner Wichmann, and Anton Valavanis

**PURPOSE:** To determine the value of MR contrast enhancement in predicting the course of acute inflammatory facial nerve palsy and in selecting patients for surgical decompression. **METHODS:** Six patients with an acute inflammatory incomplete or complete peripheral facial nerve palsy (five idiopathic and one herpetic in origin) had repeated MR imaging studies with and without contrast enhancement, electroneurography, and clinical examinations to establish a connection between the intensity of contrast enhancement on MR images, the clinical condition, and the electrophysiological data. The examinations were performed every second day starting on the first day of admission until clinical recovery was proved by clinical deblockage (spontaneous clinical improvement). The last examination was performed 3 months after the onset of the facial nerve palsy. **RESULTS:** An abnormal, very intense contrast enhancement of the facial nerve was always present in the distal intrameatal and proximal tympanic segments and in the geniculate ganglion. The labyrinthine segment exhibited a mild to moderate enhancement, and the distal tympanic and mastoid segments showed a moderate to intense enhancement. The intensity of contrast enhancement did not correspond to the severity, duration, or course of the facial nerve palsy, and the electroneurographic data had no predictive value in indicating the severity of the inflammatory process. Three months after clinical recovery, a persistent and more or less unchanged or even slightly more intense contrast enhancement was observed. **CONCLUSION:** The long-lasting intense contrast enhancement seen in the facial nerve segments of patients who have acute peripheral inflammatory facial nerve palsy is explained by a two-phase breakdown of the blood-nerve barrier.

**Index terms:** Magnetic resonance, contrast enhancement; Nerves, facial (VII)

*AJNR Am J Neuroradiol* 17:1229–1236, August 1996

In patients with an acute and complete peripheral facial nerve palsy, the suspected site of the nerve lesion and nerve damage is at the level of the meatal foramen (1) (this is the canalicular entrance to the labyrinthine segment of the facial nerve canal) from where the facial nerve courses through the fallopian canal, exits the temporal bone through the stylomastoid foramen, and enters the parotid gland (1). In

cases of acute peripheral nerve damage, rapid anterograde and retrograde nerve degeneration can be observed (2, 3). The exact degree of nerve fiber degeneration can be measured reliably by percutaneous electroneurography (4–9). Electroneurography cannot be performed within the osseous facial nerve canal, but the nerve fiber degeneration can be measured at the stylomastoid foramen several centimeters distal to the site of the suspected nerve lesion (4–9). Therefore, the extent of maximal nerve fiber degeneration is measured with a temporal delay, relative to the onset of the disease, necessitated by the distance between the location of the nerve damage and the site of the measurements.

Surgical decompression of the facial nerve is indicated in patients who have a complete nerve

---

Received September 27, 1995; accepted after revision February 2, 1996.

From the Departments of Neuroradiology (S.S., W.W., A.V.) and ENT (P.B.), University Hospital of Zürich, Switzerland.

Address reprint requests to Sabine Sartoretti-Schefer, MD, Department of Neuroradiology, Universitätsspital Zürich, Frauenklinikstr 10, 8091 Zürich, Switzerland.

AJNR 17:1229–1236, Aug 1996 0195-6108/96/1707-1229

© American Society of Neuroradiology

palsy and a nerve fiber degeneration of more than 94% within 2 weeks (1, 10). Owing to the delay in making the measurements, subsequent severe nerve fiber degeneration requiring surgical decompression is not detected until at least 1 to 3 days after the onset of the palsy, depending on the variable velocity of the advancing nerve degeneration (6, 7). The longer the palsy lasts, the poorer the prognosis for a complete recovery after surgical decompression; thus, patients should be operated on as early as possible (5).

In patients with inflammatory nerve palsy, abnormal enhancement of the different facial nerve segments is observed on magnetic resonance (MR) images after intravenous injection of gadopentetate dimeglumine (11–17). In this prospective study, we evaluated the intensity of contrast enhancement in the different facial nerve segments on repeated follow-up MR examinations in six patients with acute facial nerve palsy of inflammatory origin. To determine the value of the intensity of contrast enhancement in predicting the course of the disease and in selecting patients for surgical decompression, we compared these data with the clinical findings and with the percentage of nerve fiber degeneration as assessed by electroneurography.

## Subjects and Methods

Six patients (four men and two women) with a mean age of 44 years (range, 21 to 67 years) were studied repeatedly with high-resolution MR imaging, electroneurography, and clinical examination. These six patients represent a clinically homogeneous subgroup culled from a larger series of 35 patients with different types of acute facial nerve palsy (ie, idiopathic, herpetic, human immunodeficiency virus [HIV]-associated, and traumatic) reported elsewhere (18). All patients with acute inflammatory nerve palsy who came to the ear, nose, and throat emergency department during a period of 5 months were asked to participate in this follow-up study on the first day of their admission (therefore, in no patient was the clinical course predictable at the beginning of the study). However, only six patients gave oral consent for repeated MR imaging and for clinical and neurophysiological examinations, and these patients constitute the study cohort. The other 29 patients had only single MR examinations.

An idiopathic, acute, incomplete (four patients) or complete (one patient) peripheral facial nerve palsy was diagnosed in five patients. One patient had a complete herpetic facial nerve palsy diagnosed by elevated IgG and IgM antibodies against varicella-zoster virus, characteristic

auricular vesicles, ear pain, and additional involvement of the eighth cranial nerve.

All the examinations were repeated every second day starting on the first day of admission until the patients showed spontaneous clinical improvement (so-called clinical deblockage, see below), which occurred between the sixth day (patient 4) and the 14th day (patient 2) after the palsy began. The final MR examination was performed between the 83rd and the 110th day after onset of the palsy, by which time five patients had made a complete recovery and one patient had made an incomplete recovery (in most cases, about 3 months after onset). Therefore, each patient had between four and eight MR examinations (average, 5.5 per person), which were performed on a 1.5-T unit. Our standard MR protocol consisted of spin-echo T1-weighted sequences, 500–640/20–25 (repetition time/echo time) with two excitations for noncontrast sequences and four excitations for the postcontrast sequences. A temporal bone surface coil (14-cm diameter) was applied, and the field of view was 160 to 180 mm. Thin sections (2.5 mm) in transverse (interleaved and overlapped) and coronal (overlapped) planes were obtained. Noncontrast transverse T1-weighted sequences were acquired in all cases.

Gadopentetate dimeglumine was injected intravenously in all patients according to a standard high-dose protocol with a bolus of 0.5 mmol/kg body weight. MR imaging was performed immediately after injection of the contrast medium.

The intensity of contrast enhancement within the distal intrameatal and labyrinthine segments, the geniculate ganglion, and the proximal tympanic, distal tympanic, and mastoid segments was evaluated independently by two neuroradiologists. Evaluation consisted of visual rating of the degree of contrast enhancement on a four-point scale: very intense, intense, moderate, or minimal. A total of 198 facial nerve segments were evaluated in the six patients. The region-of-interest method for objective signal intensity measurement of the facial nerve could not be applied because of the small diameter (7) of the fallopian canal (1.02 mm in the labyrinthine segment, 1.53 mm in the tympanic segment, and 1.48 mm in the mastoid segment) and of the facial nerve itself (0.85 mm in the labyrinthine segment, 1.12 mm in the tympanic segment, and 0.94 mm in the mastoid segment) as compared with the smallest region of interest available. The subjective evaluations of both neuroradiologists differed in only four (2%) of the 198 segments. In these instances of disagreement, the lower grade was used.

Electroneurography was performed with surface electrodes in the nasolabial fold after supramaximal stimulation with 0.2-millisecond impulses of 1 kHz and amplitudes of 0.05 to 0.1 V just distal to the stylomastoid foramen, and the maximal compound action potentials were recorded. A bipolar derivation of the maximal muscular sum action potential was obtained from the nasolabial fold by means of surface electrodes. The degree of nerve fiber degeneration was determined as a percentage value of the total amount of active nerve fibers.

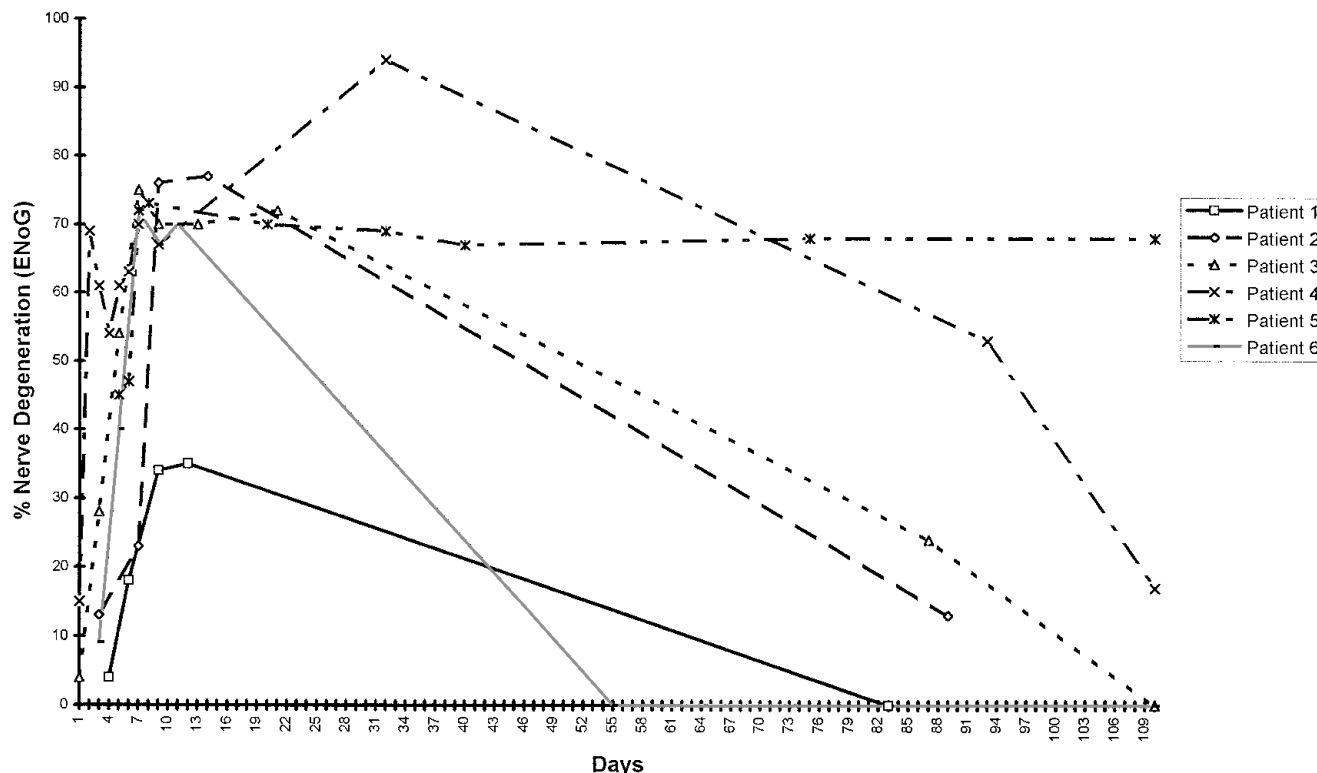


Fig 1. Alterations in the percentage of nerve fiber degeneration as measured by electroneurography (ENoG) during the natural course of acute peripheral inflammatory nerve palsy in six patients.

The clinical severity of the peripheral facial nerve palsy was assessed by the Fisch grading system (1), which rates the ability of the patient to perform four specific face movements—closing the eyelids, whistling, laughing, and frowning—with different degrees of force. Each movement is assigned a value of 0 to 20 points, and, additionally, the muscular tonus during rest is rated up to a maximum of 20 points. Thus, patients with normal facial nerve function obtain a maximum of 100 points, and patients with incomplete or complete peripheral facial nerve palsy have scores below 100. In terms of this classification scheme, the moment at which improvement in the status of complete or incomplete peripheral palsy is noted is called “clinical deblockage,” and leads to a higher score on the Fisch scale. An early clinical deblockage is a good prognostic sign for a favorable clinical outcome (1).

## Results

Figure 1 shows the alterations in the percentage of nerve fiber degeneration as measured by electroneurography during the natural course of acute peripheral inflammatory nerve palsy in our six patients. The Fisch scores that determine the clinical condition of the patients are presented in Figure 2. The percentage of nerve fiber degeneration considerably increased over the first days (the duration was variable in each

patient) but never exceeded the critical value of 94% within 14 days. Despite further increases in nerve fiber degeneration as observed by electroneurography, the clinical recovery that had already begun was such that all six patients were able to perform slight movements of the face (clinical deblockage). Thus, there was no connection between degree of nerve fiber degeneration and clinical condition. Owing to the temporal delay in obtaining the electroneurographic measurements, clinical improvement considerably preceded electroneurographic improvement. Compared with the early spontaneous clinical recovery in our patients, the secondary decrease in percentage of nerve fiber degeneration, indicating a regeneration of the nerve, was considerably delayed and could not be regarded as a reliable prediction of the course of the disease.

Although the natural course of the disease varied among the patients, five patients had made a complete recovery by 3 months after the onset of the palsy and one patient had made an incomplete recovery, as assessed by both clinical examination and electroneurography.

Despite the variable clinical course of the fa-

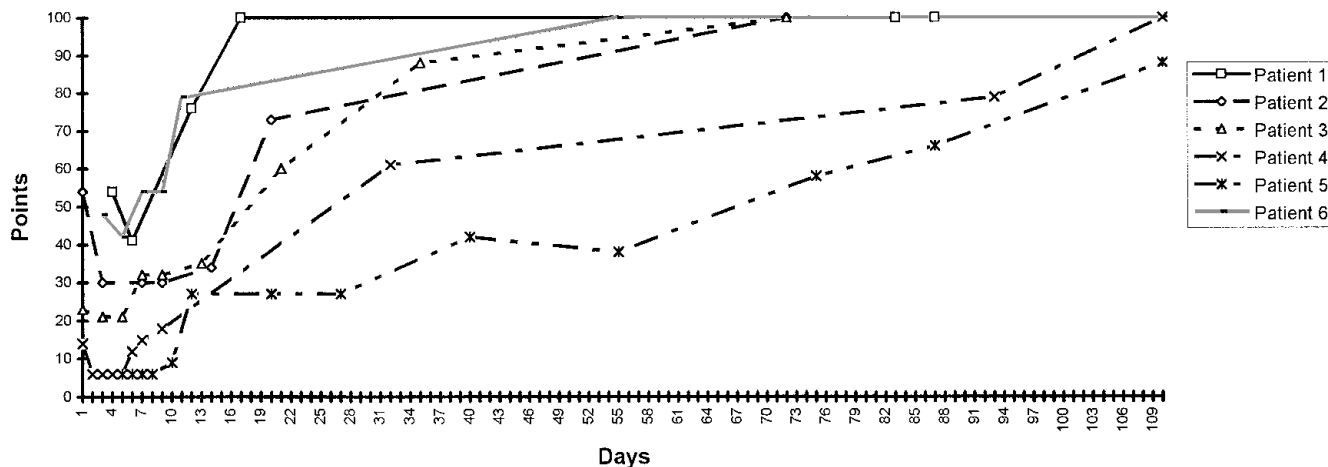


Fig 2. Clinical condition of six patients with acute peripheral inflammatory nerve palsy as determined by Fisch scores.

#### Intensity of contrast enhancement of different facial nerve segments

|           | Segment            |              |                     |                   |                 |         |
|-----------|--------------------|--------------|---------------------|-------------------|-----------------|---------|
|           | Distal Intrameatal | Labyrinthine | Geniculate Ganglion | Proximal Tympanic | Distal Tympanic | Mastoid |
| Patient 1 |                    |              |                     |                   |                 |         |
| 4th day   | +++                | +            | +++                 | +++               | ++              | +++     |
| 83th day  | ++++               | ++           | ++++                | +++               | ++              | +++     |
| Patient 2 |                    |              |                     |                   |                 |         |
| 1st day   | +++                | ++           | +++                 | +++               | ++              | ++      |
| 89th day  | ++                 | ++           | +++                 | +++               | +++             | +++     |
| Patient 3 |                    |              |                     |                   |                 |         |
| 1st day   | ++++               | ++           | ++++                | ++++              | ++              | +++     |
| 87th day  | ++++               | ++           | ++++                | ++++              | +++             | ++++    |
| Patient 4 |                    |              |                     |                   |                 |         |
| 1st day   | ++++               | +            | ++++                | +++               | ++              | ++      |
| 93rd day  | ++++               | ++           | ++++                | ++++              | ++              | +++     |
| Patient 5 |                    |              |                     |                   |                 |         |
| 5th day   | ++++               | +            | +++                 | +++               | ++              | +++     |
| 110th day | +++                | +            | +++                 | +++               | ++              | +++     |
| Patient 6 |                    |              |                     |                   |                 |         |
| 3rd day   | +++                | +            | +++                 | +++               | ++              | +++     |
| 103rd day | ++                 | ++           | +++                 | +++               | ++              | +++     |

Note.—In all patients the intensity of contrast enhancement of the various facial nerve segments at the first and last MR examinations are reported. The first MR examination was always performed on the first day of admission, but in the table the days mentioned represent the exact day after onset of the palsy. The first day of admission is therefore not always the first day of the onset of the disorder.

+ indicates minimal enhancement; ++, moderate enhancement; +++, intense enhancement; and +++++, very intense enhancement.

cial nerve palsy in each patient in whom there was initial deterioration and subsequent improvement, we found no significant alteration in the location and intensity of the contrast enhancement pattern either during the acute phase of the disease (until the occurrence of spontaneous deblockage) or after complete clinical recovery was effected. The Table shows the intensity of the contrast enhancement of the different nerve segments in all patients on the first and on the final day of admission. During the first few days after onset of the facial nerve palsy, the intensity of contrast enhancement of

the different nerve segments did not change; therefore, these data are not presented in the Table. Three months after the onset of the disease, contrast enhancement in the distal intrameatal segment was either constant (two patients), slightly decreased (three patients), or slightly increased (one patient). In the other nerve segments, the contrast enhancement was constant (21 segments) or increased (10 segments) and could still be observed in all patients despite an almost complete clinical recovery (Figs 3 and 4, and the Table). Therefore, no connection could be established between the

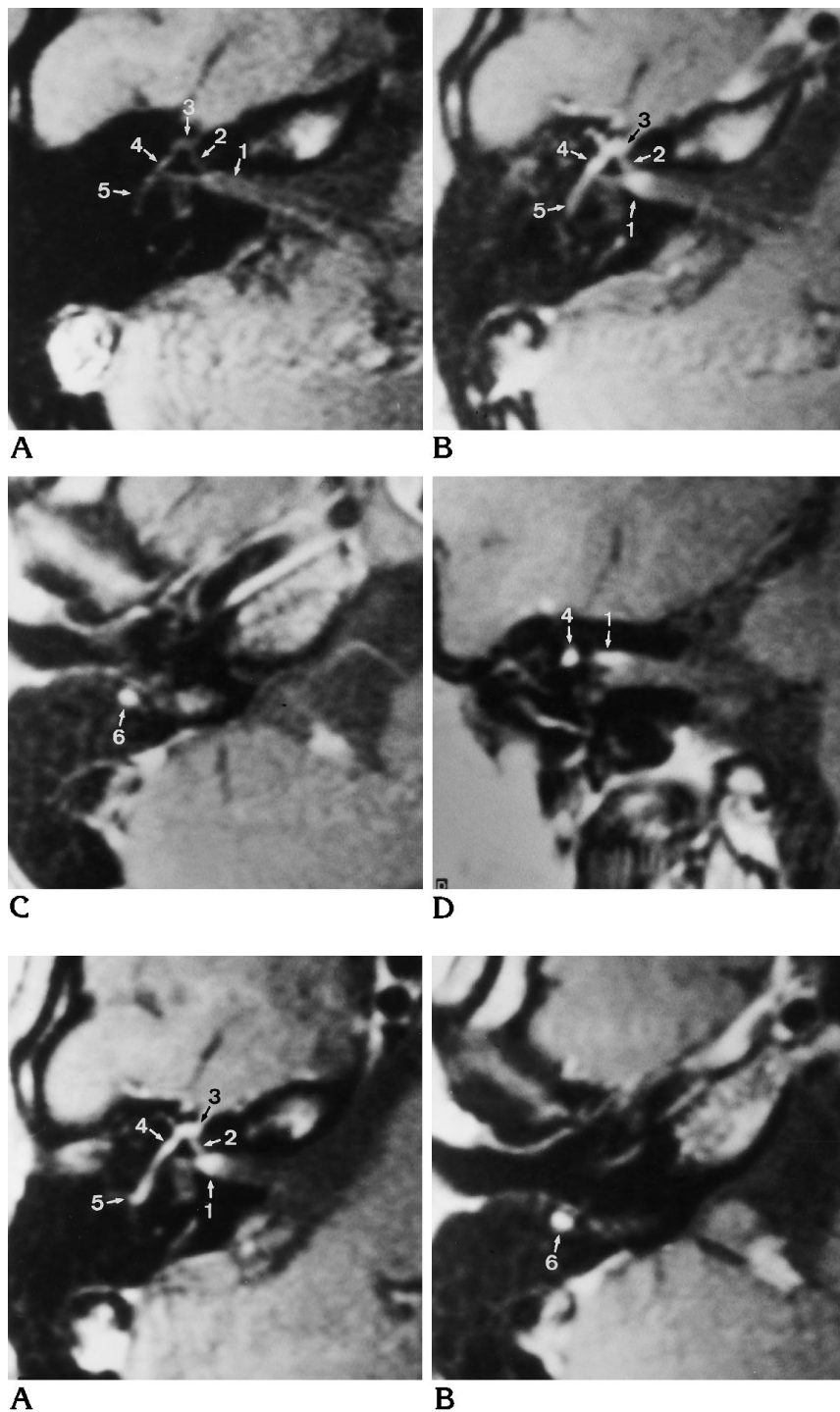


Fig 3. Patient 3: first day of idiopathic peripheral facial nerve palsy.

Transverse noncontrast (A) and contrast-enhanced axial (B and C) and coronal (D) T1-weighted MR images show a very intense enhancement of the distal intrameatal segment (1), the geniculate ganglion (3), and the proximal tympanic segment (4); an intense enhancement of the mastoid segment (6); and a moderate enhancement of the labyrinthine (2) and distal tympanic (5) segments.

Fig 4. Patient 3: 87th day after onset of idiopathic peripheral facial nerve palsy.

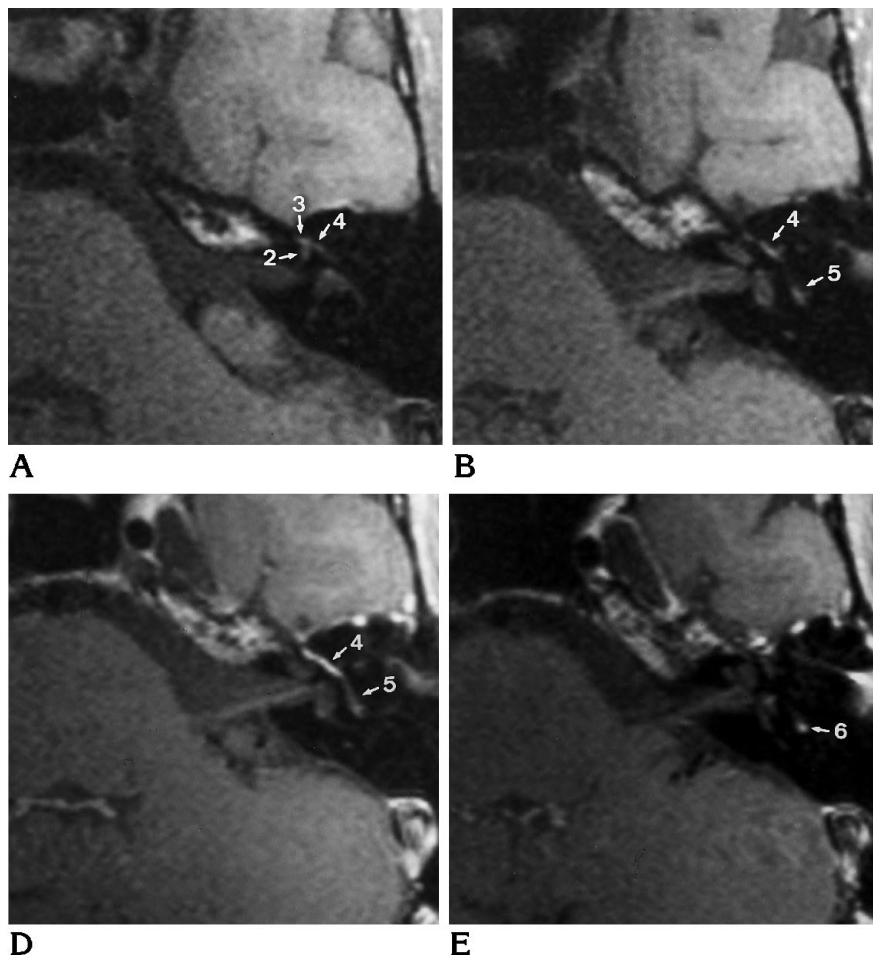
Transverse contrast-enhanced axial T1-weighted MR images (A and B) show enhancement is unchanged in the distal intrameatal (1) and labyrinthine (2) segments, the geniculate ganglion (3), and the proximal tympanic segment (4). The distal tympanic (5) and mastoid (6) segments have slightly more intense enhancement than observed on the first day of the palsy.

intensity of contrast enhancement as assessed visually and the degree of nerve fiber degeneration on one hand and clinical improvement on the other hand. The intensity of contrast enhancement did not correspond to the clinical course.

An abnormal and very intense enhancement of the facial nerve in the distal intrameatal seg-

ment and in the geniculate ganglion and the proximal tympanic segment, as well as a mild but also abnormal enhancement in the labyrinthine segment, were noticed in all patients. In five patients, an abnormally intense enhancement was also observed in the mastoid segment. A moderate enhancement was seen in the distal tympanic segment in six patients and in

Fig 5. Transverse noncontrast (*A* and *B*) and postcontrast (0.5 mmol/kg gadopentetate dimeglumine) (*C-E*) axial T1-weighted MR images of a normal facial nerve show slight enhancement of the geniculate ganglion (3), the proximal (4) and distal (5) tympanic segments, and the mastoid segment (6). No enhancement of the distal intrameatal and labyrinthine segments (2) is seen.



the mastoid segment in one patient. No significant difference in intensity of contrast enhancement among the different nerve segments was observed in any of our six patients. Moreover, the intensity of the enhancement of the various nerve segments had no predictive value in indicating the clinical severity of the inflammatory process.

### Discussion

In acute inflammatory peripheral facial nerve palsy (idiopathic, herpetic, and HIV-associated), recent data assume as the main etiologic factor a latent viral infection of the geniculate ganglion with possible later reactivation and spread of the inflammatory process along the nerve fibers proximally and distally to the geniculate ganglion (11, 19, 20). Pathophysiologically, this process is initiated by the formation of intraneural edema in the neuronal nerve sheaths caused by breakdown of the blood-peripheral nerve barrier and by venous congestion

in the epineural and perineural venous plexus (11). This is assumed to be the underlying mechanism of the strong and abnormal enhancement of the inflamed facial nerve on MR images, especially in the distal intrameatal, labyrinthine, and proximal tympanic segments, and the geniculate ganglion (11, 21, 22) as compared with a slight to moderate enhancement of the geniculate ganglion and the tympanic and mastoid segments in normal facial nerves after injection of 0.5 mmol/kg of contrast material, as observed in our previous study related to the pooling of contrast material in the epineural and perineural venous plexus (Fig 5).

In accordance with the different electrophysiological, histologic, and morphologic criteria, Sunderland has defined five categories of peripheral facial nerve palsy (23, 24). By this grading system, our patients fit into grades 1 (conduction block with contained nerve architecture) and 2 (intact endoneural sheath but some degree of axonal degeneration). At these levels, an anterograde and retrograde wallerian

degeneration is present, but the palsy has the potential for complete regeneration (23, 24). Patients with grade 3 nerve injury have severe nerve damage with destruction of the internal structure of the funiculus and the endoneural sheaths. This situation results from a long-lasting grade 2 nerve injury that is not treated adequately by nerve fiber decompression. Patients with grade 3 injury, as well as those with grade 4 and 5 nerve injury (loss of funicular continuity and total transection of the nerve, respectively), which usually results from trauma, were not included in our study, since, at our institution, patients with grade 2 injury and a nerve fiber degeneration of more than 94% within 2 weeks always undergo surgery and thus never reach grade 3 injury (9, 25).

We found no significant difference in the intensity and location of abnormal contrast enhancement along the different nerve segments. Our results, summarized in the Table and in Figures 1 and 2, indicate that the intensity of the enhancement was obviously independent of the extent, severity, and duration of nerve damage during the observation period of 3 months. Therefore, no relationship can be established between the intensity of the enhancement and the prognosis for the palsy on the basis of findings on contrast-enhanced MR images. The intensity of the contrast enhancement thus cannot be used to differentiate between patients who require nerve decompression surgery to arrest a deteriorating clinical course and those who have a benign course that will resolve spontaneously. Furthermore, no connection can be made between the clinical and electro-neurographic course of the disease and the intensity of contrast enhancement. Even 3 months after the onset of nerve palsy and after complete clinical recovery, a persistent and more or less unchanged or occasionally more intense abnormal contrast enhancement of the various facial nerve segments can be observed.

Long-lasting damage to the blood-peripheral nerve barrier as a prerequisite for the long-lasting contrast enhancement of the facial nerve on MR images must be supposed. The blood-nerve barrier is formed by the endothelium of the endoneural capillaries (the endoneural microvasculature) and by the inner perineural cells (22, 26). Experimental animal studies of acute peripheral nerve lesions (2, 27–32) have shown that the complex process of degeneration and regeneration after nerve injury is accompanied

by a vasogenic response associated with a two-phase breakdown in the blood-nerve barrier linked to the functional and metabolic demands of the tissue. The first phase is rapid and includes breakdown of the endoneural barrier, with an increase in vessel diameter associated with macrophage infiltration and wallerian degeneration. The second phase, which appears later, during the period of regeneration linked to the breakdown of the perineurium, provides a peak into the endothelial surface area that presumably provides for the increased transfer of metabolic substrate to support regeneration (30). These experimental observations can also be applied to the facial nerve, since this nerve behaves histologically and electrophysiologically as a peripheral nerve. Therefore, long-standing damage to the blood-nerve barrier can be suspected as the underlying mechanism to explain the prolonged contrast enhancement of the facial nerve (persisting even after complete recovery in five of our six patients) observed in our study (27–32). Other investigators have reported abnormal contrast enhancement of the different segments of the facial nerve lasting over a period of 3 to 13 months in single cases (12, 14–16).

The maximal increase in vascular permeability in the segments near the site of the lesion occurs much earlier than in the segments distal to the lesion (27–29). This might explain why in most of our cases there was a slight decrease in intensity of contrast enhancement over time in the distal intrameatal segment as opposed to a slight increase in intensity in the segments distal to the labyrinthine segment in the late follow-up MR examinations 3 months after the onset of the palsy.

We are aware of the role that the partial-volume phenomenon plays in the visual evaluation of signal intensity in the small facial nerve canal. Certainly, this phenomenon had an influence on our results, considering the difference between a section thickness of 2.5 mm and a facial nerve diameter of less than 1 mm. However, this applies equally to all cases in our study and to the differentiation of normal from abnormal facial nerve enhancement in acute peripheral inflammatory facial nerve palsy; we refer especially to a previously published study (11). We are also aware that the intensity of the contrast enhancement of the facial nerve is possibly related to the dose of contrast material injected. Our study protocol called for a very



high dose (0.5 mmol/kg) of contrast agent, and our results must be interpreted accordingly. Further studies are required to ascertain the intensity of contrast enhancement of the facial nerve after low doses of contrast material are administered. Additionally, the number of patients examined in this study was small, and a larger study with more patients might produce a different outcome.

In conclusion, serial MR studies were obtained in six patients with acute peripheral inflammatory facial nerve palsy to ascertain the intensity of contrast enhancement of the different facial nerve segments during the natural course of the disease. We found no correspondence between the observed signal intensities and the clinical and electrophysiological findings. The long-lasting intense enhancement of the facial nerve can be explained by a two-phase breakdown of the blood-nerve barrier.

## References

1. Fisch U. Surgery for Bell's palsy. *Arch Otolaryngol* 1981;107:1-11
2. Mellick RS, Cavanagh JB. Changes in blood vessel permeability during degeneration and regeneration in peripheral nerves. *Brain* 1968;91:141-160
3. Chaudhry V, Glass J, Griffin JW. Wallerian degeneration in peripheral nerve disease. *Neurol Clin* 1992;10:613-627
4. Hughes GB. Prognostic tests in acute facial nerve palsy. *Am J Otol* 1989;10:304-311
5. Graham MD, House WF. *Electroneurography and Nerve Excitability Tests in Experimentally Induced Facial Nerve Paralysis*. New York, NY: Raven Press; 1982:99-104
6. Tojima H, Aoyagi M, Inamura H, Koike Y. Clinical advantages of electroneurography in patients with Bell's palsy within two weeks after onset. *Acta Otolaryngol Suppl* 1994;511:147-149
7. Miehleke A, Fisch U. Fazialislähmungen im labyrinthären, meatalen und intrakraniellen Bereich. In: Berendes J, Link R, Zöllner F, eds. *Hals-Nasen-Ohrenheilkunde in Praxis und Klinik*. Stuttgart, Germany: Thieme Verlag; 1979:1-62
8. Prasad S, Hirsch BE, Kamerer DB, Durrant J, Sekhar LN. Facial nerve function following cerebellopontine angle surgery: prognostic value of electroneurography. *Am J Otol* 1993;14:326-329
9. Beck DL, Benecke JE. Electroneurography: electrical evaluation of the facial nerve. *J Am Acad Audiol* 1993;4:109-115
10. Jongkees W. On peripheral facial nerve paralysis. *Arch Otolaryngol* 1972;95:317-323
11. Sartoretti-Schefer S, Wichmann W, Valavanis A. Gadolinium-enhanced MR in patients with idiopathic, herpetic and HIV-associated facial nerve palsies: abnormal enhancement patterns compared with normal individuals. *AJNR Am J Neuroradiol* 1994;15:479-485
12. Kohsyu H, Aoyagi M, Tojima H, et al. Facial nerve enhancement in Gd-MRI in patients with Bell's palsy. *Acta Otolaryngol Suppl* 1994;511:165-169
13. Engström M, Thuomas KA, Naeser P, Stalberg E, Jonsson L. Facial nerve enhancement in Bell's palsy demonstrated by different gadolinium-enhanced magnetic resonance imaging techniques. *Arch Otolaryngol Head Neck Surg* 1993;119:221-225
14. Murphy TP, Teller DC. Magnetic resonance imaging of the facial nerve during Bell's palsy. *Otolaryngol Head Neck Surg* 1991;105:667-674
15. Murphy TP. MRI of the facial nerve during paralysis. *Otolaryngol Head Neck Surg* 1991;104:47-51
16. Schwaber MK, Larson TC, Zealer KL, Creasy J. Gadolinium-enhanced magnetic resonance imaging in Bell's palsy. *Laryngoscope* 1990;100:1264-1269
17. Tien R, Dillon WP, Jackler RK. Contrast-enhanced MR imaging of the facial nerve in 11 patients with Bell's palsy. *AJNR Am J Neuroradiol* 1990;11:735-741
18. Brändle P, Schefer S, Böhmer A, Wichmann W, Fisch U. Correlation of MRI, clinical and electroneurographic findings in acute facial nerve palsy. *Am J Otol* (in press)
19. Yanagihara N. Etiology and Pathophysiology of Bell's Palsy. *Ann Otol Rhinol Laryngol Suppl* 1988;137:1-27
20. Kumagami H. Experimental facial nerve paralysis. *Arch Otolaryngol* 1972;95:305-312
21. Sade J. Pathology of Bell's palsy. *Arch Otolaryngol* 1972;95:406-414
22. Lundborg G. Structure and function of the intraneural microvessels as related to trauma, edema formation and nerve function. *J Bone Joint Surg Am* 1975;57-A:938-948
23. Sunderland S. Some anatomical and pathophysiological data relevant to facial nerve injury and repair. In: Graham MD, House WF, eds. *Disorders of the Facial Nerve*. New York, NY: Raven Press; 1982:47-61
24. Sunderland S. A classification of peripheral nerve injuries producing loss of function. *Brain* 1951;74:491-516
25. Fisch U, Felix H. On the pathogenesis of Bell's palsy. *Acta Otolaryngol* 1983;95:532-538
26. Bradbury M. *The Concept of the Blood-Brain-Barrier*. New York, NY: John Wiley & Sons; 1979:127-135, 351-375
27. Bush MS, Reid AR, Allt G. Blood-nerve barrier: ultrastructural and endothelial surface charge alterations following nerve crush. *Neuropathol App Neurobiol* 1993;19:31-40
28. Podhajsky RJ, Myers RR. The vascular response to nerve crush: relationship to wallerian degeneration and regeneration. *Brain Res* 1993;623:117-123
29. Weerasuriya A, Hockman CH. Perineurial permeability to sodium during wallerian degeneration in rat sciatic nerve. *Brain Res* 1992;581:327-333
30. Latker CH, Wadhwani KC, Balbo A, Rapoport SI. Blood-nerve barrier in the frog during wallerian degeneration: are axons necessary for maintenance of barrier function? *J Comp Neurol* 1991;309:650-664
31. West NR, Collins GH. Relationship of wallerian degeneration to regrowing axons. *J Neuropathol Exp Neurol* 1991;50:693-703
32. Sparrow JR, Kiernan JA. Endoneurial vascular permeability in degenerating and regenerating peripheral nerves. *Acta Neuropathol* 1981;53:181-188