



Discover Generics

Cost-Effective CT & MRI Contrast Agents



WATCH VIDEO

AJNR

Proton MR spectroscopy of squamous cell carcinoma of the upper aerodigestive tract: in vitro characteristics.

S K Mukherji, S Schiro, M Castillo, L Kwock, R Soper, W Blackstock, W Shockley and M Weissler

This information is current as of June 3, 2025.

AJNR Am J Neuroradiol 1996, 17 (8) 1485-1490
<http://www.ajnr.org/content/17/8/1485>

Proton MR Spectroscopy of Squamous Cell Carcinoma of the Upper Aerodigestive Tract: In Vitro Characteristics

Suresh K. Mukherji, Sharon Schiro, Mauricio Castillo, Lester Kwock, Richard Soper, William Blackstock, William Shockley, and Mark Weissler

PURPOSE: To determine the ability of in vitro high-field-strength proton MR spectroscopy to differentiate squamous cell carcinoma of the upper aerodigestive tract from uninvolved muscle. **METHODS:** Surgical specimens of squamous cell carcinoma arising from the upper aerodigestive tract ($n = 18$) and from muscle ($n = 13$) were examined in vitro using high-field (11 T) proton MR spectroscopy. The peak heights of choline and creatine were measured for tumor and muscle at echo times of 136 and 272. The choline/creatine (Cho/Cr) ratio was compared between tumor and normal tissue for each echo time. Student's t test was used to determine whether a significant difference existed between proton MR spectroscopic measurements of the Cho/Cr ratio for tumor and muscle. **RESULTS:** The mean Cho/Cr ratio was consistently higher in tumor than in muscle at all echo times; however, statistically significant differences between tumor and muscle were identified only at longer echo times (136 and 272). **CONCLUSION:** The Cho/Cr peak height ratio can be used to differentiate tumor from muscle in vitro (at 11 T).

Index terms: Carcinoma; Magnetic resonance, spectroscopy; Neck, magnetic resonance; Neck, neoplasms

AJNR Am J Neuroradiol 17:1485–1490, September 1996

A variety of imaging methods, such as computed tomography (CT), magnetic resonance (MR) imaging, and positron emission tomography (PET), have been used to study patients with squamous cell carcinoma of the upper aerodigestive tract. Recently, proton MR spectroscopy has been used to help characterize malignant neoplasms, including various brain tumors, gynecologic tumors, and lymphomas (1–3). Proton MR spectroscopy provides a non-invasive method for evaluating the metabolic components of the soft tissues of the neck. Because proton MR spectroscopy measures the presence of specific metabolites and is not dependent on anatomic information, this technique has the potential to show malignant tu-

mors that are clinically and radiologically occult.

Previous reports have suggested that MR spectroscopy may be used for evaluating both benign and malignant lesions of the extracranial head and neck (4–8). Both phosphorous-31 and proton MR spectroscopy have been used to identify differences in metabolite concentrations in malignant and benign tissues (9). These studies have suggested that there are metabolites that are present in higher concentrations in malignant tumors than in the surrounding normal tissue. It has also been suggested that proton spectra obtained from malignant brain tumors have a higher choline/creatine (Cho/Cr) ratio than is present in normal tissue (9). A similar proton MR spectroscopic pattern has been suggested for squamous cell carcinoma arising from the upper aerodigestive tract (5).

The purpose of this investigation was to evaluate the in vitro Cho/Cr ratio obtained at high-field-strength proton MR spectroscopy (11 T) for squamous cell carcinoma of the upper aerodigestive tract and for muscle and to quantify

Received August 14, 1995; accepted after revision March 14, 1996.

From the Departments of Radiology (S.K.M., S.S., M.C., L.K.), Surgery (S.K.M., W.S., M.W.), Pathology (R.S.), and Radiation Oncology (W.B.), University of North Carolina, Chapel Hill.

Address reprint requests to Suresh K. Mukherji, MD, Department of Radiology, 3324 Infirmary CB 7510, University of North Carolina School of Medicine, Chapel Hill, NC 27599.

AJNR 17:1485–1490, Sep 1996 0195-6108/96/1708–1485

© American Society of Neuroradiology

TABLE 1: Tumors used for spectroscopic analysis

	Location	Type	Stage	Grade
1	Aryepiglottic fold	Primary	II	Moderately to poorly differentiated
2	Pyriiform sinus	Primary	IV	Poorly differentiated
3	Infrahyoid epiglottis	Primary	IV	Moderately differentiated
4	Tongue base	Primary	II	Poorly differentiated
5	Oral tongue	Primary	I	Moderately differentiated
6	Tonsil	Recurrent	I	Moderately differentiated
7	Retromolar trigone	Recurrent	IV	Poorly differentiated
8	Floor of mouth	Recurrent	IV	Moderately differentiated
9	Epiglottis	Primary	II	Moderately differentiated
10	Esophagus	Recurrent	IV	Poorly differentiated
11	Floor of mouth	Recurrent	III	Moderately differentiated
12	Suprahyoid epiglottis	Primary	II	Moderately differentiated
13	True vocal cord	Primary	IV	Moderately differentiated
14	Epiglottis	Primary	II	Moderately differentiated
15	True vocal cord	Recurrent	II	Moderately differentiated
16	Pyriiform sinus	Primary	IV	Moderately differentiated
17	Retromolar trigone	Primary	II	Well differentiated
18	Epiglottis	Primary	IV	Well to moderately differentiated

any differences found between these tissue types.

Materials and Methods

The current study is a prospective in vitro analysis of the one-dimensional proton MR spectra of muscle and squamous cell carcinoma arising from the upper aerodigestive tract performed at high field strengths (11 T). Tissue specimens from both muscle and tumor were analyzed. Volumes of 1 cm³ of tumor (n = 18) and of muscle (n = 13) were obtained at the time of surgical resection. Twelve of the 18 tumor samples were from primary malignant lesions and six were obtained from recurrent tumors that had been previously treated with surgery or radiation therapy. All tumor specimens (both primary and recurrent lesions) were confirmed histologically to consist of squamous cell carcinoma. A summary of the tissue samples evaluated in this study and the location of the tumors is given in Table 1.

Normal tissue consisted of muscle samples that were obtained from the gross specimen. These tissue samples were not directly adjacent to the tumor and did not affect the surgical margins. We were unable to analyze samples composed purely of normal mucosa because of insufficient sample size. The muscle obtained from tumors of the oral cavity or oropharynx consisted of tongue base musculature; tissue from the strap muscles were analyzed for laryngeal, hypopharyngeal, and esophageal carcinomas.

All specimens were placed in plastic vials and were snap frozen in liquid nitrogen within 30 minutes after surgical resection to preserve the metabolites. Samples were stored in a -70°C freezer until the time of spectroscopic analysis. From previous studies, we know that fresh tissue samples that are frozen immediately in liquid nitrogen and stored at -70°C and analyzed at a later time give the same spectra as samples that are analyzed immediately after

retrieval (10). The above tissue procurement protocol was approved by the Institutional Review Board at our institution.

In preparation for proton MR spectroscopy, the samples were thawed, minced, and placed in D₂O phosphate-buffered saline for 15 minutes. Tissue samples were then placed between glass wool plugs (saturated with D₂O) in 5-mm nuclear MR tubes so as to position the tissue between the coils of the proton probe. No freeze-extract nuclear MR studies were performed. Mincing was necessary not only for size considerations but also because it allowed a more uniform packing of the tumor preparation. This minimized any problems with magnetic field inhomogeneity resulting from nonuniform packing of the tumor in the nuclear MR tube and made magnetic field shimming of the sample much easier.

MR proton spectra of excised tumor and normal muscle specimens were obtained by using the Bruker 500-MHz spectroscopy system with 5-mm tubes at 37°C. The water signal was suppressed by using a presaturation pulse centered over the water frequency. One-dimensional proton spectra were acquired with a spin-echo sequence, with data obtained at echo times (TEs) of 136 and 272 over a width of 7042.25 Hz (14.0806 ppm) using 8192 data points, 128 accumulations, an acquisition time of 0.582 second, and a relaxation delay of 2.00 seconds. A line-broadening of 5 Hz was applied to one-dimensional data before Fourier transformation. The spectra obtained were phase-corrected using only a zero-order phase-correction algorithm to obtain the final spectra that were eventually analyzed. The TEs of 136 and 272 were evaluated, as these are typical echo times for chosen localized spectroscopic imaging.

We determined baseline for each spectra by visual inspection after phase correction for the purpose of measuring peak heights. Peak height measurements were obtained for creatine (3.02 ppm) and choline (3.2 ppm) at

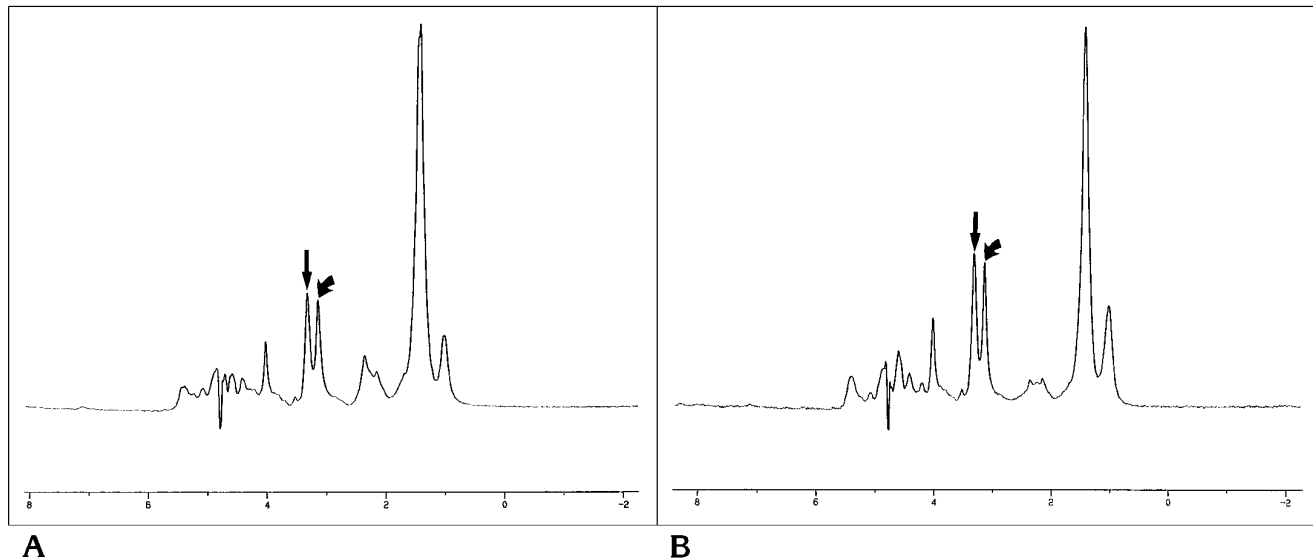


Fig 1. Proton MR spectroscopy of muscle.

A, Proton MR spectroscopy of muscle tissue at 2000/136 (repetition time/echo time) shows the Cho/Cr ratio to be equal to 1.06. *Straight arrow indicates choline; curved arrow, creatine.*

B, Proton MR spectroscopy of the same sample as in A at 2000/272 shows the Cho/Cr ratio to be 1.06, which is similar to that measured in A. *Straight arrow indicates choline; curved arrow, creatine.*

TEs of 136 and 272 for both tumor and muscle. Cho/Cr ratios were calculated for tumor and muscle at each TE. The measurements were made by a single observer. Student's *t* test was used to determine whether there was a significant difference ($P = .05$ level) between the nuclear MR measurements for the Cho/Cr ratio for tumor and muscle at the various TE intervals.

Results

A summary of the tumor samples analyzed in this study is presented in Table 1. The histologic grades of the analyzed tumor specimens were as follows: moderately differentiated, $n = 11$; poorly differentiated, $n = 4$; well differentiated, $n = 1$; moderately to poorly differentiated, $n = 1$; and well to moderately differentiated, $n = 1$.

The results of this study demonstrate that the mean Cho/Cr peak height ratios were higher for tumor than for muscle at all TEs and that statistically significant differences were found at TEs of 136 and 272. At a TE of 136, the mean Cho/Cr peak height ratio for tumor was equal to 2.02 (95% confidence interval [CI] = 1.63 to 2.41); whereas, the mean ratio for muscle was equal to 1.24 (95% CI = 0.90 to 1.58) (Fig 1). This difference was statistically significant ($P = .008$). A similar finding was observed at a repetition time of 2000 and a TE of 272. The mean Cho/Cr peak height ratio for tumor was 2.64

(95% CI = 1.96 to 3.34), whereas the mean for muscle was 1.44 (95% CI = 1.09 to 1.79) (Fig 2). This difference in ratios was also statistically significant ($P = .005$). A summary of the above results is presented in Table 2 and Figure 3. There were no significant differences in the Cho/Cr ratios for the different grades of malignancy.

Discussion

Elevated choline has been detected in malignant tumors of the head and neck (6); however, a specific baseline Cho/Cr ratio indicative of malignancy has not been established for squamous cell carcinoma of the upper aerodigestive tract. In this study we attempted to ascertain whether Cho/Cr ratios are different between squamous cell carcinoma and muscle of the extracranial head and neck and to determine specific ratio levels that may be characteristic of each tissue type.

Choline, a nutrient present in most foods, is absorbed from the diet and is ubiquitous throughout the body (11). The molecule is transported intracellularly by a low-affinity system with its mechanism coupled to the synthesis of phosphatidylcholine (12). Once it is within the cells, choline is initially phosphorylated by

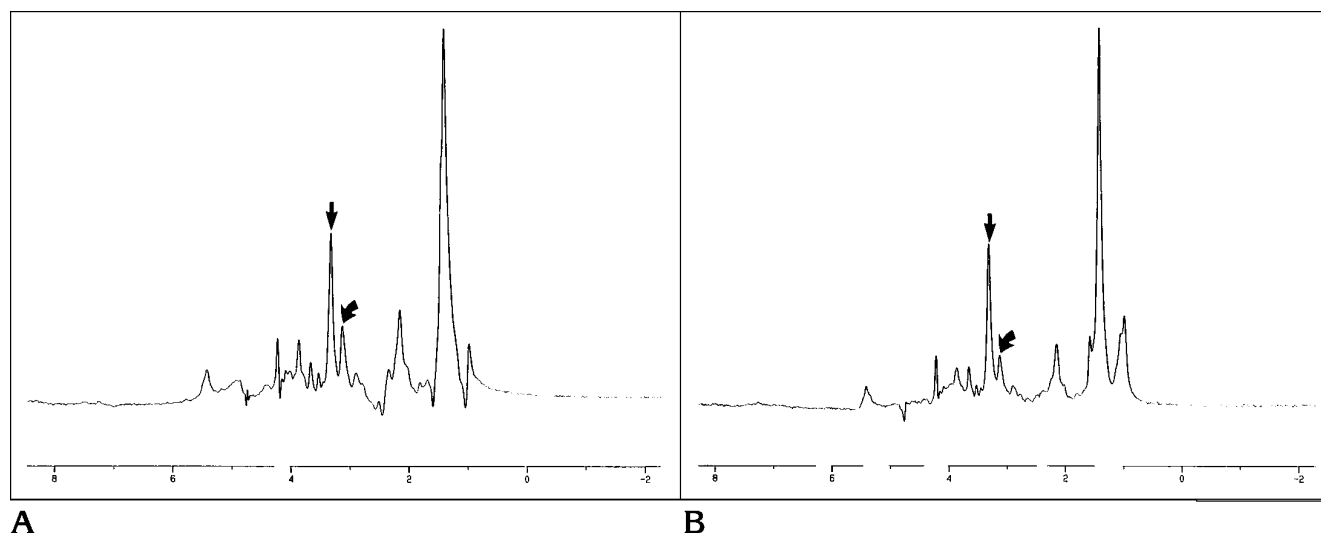


Fig 2. Proton MR spectroscopy of tumor.

A, Proton MR spectroscopy of a tumor sample (squamous cell carcinoma) at 2000/136 shows the choline (*straight arrow*)/creatine (*curved arrow*) ratio to be equal to 2.67. This ratio is also larger than the Cho/Cr ratio obtained at similar parameters for muscle (compare with Fig 1A).

B, Proton MR spectroscopy of the same sample as in A at 2000/272 shows that the Cho/Cr ratio has increased to 4.42. Note the marked difference in this ratio compared with that found in spectra obtained at similar parameters for muscle (Fig 1B). *Straight arrow* indicates choline; *curved arrow*, creatine.

TABLE 2: Mean in vitro choline/creatine (Cho/Cr) ratios for tumor and muscle

Echo Time	Cho/Cr Ratio (\pm SD)		P
	Tumor	Muscle	
136	2.02 (0.78)	1.24 (0.47)	.008*
272	2.64 (1.39)	1.44 (0.49)	.005*

* Statistically significant

choline phosphotransferase to form phosphocholine. This latter molecule is the precursor of phosphatidylcholine, which is formed by the Kennedy pathway (12). Choline and its derivatives are believed to represent important constituents in the phospholipid metabolism of cell membranes (9). The choline peak (resonance peak at 3.2 ppm) is believed to be composed of choline, phosphocholine, phosphatidylcholine, and glycerophosphocholine. Elevation of this peak has been demonstrated in several tumor types and is thought to represent increased membrane phospholipid biosynthesis and also to be an active marker for cellular proliferation (13–15). Specifically, elevation of the Cho/Cr ratio in squamous cell carcinoma has been reported in vivo, although this ratio has not been quantitated (16). Phosphorous-31 spectroscopy has been used to examine patients with various head and neck tumors. Results of these

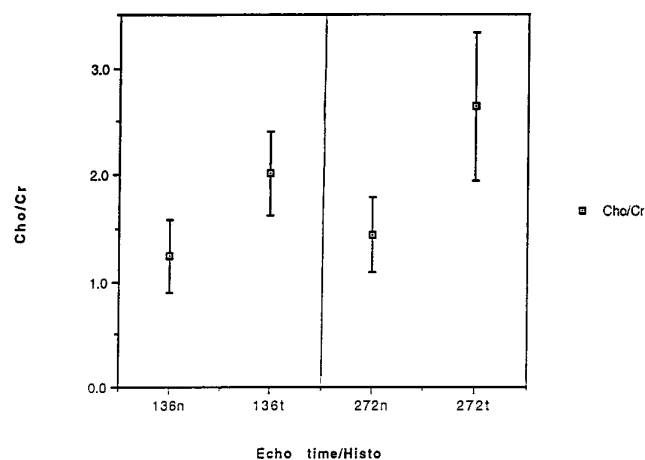


Fig 3. Means and 95% CIs for the Cho/Cr ratios between tumor and muscle for 90 acquisitions at TEs of 136 and 272. This plot shows a progressive increase in the difference between the mean Cho/Cr ratios for tumor and muscle with increasing TE. The difference between the mean ratios for tumor and muscle were found to be statistically significant at TEs of 136 and 272 ($P = .008$ and $.005$, respectively). *N* indicates normal muscle tissue; *t*, tumor; and *Histo*, histologic grade.

studies have shown elevation of the phosphomonoester resonance as compared with normal muscle (8), and this elevated resonance is believed to be composed of phosphocholine and/or phosphoserine (17). The proton MR spectroscopic data found in this study would

suggest that the increase in phosphomonoester levels previously described is due to an increase in phosphocholine.

Creatine plays a role in the maintenance of energy metabolism. It may be obtained from the diet or synthesized *de novo* within the liver, kidneys, and pancreas by precursor molecules, which include arginine, glycine, and S-adenosylmethionine (9, 17). Creatine is converted to creatine phosphate by the enzyme creatine kinase. Creatine phosphate acts as a store for high-energy phosphates in the cytosol of muscles (9). Additionally, because phosphocreatine is a high-energy phosphate compound, it has been postulated that it may help sustain levels of adenosine triphosphate in energy-demanding tissues, such as actively proliferating tumors. The creatine resonance observed at 3.02 ppm is thought to consist of both phosphocreatine and creatine (18, 19). Currently, the exact levels and concentrations of creatine in normal and diseased tissue (ie, tumor or inflammation) are unknown (9).

The spectroscopic analysis was performed using a semiquantitative ratio analysis based on the measurements of peak heights. Both peak height and peak area ratios have been used to evaluate differences between the Cho/Cr ratio between tumors and normal tissue (1–3, 20, 21) (W. Negendank, R. Zimmerman, E. Gotsis, et al, "A Cooperative Group Study of ^1H MRS of Primary Brain Tumors," abstract presented at the annual meeting of the Society of Magnetic Resonance in Medicine, New York, NY, August 1993). The spectra obtained in our study showed no significant line broadening that could potentially result in misinterpretation of the peak intensity analysis.

Our results show that there are statistically significant differences in the peak intensity ratios of choline to creatine between tumor and muscle when analyzed *in vitro* at high field strengths (11 T). The differences in the Cho/Cr ratios between tumor and muscle were found to increase with increasing TE. Alterations in Cho/Cr peak height ratios with respect to TE are most likely caused by differences in T1 and T2 relaxation times, as the spectra in our study were obtained under partial relaxation conditions. This phenomenon results in a reduction in the lipid peak intensities (0.9 to 1.3 ppm) with increasing TE, thereby producing improved visibility of the adjacent choline and creatine regions.

In this study we evaluated only spectra assigned to choline and creatine, because these peaks have been used to differentiate tumor from posttreatment changes and are readily detected on clinical imaging units (1.5 T). Our objective was to identify a spectroscopic marker that can be used to help differentiate squamous cell carcinoma of the extracranial head and neck from nonneoplastic tissue in routine clinical practice. It is possible that differences in other metabolites are present between tumor and normal tissue at high field strengths; however, these metabolites may not be detectable on clinical imaging units (1.5 T). It is also possible that such metabolites may be detected on 3.0-T units; however, very few centers have such units.

The results of this *in vitro* study suggest that there may be a Cho/Cr level that may serve as a threshold and be an indicator of squamous cell carcinoma. Evaluation of the 95% CIs suggest that a Cho/Cr level greater than 1.63 obtained at a TE of 136 or a Cho/Cr level greater than 1.96 obtained at a TE of 272 are indicative of tumor. These minimum levels vary with the TE at which they were obtained. These *in vitro* results may be used for establishing quantitative guidelines for future clinical studies evaluating the ability of proton MR spectroscopy to differentiate tumor from normal tissue.

Although our data suggest that Cho/Cr ratios below 1.58 and 1.79 for TEs of 136 and 272, respectively, are indicative of uninvolved muscle, it is unlikely that microscopic foci of tumor can be completely excluded by proton MR spectroscopy alone, regardless of the field strength. Thus, indeterminate masses with low Cho/Cr ratios that are clinically suggestive of tumor still warrant close clinical and radiologic follow-up, regardless of the spectroscopic findings.

The importance of identifying and isolating a consistent and reproducible metabolic marker for squamous cell carcinoma rests not in the ability to diagnose primary tumors with proton MR spectroscopy but rather in identifying recurrent or residual tumors that are clinically and radiologically occult. Detection of recurrent tumors by physical examination and imaging (CT and MR) is difficult after treatment, as surgery and radiation therapy cause scarring and fibrosis of the underlying tissue that often prevent adequate physical and radiologic examination. Earlier detection of recurrent tumor, before it has progressed to a large lesion, has the poten-

tial to increase the likelihood of cure in those patients in whom initial therapy has failed. This form of surveillance is potentially possible with proton spectroscopy by monitoring the treatment site with interval MR spectroscopy and searching for the presence of markers that are suggestive of recurrent tumor. In addition to benefits of detecting early recurrences, identification of a reliable spectroscopic marker may prevent unnecessary biopsies in patients who do not have recurrent disease.

In the future, proton MR spectroscopy may also be used to monitor response to conservation therapy, such as chemotherapy and radiation therapy, during treatment. Theoretically, persistence of characteristic peaks following initiation of therapy could be indicative of a tumor that is unresponsive to treatment and that may require adjuvant therapy, or that may be completely resistant to conservative management and thus require surgical resection.

In conclusion, the results of our study show that differences between the Cho/Cr ratio can differentiate squamous cell carcinoma of the upper aerodigestive tract from muscle at high field strengths (11 T) and that these differences enlarge with increasing TE. This investigation represents a controlled laboratory analysis of tumor and normal tissue analyzed at high field strength. Further laboratory and clinical studies are needed to confirm our in vitro findings. Currently, we are in the process of correlating our in vitro findings with differences in Cho/Cr peak height ratios obtained with proton MR spectroscopy performed with clinical imaging units (1.5 T) in patients with squamous cell carcinoma of the upper aerodigestive tract.

References

- Gill SG, Thomas DGT, Van Bruggen NV, et al. Proton MR spectroscopy of intracranial tumors: in vivo and in vitro studies. *J Comput Assist Tomogr* 1990;14:497-504
- Delikatny EJ, Russell P, Hunter JC, et al. Proton MR and human cervical neoplasia: ex vivo spectroscopy allows distinction of invasive carcinoma of the cervix from carcinoma in situ and other preinvasive lesions. *Radiology* 1993;188:791-796
- Negendak WG, Brown TR, Evelhoch JL, et al. Proceedings of a national cancer institute workshop: MR spectroscopy and tumor cell biology. *Radiology* 1992;185:875-883
- Vogl T, Peer F, Schedel H, et al. 31-P spectroscopy of head and neck tumors: surface coil technique. *Magn Reson Imaging* 1989;7:425-435
- Mafee MF, Barany M, Gotsis ED, et al. Potential use of in vivo proton spectroscopy for head and neck lesions. *Radiol Clin N Am* 1989;27:243-254
- Russel P, Lean CL, Delbridge L, May GL, Dowd S, Mountford CE. Proton magnetic resonance and human thyroid neoplasia, I: discrimination between benign and malignant neoplasms. *Am J Med* 1994;96:383-388
- Hendrix RA, Lenkinski RE, Vogege K, Bloch, McKenna WG. 31-P localized magnetic resonance spectroscopy of head and neck tumors: preliminary findings. *Otolaryngol Head Neck Surg* 1990;103:775
- McKenna WG, Lenkinski RE, Hendrix RA, Vogege K, Bloch P. The use of magnetic resonance imaging and spectroscopy in the assessment of patients with head and neck and other superficial malignancies. *Cancer* 1989;64:2069-2075
- Miller BL. A review of chemical issues in 1-H NMR spectroscopy: *N*-acetyl-L-aspartate, creatine and choline. *NMR Biomed* 1991;4:47-52
- Johnson M, Selinsky B, Davis M, et al. In vitro NMR evaluation of human thyroid lesions. *Invest Radiol* 1989;24:666-671
- Wurtman JJ. Sources of choline and lecithin in the diet. *Nutr Brain* 1979;5:73-81
- Thompson GA. Phospholipid metabolism in animal tissues. In: Ansell GB, Jawthorne JN, Dawson RMC, eds. *Form and Function of Phospholipids*. Amsterdam, Netherlands: Elsevier; 1973;67-96
- Lean CL, Newland RC, Ende DA, Bokey EL, Smith ICP, Mountford CE. Assessment of human colorectal biopsies by H-1 MRS: correlation with histopathology. *Magn Reson Med* 1993;30:525-533
- Ruiz-Cabello J, Cohen JS. Phospholipid metabolites as indicators of cancer cell function. *NMR Biomed* 1992;5:226-233
- Negendak W. Studies of human tumors by MRS: a review. *NMR Biomed* 1992;5:303-324
- Van Zijl PC, Moonen CT, Gillen J, et al. Proton magnetic resonance spectroscopy of small regions (1 mL) localized inside superficial human tumors: a clinical feasibility study. *NMR Biomed* 1990;3:227-232
- De Cestaines JD, Larsen VA, Podo F, Carpinella G, Briot O, Hensiksen O. In vivo P-31 MRS of experimental tumors. *NMR Biomed* 1993;6:345-365
- Rodwell VW. Conversion of amino acids to specialized products. In: Martin DW, Mayes PA, Rodwell VW, eds. *Harper's Review of Biochemistry*. 18th ed. Los Altos, Calif: Lange Medical Publications; 1981;299-305
- Ross BD. The biochemistry of living tissues: examination by MRS. *NMR Biomed* 1992;5:215-219
- Ott D, Henning J, Ernst T. Human brain tumors: assessment with in vivo proton MR spectroscopy. *Radiology* 1993;186:745-752
- Kugel H, Heindel W, Erinstein R, Bunke J, duMesnil R, Friedman G. Human brain tumors: spectral patterns with localized H-1 MR spectroscopy. *Radiology* 1992;183:701-709