

# Generic Contrast Agents

Our portfolio is growing to serve you better. Now you have a *choice*.



FRESENIUS  
KABI

[VIEW CATALOG](#)

# AJNR

## **Covered stent placement for neurovascular disease.**

R J Singer, M D Dake, A Norbash, T Abe, M L Marcellus  
and M P Marks

*AJNR Am J Neuroradiol* 1997, 18 (3) 507-509

<http://www.ajnr.org/content/18/3/507>

This information is current as  
of May 25, 2025.

---

# Covered Stent Placement for Neurovascular Disease

Robert J. Singer, Michael D. Dake, Alexander Norbash, Toshi Abe, Mary L. Marcellus, and Michael P. Marks

**Summary:** We describe an endovascular technique in which covered stents were used to occlude a parent vessel. In one patient, with a giant paraclinoid aneurysm, a Gortex-covered Palmaz stent was used to occlude the cervical internal carotid artery and to create thrombosis in the aneurysm. In the second patient, with a high-flow vertebrojugular fistula, a hooded stent provided definitive treatment after an attempt to close the fistula by detachable balloon therapy failed. Follow-up of these patients revealed stable stent position and no untoward effects of permanent vessel occlusion.

**Index terms:** Arteries, therapeutic blockade; Interventional instruments, stents

Endovascular parent vessel occlusion by detachable balloon systems has been used as an effective therapy for giant and surgically inaccessible aneurysms. Currently, there is no detachable balloon system approved for use in the United States by the Food and Drug Administration. We describe two cases in which covered stents were constructed and deployed for parent vessel occlusion. One patient had a giant paraclinoid aneurysm and the other had a vertebrojugular fistula. Covered stent placement was effective in both cases, and in one case, it proved to be superior to detachable balloon therapy.

## Case Reports

### Case 1

A 76-year-old right-handed woman had decreased visual acuity in the right eye. Initial intraocular laser treatment failed to improve her condition. Further examination, including magnetic resonance imaging and cerebral angiography, showed a giant right-sided caroticoophthalmic aneurysm filling exclusively via the internal carotid artery (Fig 1A). On examination, she had light perception without projection in the right eye and no other lateralizing signs.

At angiography, cross filling of the right carotid artery circulation via a patent anterior communicating artery was

seen during the left carotid artery injection. A temporary balloon occlusion test was performed in anticipation of carotid artery occlusion, and the patient tolerated 20 minutes of occlusion. A 2-cm Palmaz balloon-expandable stent (Johnson & Johnson, New Brunswick, NJ) was covered with a closed-end 5-mm Gortex tube graft. This stent was placed through a 9F guiding catheter without the use of a guidewire. The Gortex was sutured into place with 10.0 prolene suture material and sewed close at the distal end to create a covering, like a wind sock (Fig 1B). The stent was expanded on a 7 mm  $\times$  2-cm angioplasty balloon (Cordis Corp, Miami, Fla) in the distal cervical right internal carotid artery. Immediate thrombosis of the carotid artery was achieved. The patient tolerated the procedure well with no neurologic sequelae. Follow-up angiography showed parent vessel occlusion with no residual aneurysmal filling (Fig 1C and D). Clinical follow-up at 12 months showed no evidence of thromboembolic complications, and the patient reported improved visual acuity.

### Case 2

After a penetrating neck injury from a glass shard, a 34-year-old woman had a bruit over the left midcervical region and intermittent pain in the left arm. She had no weakness or other neurologic sequelae. Diagnostic angiography revealed a 3  $\times$  2-cm high-flow vertebrojugular fistula at the C6–7 level. The fistula was supplied retrogradely from the distal vertebral artery and anterogradely from the proximal vertebral artery (Fig 2A).

The inflow from the distal vertebral artery was occluded by placement of a detachable balloon (Interventional Therapeutics, South San Francisco, Calif) into the distal cervical segment of the vertebral artery, after which 15 4  $\times$  40-mm and 3  $\times$  30-mm Flower coils (Target Therapeutics, Fremont, Calif) were placed proximal to the balloon. A detachable balloon (Interventional Therapeutics) was then placed into the proximal vertebral artery across the fistula, temporarily occluding the fistula. However, within a few minutes of detachment the balloon shifted position and created an embolus in the right lung. The balloon was successfully snared and punctured in a right pulmonary artery. A 10  $\times$  42-mm wall stent (Schneider, Pfizer Hospital Products Group, Minneapolis, Minn) was placed in the

---

Received February 16, 1996; accepted after revision June 25.

From the Department of Radiology, Stanford University Medical Center, 300 Pasteur Dr, Stanford, CA 94305. Address reprint requests to Michael P. Marks, MD.

AJNR 18:507–509, Mar 1997 0195-6108/97/1803-0507 © American Society of Neuroradiology

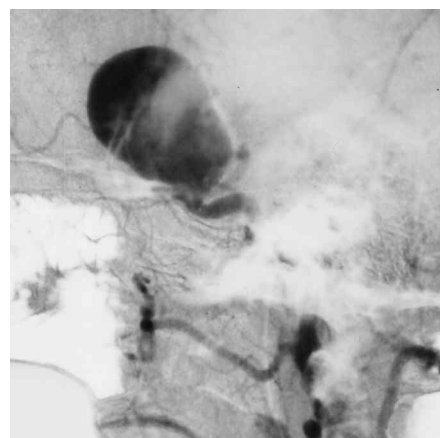
Fig 1. Covered stent placement in a 76-year-old woman with a giant right caroticoophthalmic aneurysm.

A, Right common carotid artery injection (lateral projection) shows a giant supraclinoid aneurysm.

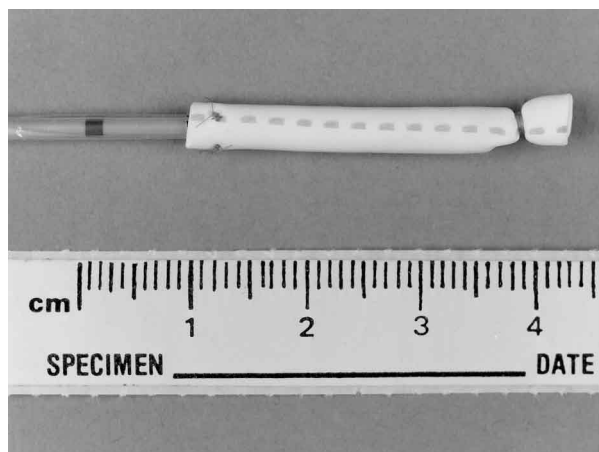
B, Balloon-mounted 2-cm expandable stent covered with a closed-end Gortex graft secured with 10-0 proline suture.

C, Right common carotid artery injection (lateral projection) after stent deployment shows internal carotid artery occlusion.

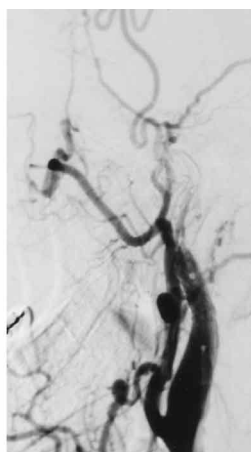D, Control angiogram after stent deployment. Left common carotid artery injection (anteroposterior projection) shows good cross filling to right anterior and middle cerebral arteries.



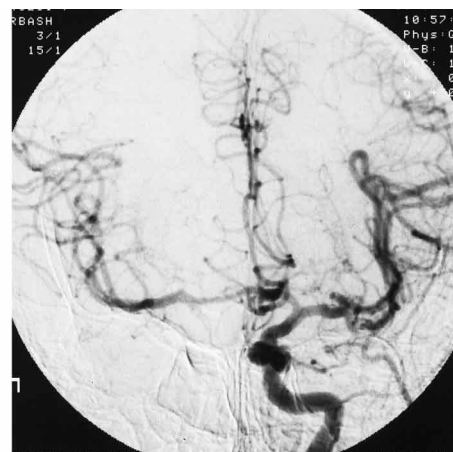
A



B



C



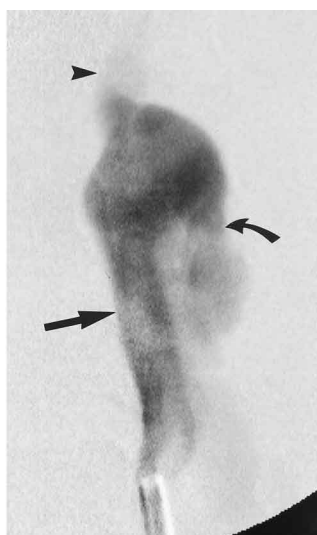
D

Fig 2. A 34-year-old woman with vertebrojugular fistula after a penetrating neck injury.

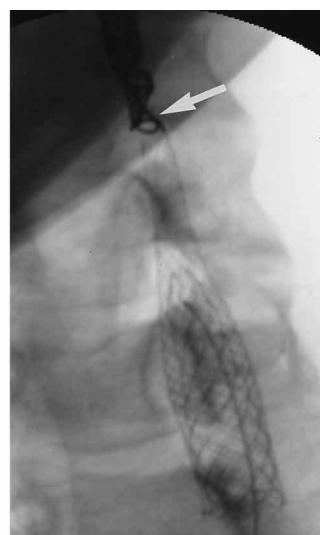A, Left vertebral artery injection (anteroposterior projection) shows a high-flow fistula. Proximal vertebral artery (*straight arrow*) predominantly fills the high-flow fistula and jugular vein (*curved arrow*). It also slightly fills the more distal vertebral artery (*arrowhead*).

B, Fluoroscopic image of the Gortex-covered stent within a previously placed wall stent. Coils (*arrow*) had previously been placed in the distal vertebral artery to prevent antegrade flow.

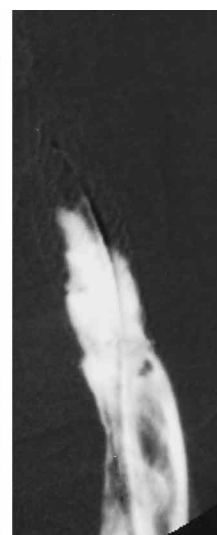
C, Left vertebral artery injection (anteroposterior projection) immediately after covered stent placement shows occlusion of the fistula.



A



B



C

vertebral artery across the fistula. Two additional detachable balloons were then placed within the stent, and flow through the fistula diminished. At angiography 1 week later, however, one balloon had deflated and the other had shifted position so that the flow through the fistula was again high. The remaining balloon was punctured via guidewire. A 4 × 39-mm Palmaz stent covered by Gortex (as described in case 1) was placed across the fistula on a 7 × 20-mm angioplasty balloon (Meditech, Boston Scientific Corp, Watertown, Mass). This stent was deployed within the previously placed wall stent (Fig 2B). The fistula was immediately closed (Fig 2C). Follow-up examination at 17 months showed no evidence of thromboembolic complications or residual fistula.

## Discussion

Parent vessel occlusion via surgical ligation or an endovascular technique is an appropriate therapy for use in properly selected patients with intracranial aneurysms. Such patients often have lesions that are not amenable to surgery owing to complex angioarchitecture, including large size, calcification, unsafe location, or poorly defined necks. Therapy is directed toward excluding the lesion from normal flow or reducing flow, with resultant thrombosis.

The safety and efficacy of detachable balloon systems have been well documented when used in temporary occlusion trials with and without analysis studies of cerebral blood flow. However, current Food and Drug Administration restrictions prevent the use of detachable balloon systems for permanent vessel occlusion in the United States. A suitable alternative may therefore be needed.

Covered stents, similar to those used in the

present study, have been used elsewhere in the circulation with good angiographic and clinical results (1–3); stents have also been used in the cerebrovascular circulation (4–6). In one of our cases, covered stent constructs were more effective than a detachable balloon system, because of the large size and high flow of the fistula. In general, stent placement is more controlled than balloon deployment and eliminates the potential complication of balloon rupture or deflation. As compared with coil embolization, covered stenting yields immediate vessel occlusion and reduces the risk of distal embolization. In conclusion, covered stent constructs can achieve parent vessel occlusion with relative safety and may provide technical advantages over other available materials.

## References

1. May J, White G, Waugh R, Yu W, Harris J. Transluminal placement of a prosthetic graft-stent device for treatment of subclavian artery aneurysm. *J Vasc Surg* 1993;18:1056–1059
2. Marin ML, Veith FJ, Panetta TF, et al. Percutaneous insertion of a stented graft to repair a traumatic femoral arteriovenous fistula. *J Vasc Surg* 1993;18:299–302
3. Cragg AH, Dake MD. Percutaneous femoropopliteal graft placement. *Radiology* 1993;187:643–648
4. Marks MP, Dake MD, Steinberg GK, Norbash AM, Lane B. Stent placement for arterial and venous cerebrovascular disease: preliminary experience. *Radiology* 1994;191:441–446
5. Storey GS, Marks MP, Dake M, Norbash AM, Steinberg GK. Vertebral artery stenting following percutaneous transluminal angioplasty. *J Neurosurg* 1996;84:883–887
6. Wakhloo AK, Schellhammer F, de Vries J, Haberstroh J, Schumacher M. Self-expanding and balloon-expandable stents in the treatment of carotid aneurysms: an experimental study in the canine model. *AJNR Am J Neuroradiol* 1994;15:493–502