

Generic Contrast Agents

Our portfolio is growing to serve you better. Now you have a *choice*.



FRESENIUS
KABI

[VIEW CATALOG](#)

AJNR

MR height of the pituitary gland as a function of age and sex: especially physiological hypertrophy in adolescence and in climacterium.

A Tsunoda, O Okuda and K Sato

This information is current as of May 24, 2025.

AJNR Am J Neuroradiol 1997, 18 (3) 551-554
<http://www.ajnr.org/content/18/3/551>

MR Height of the Pituitary Gland as a Function of Age and Sex: Especially Physiological Hypertrophy in Adolescence and in Climacterium

A. Tsunoda, O. Okuda, and K. Sato

PURPOSE: To clarify the age- and sex-related changes in pituitary height. **METHODS:** We reviewed sagittal T1-weighted MR images in 1020 subjects to analyze the size of the pituitary gland. **RESULTS:** The pituitary height in female subjects (mean, 5.35 mm; SD, 1.2) was significantly greater than that in male subjects (mean, 4.93 mm; SD, 1.0). When the data were analyzed for different age ranges, sex-related differences were statistically significant only in the 10- to 19-, 20- to 29-, and 50- to 59-year-old age groups. The pituitary height peaked in the 20-to-29 age group and tended to decline with age. In female subjects, however, there was a tendency for pituitary height to increase again in the 50-to-59 age group. **CONCLUSION:** The pituitary height may reflect physiological neuroendocrine differences between younger and older subjects and between male and female subjects. The second increase observed in female subjects may likewise reflect high concentrations of gonadotropic hormones, apparently due to an age-related decline in circulating gonadal steroids and an increase in gonadotropin-releasing hormone.

Index terms: Pituitary gland, magnetic resonance; Age and aging

AJNR Am J Neuroradiol 18:551-554, March 1997

Magnetic resonance (MR) imaging has proved to be an accurate diagnostic technique for use in examinations of the pituitary gland. Consequently, there are many occasions in which one encounters such borderline pituitary abnormalities as physiological hypertrophy, microadenoma, inflammatory disease, empty sella, and so on (1). Measurements of the pituitary gland for various age ranges have recently been published (2-9). These studies suggest that changes in the endocrine milieu may be reflected in pituitary morphology, such as the increase in pituitary height during puberty (2-9) and its subsequent age-related decrease in height (3-5, 8, 9). However, the sample sizes in these studies were small, with a total of no more than 300 subjects. We therefore set out to analyze the age- and sex-related changes in pituitary

height across a broad range of ages (10 to 78 years) and in a large number of subjects (more than 1000). Our results support the above-mentioned findings and furthermore reveal a second increase in pituitary height in perimenopausal women.

Materials and Methods

Of 1269 consecutive patients who underwent routine cranial MR imaging over a 9-month period, we investigated 1020 subjects (533 male and 487 female, ranging in age from 10 to 78 years). The following patients were excluded from the study: those with clinical findings suggestive of hypothalamopituitary axis disorder or significant endocrine disturbance; those who reported themselves to be pregnant or breast-feeding; those receiving exogenous hormonal therapy, including thyroid, postmenopausal estrogen/progesterone replacement, and steroid therapy; those receiving medications thought to affect pituitary size, such as phenothiazine, reserpine, or sulpiride; those with psychogenic disorders; those with a suspected increase in intracranial pressure on the basis of head MR images; and those younger than 10 years of age.

All MR images were acquired on a 1.5-T MR system. Precise midsagittal T1-weighted spin-echo images planned from an axial image were used for analysis. In 918 subjects, imaging parameters were 200/15/2 (repetition

Received April 24, 1996; accepted after revision September 4.

From the Department of Neurosurgery, Juntendo University School of Medicine, 2-1-1 Hongo, Bunkyo-ku, Tokyo 113, Japan. Address reprint requests to Akira Tsunoda.

AJNR 18:551-554, Mar 1997 0195-6108/97/1803-0551

© American Society of Neuroradiology

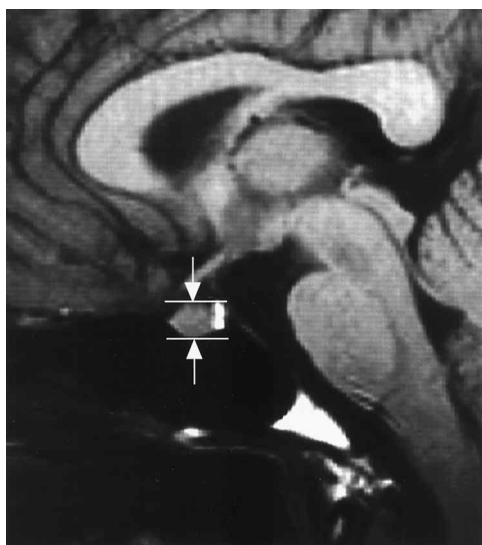


Fig 1. Midsagittal T1-weighted (500/20/2) spin-echo MR image of the pituitary gland (arrows indicate the pituitary height).

time/echo time/excitations); a 256×128 matrix; a 20-cm field of view; and a 9-mm section thickness. In 102 subjects, the parameters were 500/20/2; a 256×224 matrix; a 20-cm field of view; and a 10-mm section thickness. The former parameters were used mainly to obtain scout images, the latter for other clinical purposes.

The height of the pituitary gland was measured as shown in Figure 1. Those with a height of less than 2 mm were regarded as empty sellae and were excluded from the subsequent analysis. Subjects were divided into 14 groups according to age and sex. The mean value of each measurement was obtained. Differences between groups were analyzed with Student's *t* test.

Results

The mean pituitary height was 5.1 mm (SD, 1.1). The mean and range of each subgroup classified by age and sex are given in the Table and in Figure 2. There were no subjects with a pituitary height of 9 mm in the 20- to 29-year-old age group and none with a height of 8 mm in the other age groups. The pituitary height in female subjects (mean, 5.35 mm; SD, 1.2) was significantly greater ($t = 5.739$, $P < .0001$) than that in male subjects (mean, 4.93 mm; SD, 1.0). The mean pituitary height in female subjects in each age group was greater than that in male subjects in the same age group. However, statistically significant differences were observed only in the 10- to 19-year-old group ($P < .05$), the 20- to 29-year-old group ($P < .0001$), and the 50- to 59-year-old group ($P < .0001$) (Table). The pituitary height of both males and females peaked in the 20-to-29 age group, and

declined between the 20-to-29 and 70-to-79 age groups, except in the 50-to-59 age group in women, in which the mean pituitary height increased again. Both male and female subjects younger than 45 years, of whom the females were considered to be in the premenopausal state, had greater pituitary heights than subjects older than 45 years, of whom the women were considered to be in the postmenopausal state ($t = 10.31$, $P < .001$).

In the present study, an empty sella was defined as a sella that, regardless of size, was completely filled with cerebrospinal fluid or had a pituitary height of less than 2 mm. The frequency of empty sellae was 4.3% for all subjects. It tended to be higher in the elderly group, but this difference was not statistically significant ($\chi^2 = .091$) (Table).

Discussion

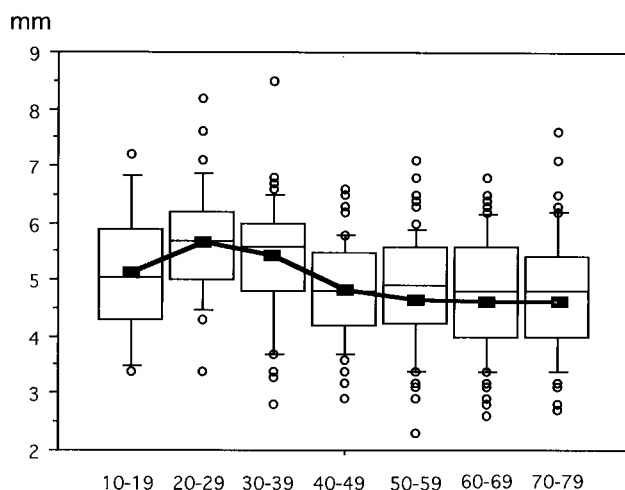
In the results of the present study, especially noteworthy is the finding that the height of the pituitary gland in women increased again in the 50- to 59-year-old age group. The increase in pituitary height during puberty is well known (2, 4, 5, 7, 9), and the age-related decline in pituitary height has also been reported (3-5, 8). Previous studies have suggested that changes in the endocrine milieu may be reflected in pituitary morphology. The increase in pituitary height during puberty may be related to the hypersecretion of luteinizing hormone during this period. The greater pituitary height in young subjects, both male and female, may reflect physiological neuroendocrine differences between younger and older subjects. The decline in pituitary height with age may also reflect the endocrinology of aging and a physiological pituitary atrophy.

It has been reported that basal serum concentrations of gonadotropic hormones (luteinizing hormone, follicle-stimulating hormone) decline after puberty up to the fifth decade (10). In women, however, concentrations of these hormones begin to increase dramatically in the fifth and sixth decades, apparently due to an age-related decline in circulating gonadal steroids (loss of feedback) and an increased "drive" from gonadotropin-releasing hormones (10). If it is true that the endocrine milieu is reflected in a person's pituitary height, it seems reasonable to assume that women have greater pituitary height in this period. Doraiswamy et al (3) spec-

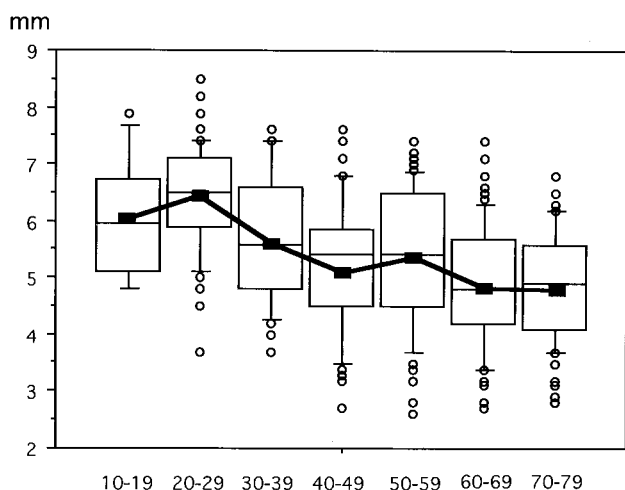
Mean height, mm, of pituitary gland by age and sex with test of statistical significance between corresponding age groups (Student's *t* test)

Age Group, y	Male		Female		P Value	n (ES)
	Mean (SD)	n (ES)	Mean (SD)	n (ES)		
10-19	5.10 (1.17)	14 (0)	6.05 (1.06)	12 (0)	.0419	26 (0)
20-29	5.63 (1.00)	44 (1)	6.48 (0.95)	71 (0)	<.0001	115 (1)
30-39	5.40 (1.06)	45 (0)	5.68 (1.10)	33 (1)	.2688	78 (1)
40-49	4.89 (0.87)	68 (2)	5.19 (1.13)	56 (1)	.1011	124 (3)
50-59	4.80 (1.03)	117 (2)	5.44 (1.18)	92 (5)	<.0001	209 (7)
60-69	4.78 (1.02)	134 (7)	4.88 (1.07)	137 (13)	.7457	271 (20)
70-79	4.78 (1.05)	111 (8)	4.87 (0.95)	86 (4)	.7547	197 (12)
Total	4.93 (1.05)	533 (20)	5.35 (1.12)	487 (24)	<.0001	1020 (44)

Note.—ES indicates empty sella.



A



B

Fig 2. Pituitary height (vertical axis) in male (A) and female (B) subjects by age group in years (horizontal axis). Central horizontal lines indicate 50th percentile of the data, boxes indicate 25th to 75th percentile, outer horizontal lines indicate 10th to 90th percentile, and the outer dots indicate values outside the 10th and 90th percentiles. Lines indicate the average pituitary height in each group.

ulated that the greater pituitary height observed in some of the elderly subjects in their study could reflect compensatory hypertrophy following a greater loss of gonadal steroid feedback. The present study confirms the increased pituitary height in women of perimenopausal age.

The greater pituitary height in young people is well known (2-5, 7, 8). Previous studies have reported that pituitary height peaks in the 10- to 19-year-old age group of both sexes (2, 5, 7), or in the 20- to 29-year-old age group (4), which is in agreement with our findings. We do not know the reason for this difference, and more data are required before a conclusion can be reached.

Is it sufficient to discuss pituitary height but not length or volume with respect to pituitary size? Some previous investigators (3, 4, 11) have stated that changes in pituitary size are mainly due to changes in gland height, as there are no age-related effects on gland length or width. Lurie et al (11) suggested that future studies might reasonably use pituitary height alone, with findings on midsagittal T1-weighted images serving as the single measure of pituitary size.

The section thickness of the images must be called into question. We used rather thick sagittal images of 9 to 10 mm. The pituitary gland is often concave superiorly, and this would not be reflected in a single, thick sagittal image, which might show only the higher lateral margins. This would seem to raise questions regarding the reliability of our height measurements. For example, the gland volume might actually be decreased, even in the presence of increased height at the lateral aspects of the gland. The same problem arises in partially empty sellae, in which one generally sees gland tissue extending to the full height along the lateral margins

while the height at the center is very low. Strictly speaking, our results reflect the average of lateral and midsagittal pituitary heights, and must therefore be accepted with some reservations.

An empty sella is defined as a sella that, regardless of size, is partly or completely filled with cerebrospinal fluid (12). However, it is not always easy to distinguish between an empty sella and a normal or atrophic pituitary gland on MR images. For the sake of convenience, we defined empty sellae as those with a pituitary height of less than 2 mm, and excluded them from later analysis. Previous studies have reported the prevalence of empty sellae to be about 5% for all ages, with an increase in prevalence with age (12). Our results also support this observation, although the observed differences were not statistically significant.

Although our results were obtained in a patient population and rather thick image sections were used, our study does provide meaningful data on pituitary size for 1020 subjects. The pituitary height peaked in the 20- to 29-year-old age group in both sexes, and tended to decline between the ages of 30 and 79 years. A pituitary height greater than 9 mm in the 20 to 29 age group or 8 mm in the other age groups should be considered abnormal. In women, the pituitary height tended to increase again in the 50- to 59-year-old age group, which might reflect compensatory hypertrophy following a greater loss of gonadal steroid feedback. Correlative endocrine studies as well as further MR imaging studies are clearly required to test our hypothesis and to clarify the functional significance of differences in pituitary size. Such data should facilitate the further evaluation of pituitary morphology in neuroendocrine disorders.

Acknowledgments

We thank Youko Wagatsuma, Koichi Hongo, Takeshi Narahara, Hideyo Sudo, Noboru Toyoda, and Kazuhiro Hirai for their technical assistance.

References

1. Rauschnig W. Sella/suprasellar masses. In: Osborn AG, ed. *Diagnostic Neuroradiology*. St Louis, Mo: Mosby-Year Book; 1994: 461-484
2. Argyropoulou M, Perignon F, Brunelle F, Brauner R, Rappaport R. Height of normal pituitary gland as a function of age evaluated by magnetic resonance imaging in children. *Pediatr Radiol* 1991;21: 247-249
3. Doraiswamy PM, Potts JM, Axelson DA, et al. MR assessment of pituitary gland morphology in healthy volunteers: age- and gender-related differences. *AJNR Am J Neuroradiol* 1989;13:1295-1299
4. Hayakawa K, Konishi Y, Matsuda T, et al. Development and aging of brain midline structures: assessment with MR imaging. *Radiology* 1989;172:171-177
5. Suzuki M, Takashima T, Kadoya M, et al. Height of normal pituitary gland on MR imaging: age and sex differentiation. *J Comput Assist Tomogr* 1990;14:36-39
6. Wiener SN, Rzeszutarski MS, Droegge RT, Pearlstein AE, Scafron M. Measurement of pituitary gland height with MR imaging. *AJNR Am J Neuroradiol* 1984;6:717-722
7. Elster AD, Chen MYM, Williams DW, Key LL. Pituitary gland: MR imaging of physiologic hypertrophy in adolescence. *Radiology* 1990;174:681-685
8. Peyster RG, Adler LP, Viscarello RR, Hoover ED, Skarzynski J. CT of the normal pituitary gland. *Neuroradiology* 1986;28:161-165
9. Peyster RG, Hoover ED, Viscarello RR, Moshang T, Haskin ME. CT appearance of the adolescent and preadolescent pituitary gland. *AJNR Am J Neuroradiol* 1983;4:411-414
10. Simpkins JW, Estes KS. Role of monoaminergic neurons in the age-related alternations in anterior pituitary secretion. In: Nemeroff CB, Duun AJ, eds. *Peptides, Hormones and Behavior*. New York, NY: Spectrum Press; 1984;823-863
11. Lurie SN, Doraiswamy PM, Husain MM, et al. In vivo assessment of pituitary gland volume with magnetic resonance imaging: the effect of age. *J Clin Endocrinol Metab* 1990;71:505-508
12. Bjerre P. The empty sella. *Acta Neurol Scand Suppl* 1990;82: 1-25