

Generic Contrast Agents

Our portfolio is growing to serve you better. Now you have a choice.



[VIEW CATALOG](#)

AJNR

Collagen-coated acrylic microspheres for embolotherapy: in vivo and in vitro characteristics.

C P Derdeyn, V B Graves, M S Salamat and A Rappe

AJNR Am J Neuroradiol 1997, 18 (4) 647-653

<http://www.ajnr.org/content/18/4/647>

This information is current as of May 22, 2025.

Collagen-Coated Acrylic Microspheres for Embolotherapy: In Vivo and In Vitro Characteristics

Colin P. Derdeyn, Virgil B. Graves, M. Shahriar Salamat, and Alan Rappe

PURPOSE: To evaluate the in vivo and in vitro properties of collagen-coated acrylic microspheres and to compare them with polyvinyl alcohol (PVA) particles. **METHODS:** Samples of 100- to 300- μm , 300- to 500- μm , 500- to 700- μm , and 700- to 900- μm collagen-coated acrylic microspheres and 200- to 300- μm PVA particles were suspended in solutions of 50% saline and 50% contrast material. The samples were evaluated for quantitative and qualitative microscopic characteristics (shape, size, deformability); injectability via standardized microcatheters; degree of particulate penetration in the pig rete mirabile; and reaction of tissue to the particles in 48-hour- and 4-week-old specimens. **RESULTS:** The acrylic microspheres were spherical and deformable. The sample of 100- to 300- μm microspheres ($n = 202$) had a mean diameter of 210 μm (standard deviation, 43 μm). Hub accumulation, particle aggregation, and catheter occlusion were not observed with the microspheres (all sizes) but were noted with the PVA particles. The 200- to 300- μm PVA particles formed aggregates in the proximal rete. The 100- to 300- μm microspheres were found throughout the rete and beyond. Chronic transmural and perivascular inflammation was observed with the microspheres and the PVA particles. **CONCLUSIONS:** Particle aggregation and catheter occlusion do not complicate the transcatheter delivery of collagen-coated acrylic microspheres as they do with PVA particles. For a given particle and vessel size, acrylic microspheres penetrate to a much greater extent than the PVA particles. Tissue reaction to acrylic microspheres and PVA particles is similar.

Index terms: Interventional materials, particles and microspheres; Animal studies

AJNR Am J Neuroradiol 18:647-653, April 1997

Therapeutic embolization is a well-established tool for the treatment of many vascular lesions. Polyvinyl alcohol (PVA) is perhaps the most widely used particulate embolic agent. Its biocompatibility is well documented, as is its efficacy as a relatively permanent embolic agent (1-7). However, the irregular PVA particles tend to aggregate and clump, which may lead to catheter occlusion (8, 9). These and

other properties may also limit the degree of particulate penetration into a vascular lesion (7).

New agents continue to be developed to resolve these difficulties. Embosphere (Guerbet Biomedical; Louvres, France) is the trade name for a commercially prepared, hydrophilic, non-resorbable, collagen-coated, acrylic microsphere currently used in Europe. The purpose of this project was to evaluate and characterize the properties of these new injectable particles and to compare them with polyvinyl alcohol (PVA) particles.

Materials and Methods

Commercial samples of 100- to 300- μm , 300- to 500- μm , 500- to 700- μm , and 700- to 900- μm Embospheres packaged in sterile saline (Guerbet Biomedical) and 200- to 300- μm PVA particles (Biodyne, El Cajon, Calif) were obtained. Each vial of Embospheres and PVA particles was suspended in 40 to 50 mL of a 50% saline and 50% contrast (Omnipaque 300, Nycomed; New York, NY) so-

Received June 20, 1996; accepted after revision October 21.

Presented at the annual meeting of the American Society of Neuroradiology, Seattle, Wash, June 1996.

Supported in part by Target Therapeutics Inc, for which Dr Graves is a paid consultant.

From the Departments of Radiology (C.P.D., V.B.G., A.R.) and Pathology (M.S.S.), University of Wisconsin Hospitals and Clinics, Madison.

Address reprint requests to Colin P. Derdeyn, MD, Mallinckrodt Institute of Radiology, 510 S Kingshighway, St Louis, MO 63119.

AJNR 18:647-653, Apr 1997 0195-6108/97/1804-0647

© American Society of Neuroradiology

lution, similar to that used in our clinical practice. Subjectively dilute solutions were used, although the concentration of particles in solution was not measured. Four separate experiments were pursued.

1) To assess particle shape, consistency, and deformability, we first qualitatively evaluated a sample of 100- to 300- μm Embospheres in solution under a light microscope ($\times 10$ magnification). The range of particle diameters was then measured in a random sample by using a calibrated ruler. The median, maximum, and minimum diameters and the standard deviation were calculated.

2) The injectability of the particles through a 3F/1.5F catheter (Balt; Montmorency, France) was evaluated by using a standard method of infusion. All four available sizes of Embospheres were evaluated as well as the 200- to 300- μm PVA particles for purposes of comparison. The catheter was passed through a serpiginous tubing system to simulate the cerebral vasculature. Suspended particles were then hand-injected with a 3-mL syringe. To see the injected particles best, we placed the catheter tip in a clear collection bowl on top of a dark background with indirect lighting. The degree of resistance on injection was subjectively graded on a scale of 0 to 5, where saline injection is 0 and occlusion is 5. The catheter was observed for accumulation of particles at the hub. In addition, the passage of suspended 100- to 300- μm and 700- to 900- μm Embospheres through the clear distal portion of Tracker-18 and Tracker-10 catheters (Target Therapeutics; Fremont, Calif) was observed under a microscope.

3) The depth of penetration of PVA particles and Embospheres was evaluated in the pig rete mirabile. Retia were unilaterally embolized to occlusion with 200-300- μm PVA particles ($n = 3$) or 100- to 300- μm Embospheres ($n = 4$) in seven juvenile (20 to 25 kg) Chester-White swine. The contralateral rete served as both the histologic and arteriographic control. The experimental protocol was approved by our institution's Animal Care Committee.

The pigs were anesthetized before intubation (Telazol [tiletamine/zolazepam] 7 mg/kg, xylazine 2.2 mg/kg, and atropine 400 μg , intramuscularly). General anesthesia during the endovascular procedures was maintained with halothane. A 6F vascular sheath was percutaneously placed into a common femoral artery via standard Seldinger technique. A 6F guiding catheter (Fasguide; Target Therapeutics) was fluoroscopically placed into each common carotid artery for bilateral baseline arteriograms. The ascending pharyngeal artery, which supplies the rete and emerges distally as the internal carotid artery, was selectively catheterized over a guidewire with the use of a microcatheter (Tracker 18; Target Therapeutics) placed through the guiding catheter.

After angiographic confirmation of catheter placement, the rete was embolized to occlusion with the 200- to 300- μm PVA particles ($n = 3$) or the 100- to 300- μm Embospheres ($n = 4$) for the acute experiments. Completion arteriograms were obtained bilaterally after the microcatheter was removed. The pigs were killed immediately

after angiography was concluded by means of an intravenously administered barbiturate overdose.

The skull base and brain were then dissected out and allowed to fix in a 10% formalin solution for 7 to 10 days. The entire rete (both sides and the midline connections) was then dissected from the surrounding bone and soft tissues (rete dissection guide provided by John Roberts, Department of Radiological Sciences, University of California at Los Angeles). After further fixation, the retia were sectioned into 2-mm coronal sections from posterior (at the junction of the ascending pharyngeal artery and the rete) to anterior. The average rete was divided into six coronal sections (range, six to eight). The sections were then embedded in paraffin, sliced in thicknesses of 5 μm , and stained with standard hematoxylin-eosin.

The degree of particulate penetration into the rete was quantified in the sequential coronal sections from the six acute preparations using the 100- to 300- μm Embospheres (four pigs) and the 200- to 300- μm PVA particles (three pigs). Two observers reviewed the slides from sequential sections for the presence of PVA or Embosphere particles. The depth of penetration into the rete was recorded. An average rete arteriole diameter was established by measuring a glutaraldehyde-fixed rete embedded in plastic.

4) The tissue response of the pig rete mirabile to embolization was assessed microscopically in 48-hour- and 4-week-old specimens from four additional juvenile Chester-White swine. Embolization was performed with 700- to 900- μm Embospheres ($n = 2$) or 200- to 300- μm PVA particles ($n = 2$) in an identical manner as that described above for the acute studies. Pigs were then allowed to recover from anesthesia and returned to the veterinary facility. No other procedures were performed on these pigs, either before or after embolization. The chronic Embosphere preparations were done with 700- to 900- μm particles after it became apparent from the acute studies that the 100- to 300- μm particles easily passed through the rete into the brain.

At 48 hours and at 4 weeks, one pig embolized with PVA particles and one with Embospheres were anesthetized and catheterized with a diagnostic catheter in a manner identical to that done for preembolization angiography. Bilateral common carotid artery arteriograms were obtained and the pigs were subsequently killed.

The skull base was dissected and allowed to fix before dissection of the rete, in a manner identical to that used for the acute preparations. Standard hematoxylin-eosin stains were used. Tissue reaction to the particles was assessed microscopically in the 48-hour and 4-week specimens by a neuropathologist blinded to the age of the specimen.

Results

Particle Evaluation

Embospheres were uniformly spherical in shape and smooth in appearance. They were

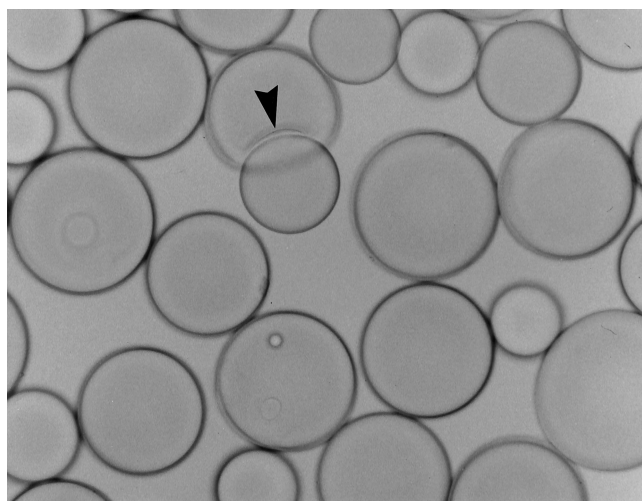


Fig 1. Embospheres (100 to 300 μm) in saline suspension. The particles are uniformly spherical, with the exception of one particle, which appears to be indented by an adjacent sphere (arrowhead). Note the range of particle sizes (original magnification $\times 10$).

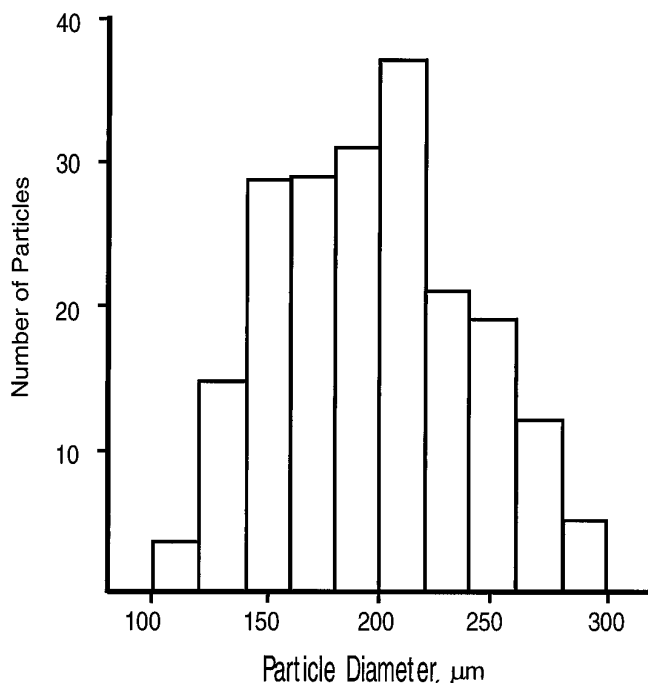


Fig 2. Histogram of Embospheres with diameters of 100 to 300 μm .

easily deformed by a needle and sometimes indented by adjacent particles (Fig 1). No fragments were observed before or after suspension and manipulation.

A range of sizes was observed for the 100- to 300- μm Embosphere particles (Fig 2). The mean particle diameter was 210 μm (standard deviation, 43 μm) and the minimum and max-




Fig 3. Photograph of a 700- to 900- μm Embosphere particle in the distal clear segment of a Tracker-10 catheter (inner diameter, approximately 360 μm) shows the deformability of the Embospheres (original magnification $\times 4$).

imum diameters were 120 μm and 310 μm , respectively ($n = 202$).

Particle Injectability

Sizes up to and including the 700- to 900- μm Embosphere particles suspended well in a solution of 50% saline 50% contrast material and injected easily through the 3F/1.5F microcatheter (minimum inner diameter, 280 μm). The ease of injection was graded as 1 on a scale of 5 (5 for occlusion) for the 100- to 300- μm particles; 2 for the 300- to 500- μm particles; and 3 for both the 500- to 700- μm and 700- to 900- μm particles. Hub accumulation, particle aggregation, or catheter occlusion were not observed. The 200- to 300- μm PVA particles accumulated in the catheter hub after injection of 1 mL and occluded the catheter after 4 mL.

Observation of the 100- to 300- μm and the 700- to 900- μm Embospheres within the Tracker-18 (minimum inner diameter, approximately 530 μm) and the Tracker-10 (minimum inner diameter, approximately 360 μm) catheters revealed deformability of the 700- to 900- μm particles within the smaller catheter (Fig 3). No adherence to the catheter wall was observed.

In Vivo Rete Penetration

A review of the sequential coronal sections from embolized pig rete mirabile showed much deeper penetration of the 100- to 300- μm Embospheres than of the 200- to 300- μm PVA particles (histogram, Fig 4). Many 200- to

300- μ m PVA particles were found in aggregates in the proximal portion of the rete (Fig 5). No PVA particles were observed in the distal half of the rete. The 100- to 300- μ m Embospheres were found in nearly equal density throughout the rete and many passed through into the brain (Fig 6). The average rete arteriole diameter measured 173.3 μ m on the glutaraldehyde-fixed specimen.

The arteriographic correlate of this difference in degree of penetration can be seen in Figure 7.

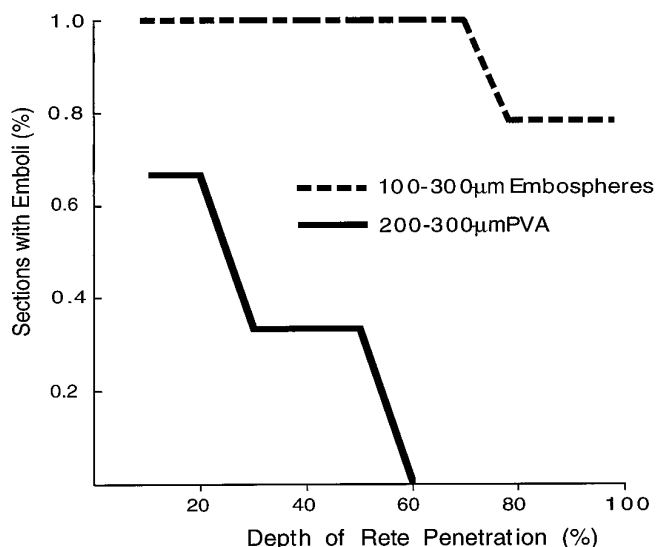
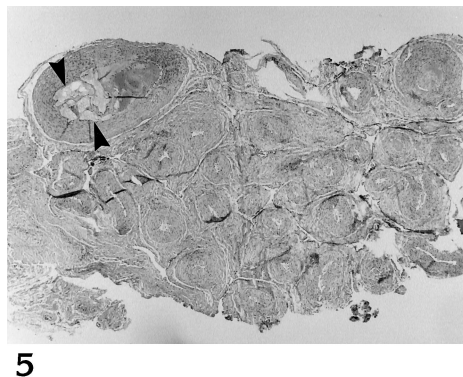


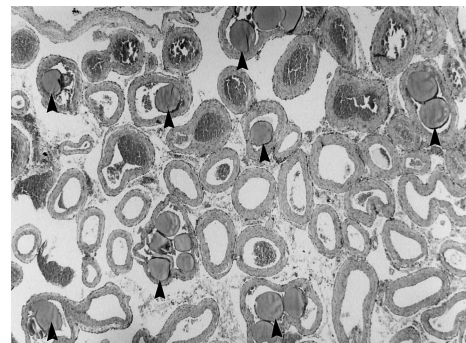
Fig 4. Histogram of depth of particulate penetration. The y-axis plots the percentage of coronal sections containing either PVA or Embosphere particles; the x-axis plots the depth of the section by percent. In the first section, taken at the junction of the ascending pharyngeal artery with the rete, all Embosphere preparations contained particles (100% of sections). Two of three PVA preparations contained particles on the first section (66% of sections). No PVA particles were observed beyond 60% depth. Embospheres were observed in the most distal sections of the rete (100% penetration), at the origin of the internal carotid artery, in three of four preparations (75% of sections).

Fig 5. Photomicrograph of a rete acutely embolized with 200- to 300- μ m PVA particles. This section was the first of seven coronal sections and was taken at the junction of the ascending pharyngeal artery with the rete. A large artery is occluded in the upper left corner of the field. Several clumped particles of PVA are present in the vessel (arrowheads) with adjacent thrombus. No other particles were identified in the field (original magnification $\times 4$).



5

Fig 6. Photomicrograph of a rete acutely embolized with 100- to 300- μ m Embospheres. This section was the fourth of seven 2-mm-thick coronal sections. Several arteries in the field contain the round particles (arrowheads) (original magnification $\times 4$).



6

When occlusion was accomplished with the 200- to 300- μ m PVA particles, good collateral crossflow across the anterior rete was noted in all three cases (Fig 7A). After Embosphere occlusion, however, no filling across the anterior rete was observed in three of four cases (Fig 7B).

Tissue Reaction

Microscopically, we saw no significant difference in tissue reaction between the PVA particles and the Embospheres in either the 48-hour or 4-week specimens. Histologic examination of the retia harvested at 48 hours showed intravascular thrombosis in association with both PVA and Embosphere particles and no vascular inflammation. Fibrin, platelets, and polymorphonuclear leukocytes were identified within the thrombus. Mild intimal reaction adjacent to the thrombus was present.

At 4 weeks, evidence of chronic transmural and perivascular inflammation was observed with both the Embospheres and the PVA particles (Figs 8 and 9). Transmural inflammation included multinucleated giant cells, plasma cells, lymphocytes, and eosinophils in both preparations. Many Embospheres remained present at 4 weeks, both intravascularly and in extravascular spaces. No PVA particles were identified in the 4-week PVA preparation.

Discussion

A variety of microspheres have been developed for use as embolic agents. They have been made from various organic and inorganic materials, including collagen (12), dextran (13), and trisacryl polymer impregnated with gelatin

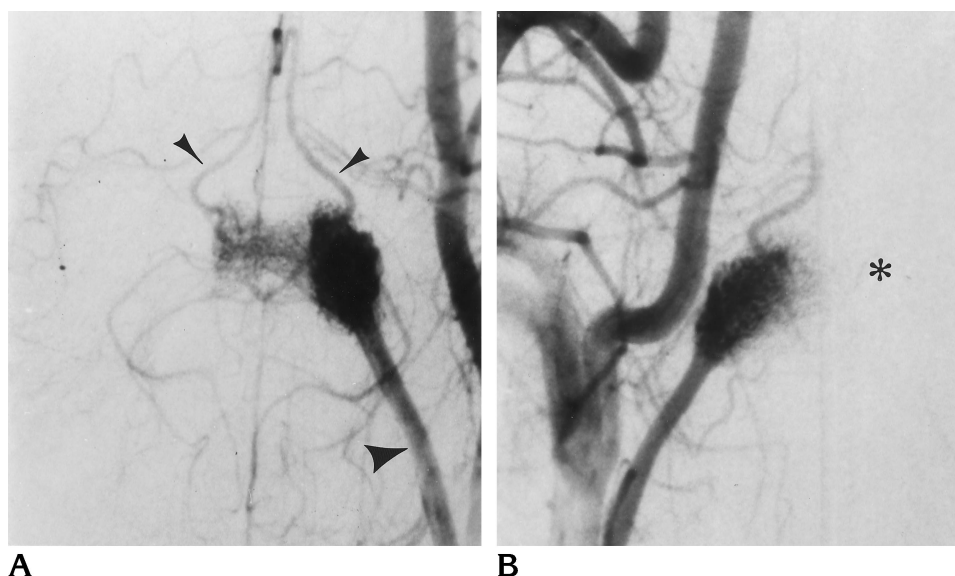


Fig 7. Rete anatomy and angiographic correlate of depth of particulate penetration.

A, Subtracted left common carotid artery angiogram (submental vertex projection) obtained 48 hours after complete embolization of the right rete mirabile with 200- to 300- μ m PVA particles. The left ascending pharyngeal artery (*large arrowhead*) is seen supplying the left rete. The fine mesh of arterioles representing the rete is seen, with flow across midline to supply both internal carotid arteries, which emerge rostrally from the distal rete (*small arrowheads*) (10, 11).

B, Right common carotid artery angiogram obtained after complete embolization of the left rete with 100- to 300- μ m Embospheres. Note the absence of collateral flow across midline (*asterisk*), consistent with more distal penetration of the rete with Embospheres.

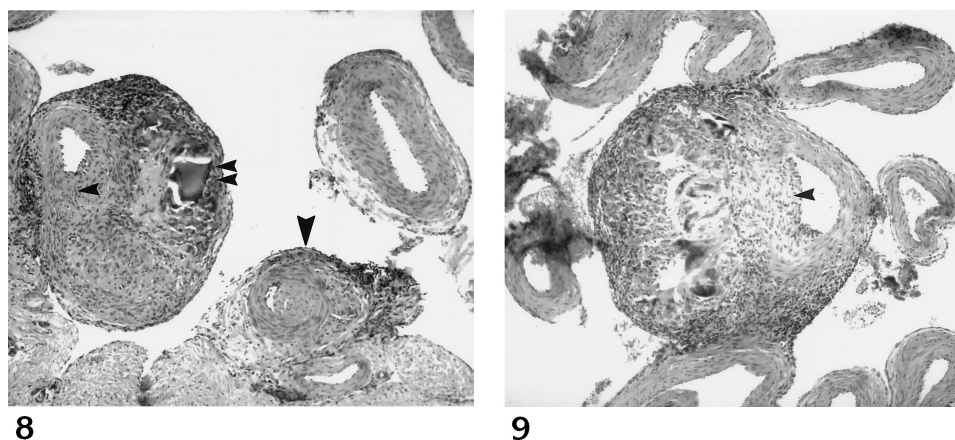


Fig 8. Photomicrograph of a rete 4 weeks after embolization with 700- to 900- μ m Embospheres. Inflammatory cells are present both within the wall of a patent vessel (*single small arrowhead*) and perivascularly. A particle without an identifiable surrounding vessel wall is present within this mass of inflammatory cells (*double small arrowheads*). Other thrombosed vessels may be present with the inflammatory mass. Intravascular thrombosis and perivascular inflammation of lesser magnitude are seen in the lower right corner of the field

(*large arrowhead*) (original magnification $\times 10$).

Fig 9. Photomicrograph of a rete 4 weeks after embolization with 200- to 300- μ m PVA particles. Transmurial inflammatory cells (*arrowhead*) are present in the wall of a patent vessel with extensive associated perivascular inflammation. Other normal vessels can be seen within the field (original magnification $\times 10$).

(14). Microspheres have been subjectively observed to penetrate more deeply into the vasculature of a lesion than PVA particles and may be injected with less difficulty (13, 15). However, no objective evaluation of these qualities or direct comparison with PVA particles has been performed. And many of these microspheres are not widely used or commercially available. In this study we sought to compare objectively the in vivo and in vitro behavior of a commercially available collagen-coated acrylic microsphere with PVA, a well-established and

frequently used embolic agent whose properties and effects are well documented.

Embospheres are uniformly spherical and smooth in appearance, with a narrow range of particle diameters in the sample evaluated. No small fragments were observed. PVA particles are generally oblong or oval, with irregular, sharp, and angulated projections. After suspension, a few small PVA fragments have been noted (9).

The transcatheter delivery of Embospheres was easier than with PVA particles. Hub accu-

mulation and catheter occlusion were not observed with Embospheres, even with particle diameters larger than the minimum inner diameter of a flow-directed catheter. Particles as large as 700 to 900 μm could be injected through a catheter with a minimum inner diameter of 280 μm . Hub accumulation and catheter occlusion occurred in this catheter with 200- to 300- μm PVA particles.

Embospheres of similar size to PVA particles showed remarkable differences in the degree of particulate penetration. Whereas 200- to 300- μm PVA particles often formed aggregates in the distal ascending pharyngeal artery or in the proximal rete, 100- to 300- μm Embospheres completely packed the rete and passed through it. These differences may be attributed to the lack of aggregation, the smooth and hydrophilic surface, and the deformability of the Embosphere particles. These same properties may also account for the relative ease of injection of the particles and the lack of hub accumulation and catheter occlusion observed with Embospheres.

The degree of penetration of PVA particles into a vascular system may be affected by many factors. The advertised size of a PVA particle is primarily a function of its intermediate axis, which is responsible for a given particle's ability to pass through a square sieve hole (9). The long axes of these irregular particles are often much longer than their intermediate axes (9). One might expect that these particles would align their long axis parallel to the flow in a vessel and become wedged at a point at which the vessel diameter is close to the intermediate diameter of the particle. However, Quisling et al (7) have shown that PVA particles *in vivo* tend to adhere to the walls of larger diameter vessels rather than become wedged in a distal vessel. Our results support these observations. In addition, PVA particles tend to clump and aggregate within the catheter hub. Similar accumulations may occur within the vessel at sites of particle adherence. For these reasons, the occlusion achieved with PVA may often occur more proximally than expected within a vessel for a given particle and given luminal diameter.

Our results provide laboratory evidence to support the empirical observations of Beaujeux and coworkers (15) regarding the use of gelatin-coated acrylic microspheres in patients with vascular lesions. They noted that larger and larger microsphere particles were used succes-

sively during an embolization treatment to obtain complete occlusion. They postulated that this process was necessitated by the fact that the physicians' initial choice of particle size was based on experience with PVA particles.

The difference in the degree of particulate penetration has considerable clinical importance. Greater penetration can be advantageous, leading to more effective transarterial embolization of many lesions. Presurgical embolization of meningiomas may constitute an ideal application for Embospheres, as there may be less potential for proximal vessel occlusion and subsequent need to develop collateral dural supply before surgery. However, lesions with evidence of arteriovenous shunting will need to be approached with great caution. Choosing a size of Embosphere solely on the basis of experience with PVA particles could result in significant distal embolization (ie, pulmonary embolization) as a result of shunting through the lesion. The response of the pulmonary circulation to Embosphere embolization is not known. Until more is understood about the optimal size of Embospheres for a given vessel diameter and the consequences of pulmonary embolization, the use of Embospheres for treatment of lesions with arteriovenous shunting, such as arteriovenous malformations, cannot be recommended.

Both the Embospheres and PVA particles incited a moderate transmural inflammatory response. Turjman and coworkers (12) observed a similar pattern of transmural and adventitial inflammation in the pig rete at 3 to 5 weeks after embolization with collagen microspheres. This inflammation may be due in part to effects of vessel occlusion and/or accompanying thrombus. Whether the collagen coating itself is responsible for the inflammatory response is not known. PVA may elicit a mild inflammatory reaction, particularly when the embolized vessel is completely occluded (4, 7, 16). When PVA particles are not occlusive, they may not elicit any inflammatory response (7). No PVA particles were identified in the 4-week specimen in our study, which may have been due to occlusion of the rete at the distal ascending pharyngeal artery, an area that was not included in the dissected specimen.

In summary, collagen-coated acrylic microspheres may offer some advantages over PVA particles for the embolization of vascular lesions with no evidence of arteriovenous shunting.

Embospheres are uniformly spherical and smooth with a narrow range of particle diameters for a given size. Their transcatheter delivery is easier and less complicated by particulate aggregation and catheter occlusion than are PVA particles. Embospheres can be injected through small flow-directed catheters. The chronic tissue reaction observed with Embospheres is similar to that seen with PVA. For a given particle and vessel size, Embospheres penetrate to a much greater extent than PVA particles. The major disadvantage of Embospheres lies in their potential to pass through a lesion to the pulmonary circulation. Until more is known about their optimal size and their effect on the pulmonary circulation, great caution should be exercised in using Embospheres to treat lesions with evidence of arteriovenous shunting.

References

1. Tadavarthy SM, Moller JH, Amplatz K. Polyvinyl alcohol (Ivalon): a new embolic material. *AJR Am J Roentgenol* 1975;125:609-616
2. Tadavarthy SM, Coleman CC, Hunter D, Casteneda-Zuniga WR, Amplatz K. Polyvinyl alcohol (Ivalon) as an embolic agent. *Semin Intervent Radiol* 1984;1:101-109
3. Lanman TH, Martin NA, Vinters HV. The pathology of encephalic arteriovenous malformations treated by prior embolotherapy. *Neuroradiology* 1988;30:1-10
4. White RI, Strandberg JV, Gross GS, Barth KH. Therapeutic embolization with long-term occluding agents and their effects on embolized tissues. *Radiology* 1977;125:677-687
5. Chuang VP, Tsai CC, Wright K, Wallace S, Charnsanavej C. Experimental canine hepatic artery embolization with polyvinyl alcohol foam particles. *Radiology* 1982;145:21-25
6. Scialfa G, Scotti G. Superselective injection of polyvinyl alcohol microemboli for the treatment of cerebral arteriovenous malformations. *AJNR Am J Neuroradiol* 1985;6:957-960
7. Quisling RG, Mickle JP, Ballinger WB, Carver CC, Kaplan B. Histopathologic analysis of intraarterial polyvinyl alcohol microemboli on rat cerebral cortex. *AJNR Am J Neuroradiol* 1984;5:101-104
8. Jack CR, Forbes G, Dewanjee MK, Brown ML, Earnest F. Polyvinyl alcohol sponge for embolotherapy: particle size and morphology. *AJNR Am J Neuroradiol* 1985;6:595-597
9. Derdeyn CP, Moran CJ, Cross DT III, Dietrich HH, Dacey RG Jr. Polyvinyl alcohol particle size and suspension characteristics. *AJNR Am J Neuroradiol* 1995;16:1335-1343
10. Daniel PM, Dawes JDK, Prichard MML. Studies of the carotid rete and its associated arteries. *Philos Trans R Soc Lond [Biol]* 1953;237B:173-208
11. Gillian LA. Blood supply to brains of ungulates with and without a rete mirabile caroticum. *J Comp Neurol* 1974;153:275-290
12. Turjman F, Massoud TF, Vinters HV, et al. Collagen microbeads: experimental evaluation of an embolic agent in the rete mirabile of the swine. *AJNR Am J Neuroradiol* 1995;16:1031-36
13. Dion JE, Rankin RN, Vinuela F, Fox AJ, Wallace AC, Mervart M. Dextran microsphere embolization: experimental and clinical experience with radiologic-pathologic correlation. *Radiology* 1986;160:717-721
14. Laurent A, Beaujeux R, Wassef M, Rufennacht D, Boschetti E, Merland J-J. Trisacryl gelatin microspheres for therapeutic embolization, I: development and in vitro evaluation. *AJNR Am J Neuroradiol* 1996;17:533-540
15. Beaujeux R, Laurent A, Wassef M, Casasco A, Gobin Y-P, Aymard A, Rufennacht D, Merland J-J. Trisacryl gelatin microspheres for therapeutic embolization, II: clinical evaluation in tumors and arteriovenous malformations. *AJNR Am J Neuroradiol* 1996;17:541-548
16. Casteneda-Zuniga WR, Sanchez R, Amplatz K. Experimental observations on short- and long-term effects of arterial occlusion with Ivalon. *Radiology* 1978;126:783-785