

Generic Contrast Agents

Our portfolio is growing to serve you better. Now you have a *choice*.



[VIEW CATALOG](#)

AJNR

MR of multiple intraspinal abscesses associated with congenital dermal sinus.

R Dev, M Husain, A Gupta and R K Gupta

AJNR Am J Neuroradiol 1997, 18 (4) 742-743

<http://www.ajnr.org/content/18/4/742>

This information is current as
of May 21, 2025.

MR of Multiple Intraspinal Abscesses Associated with Congenital Dermal Sinus

Ravi Dev, M. Husain, A. Gupta, and R. K. Gupta

Summary: We describe the MR features in a case of multiple intraspinal abscesses involving almost the whole of the spinal cord in a 3-year-old child. The presence of a dermal sinus helped us in the preoperative diagnosis.

Index terms: Spine, abscess; Spinal cord, infection

Intramedullary spinal cord abscesses are uncommon. When no demonstrable cause is present, they are referred to as *primary abscesses*; when there is a detectable cause, like trauma, dermal sinus, or any other focus of infection in the body, they are referred to as *secondary abscesses* (1). The magnetic resonance (MR) imaging features in the occasional case of intramedullary abscess have been described (2). We present a case of multiple intraspinal abscesses caused by an infection of the dermal sinus involving the cervicothoracic spinal cord.

Case Report

A 3-year-old girl had had weakness of both lower limbs for a period of 1 month that had progressed to involve both upper limbs over the ensuing 2 weeks. Fever was the initial sign, occurring 1 week before any neurologic deficit developed. Her parents had also noted a pinhole in the lower thoracic region of her back that discharged yellowish material. On examination, she was fully conscious and had quadriparesis of the upper motor neuron type. No evidence of cranial nerve involvement was seen. Laboratory investigations showed leucocytosis with neutrophilia. Results of a cerebrospinal fluid study were unremarkable.

MR imaging of the spine was done on a 1.5-T superconducting system with an oval spine coil. T1-weighted (580/15/3 [repetition time/echo time/excitations]) proton density-weighted (2200/20/1), and T2-weighted (2200/80/1) sagittal images were obtained with a 256 × 256 matrix, 3-mm section thickness, and 0.3-mm intersection

gap. Contrast-enhanced T1-weighted sagittal images were obtained after injection of gadopentetate dimeglumine, 0.1 mmol/kg body weight. MR imaging of the cervicothoracic spine showed skip areas of hyperintensity on T2-weighted images that also appeared slightly hypointense on T1-weighted images (Fig 1A and B). The postcontrast study showed multiple areas of rim enhancement in the lesions (Fig 1C). These areas extended from the cervicomedullary junction to the upper lumbar spinal cord. The postcontrast study also showed the sinus at the level of the 11th dorsal vertebra (Fig 1D).

At surgery, the dermal sinus tract was excised. Pus was aspirated from the abscess cavities in the vicinity of the sinus tract under sonographic guidance and sent for culture, which revealed *Staphylococcus aureus*. Scrapings from the wall of the abscess cavity revealed only inflammatory cells. After surgery, the patient made a partial recovery and continued taking antibiotics for 6 weeks. She was lost to further follow-up study.

Discussion

Infection is the most serious risk associated with congenital dermal sinus. It can result in meningitis, extradural, subdural, or intramedullary abscesses, or infection of an affiliated tumor (3). Dermoid tumor may arise within a focal area of expansion along the tract in approximately half the cases of dermal sinus (3). Intraneural abscess tends to extend a great distance up and down the cord rather than remain localized to the site of the dermal sinus (3). *Staphylococcus aureus* is the most common infecting organism in these cases (3). Our patient had a dermal sinus in the lower dorsal region with multiple abscesses extending from the cervicomedullary junction to the 12th thoracic vertebra.

In the brain, the abscess cavity usually appears hyperintense with a hypointense rim on

Received May 1, 1996; accepted after revision August 14.

From the Department of Neurosurgery, King George's Medical College (R.D., M.H.), and the Department of Radiology, Sanjay Gandhi Post-Graduate Institute of Medical Sciences (A.G., R.K.G.), Lucknow, India.

Address reprint requests to Rakesh K. Gupta, MD, MR Section, Department of Radiology, SGPGIMS, Lucknow, 226 014, India.

AJNR 18:742-743, Apr 1997 0195-6108/97/1804-0742 © American Society of Neuroradiology

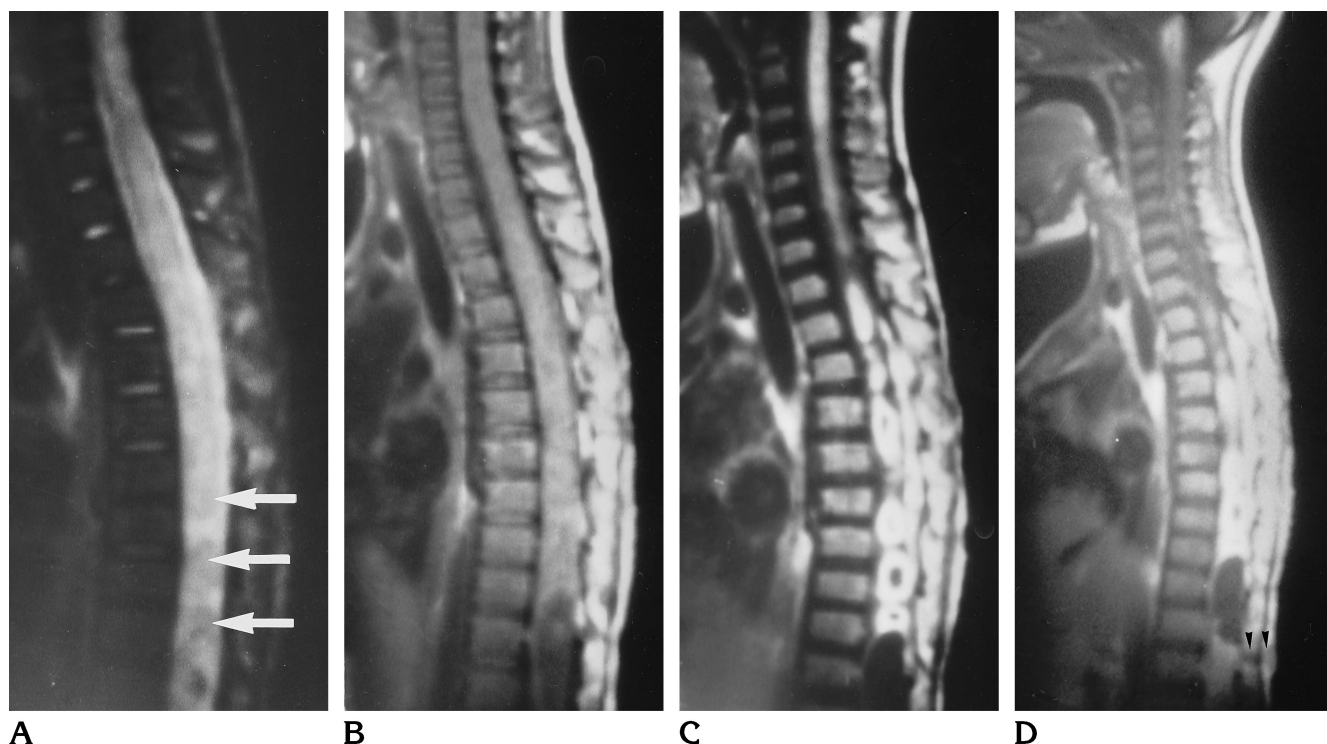


Fig 1. A 3-year-old girl with multiple intramedullary abscesses with dermal sinus.
 A, Sagittal T2-weighted MR image shows areas of mild hyperintensities (arrows) surrounded by higher hyperintense signal with expansion of the spinal cord.
 B, Sagittal T1-weighted MR image shows multiple hypointense signals surrounded by hyperintensity, corresponding to T2-weighted image.
 C, Postcontrast T1-weighted MR image shows rim enhancement of mildly hyperintense areas visible on the T2-weighted image in the dorsal region along with thick linear enhancement of the cervical spinal cord.
 D, Right parasagittal postcontrast T1-weighted MR image shows the dermal sinus (arrowheads).

T2-weighted images and hypointense on T1-weighted images; postcontrast studies show rim enhancement (4). The degree of hyperintensity of an abscess depends on the viscosity and the protein content of the pus. In the present case, the abscess showed mild hyperintensity on T2-weighted images. The pus, which appeared thick while being aspirated, might have been the cause of the mildly hyperintense signal in this case.

The differential diagnosis of multiple ring-enhancing intraspinal lesions includes tuberculosis, histoplasmosis, sarcoidosis, multiple sclerosis, inflammatory myelitis, and viral infections (5). In our case, multiple ring-enhancing lesions were caused by intraspinal abscesses involving the cervical and thoracic spinal cord.

We conclude that the manifestation of multi-

ple ring-enhancing lesions on MR images of the spinal cord, along with the presence of a dermal sinus, should help in the preoperative diagnosis of multiple intraspinal abscesses.

References

1. Menezes AH, VanGilder JC. Spinal cord abscess. In: Wilkins RH, Rengachary SS, eds. *Neurosurgery*. New York, NY: McGraw-Hill; 1985:1969-1972
2. King SJ, Jeffrey MA. MRI of an abscess of the cervical spinal cord in a case of listeria meningoenophalomyelitis. *Neuroradiology* 1993;35:101-102
3. French BN. Midline fusion defects and defects of formation. In: Youmans JR, ed. *Neurological Surgery*. Philadelphia, Pa: Saunders; 1990:1081-1235
4. Haimes AB, Zimmerman RD, Morgello S, et al. MR imaging of brain abscesses. *AJNR Am J Neuroradiol* 1989;10:279-291
5. Amour TE, Hodges SC, Leakman RW, Tamas DE. *MRI of the Spine*. New York, NY: Raven Press; 1994:352-360