

Generic Contrast Agents

Our portfolio is growing to serve you better. Now you have a *choice*.



[VIEW CATALOG](#)

AJNR

Granulomatous amebic encephalitis caused by leptomyxid amebae in an HIV-infected patient.

M T Zagardo, R J Castellani, G H Zoarski and S C Bauserman

This information is current as of May 19, 2025.

AJNR Am J Neuroradiol 1997, 18 (5) 903-908
<http://www.ajnr.org/content/18/5/903>

Granulomatous Amebic Encephalitis Caused by Leptomyxid Amebae in an HIV-Infected Patient

Michael T. Zagardo, Rudy J. Castellani, Gregg H. Zoarski, and Steven C. Bauserman

Summary: MR images of granulomatous amebic encephalitis caused by leptomyxid amebae in an HIV-infected patient showed both heterogeneous and ring-enhancing hemorrhagic lesions. The brain was diffusely involved, including the brain stem, deep gray matter nuclei, and corticomedullary junction regions of all lobes.

Index terms: Brain, infection; Encephalitis; Acquired immunodeficiency syndrome (AIDS)

Infections in humans caused by free-living amebae of the genera *Naegleria* or *Acanthamoeba* were described in 1965 by Fowler and Carter (1) and in 1966 by Butt (2). Types of infection caused by these organisms include primary amebic meningoencephalitis and granulomatous amebic encephalitis (GAE). We describe the MR and corresponding pathologic findings of GAE resulting from *Balamuthia mandrillaris*.

Case Report

A 34-year-old human immunodeficiency virus (HIV)-positive woman came to the emergency department after she collapsed at home with a grand mal tonicoclonic seizure. She had no history of opportunistic infection, was taking no medications, and had no significant travel history. On presentation, she was febrile (101.7°F) with a subtle right seventh nerve palsy and a mild right pronator drift. Laboratory results included normal electrolytes, liver enzymes, and white blood cell count. Cerebrospinal fluid analysis was notable for protein of 1.7 g/L, glucose of 3.1 mmol/L, and a pronounced lymphocytic pleocytosis of 91%. CD4 count was 738 μ L (normal, 600 to 2100 μ L). Initial magnetic resonance (MR) images showed 13 enhancing lesions involving the pons, thalamus, cerebellum, and corticomedullary junction regions of all lobes (Fig 1A–E). All lesions had T1 hypointensity and T2 hyperintensity with moderate surrounding edema. Enhancement was homogeneous and nodular and/or linear and ringlike.

Several lesions had a rim of T2 hypointensity that corresponded to areas of enhancement. These lesions were initially thought to represent abscesses caused by hematogenous spread of bacteria or fungi. Infection caused by *Toxoplasma* organisms was unlikely because the patient's CD4 count was greater than 200. High-dose ceftriaxone and metronidazole therapy was not successful.

Results of a percutaneous biopsy of a right frontal lobe lesion showed necrotizing inflammation with rare organisms suggestive of *Acanthamoeba* species. Immunofluorescent stains performed on biopsy tissue at the Centers for Disease Control (Atlanta, Ga) failed to confirm this. However, because of the very high suspicion of GAE caused by free-living amebae, we replaced the patient's antimicrobial regimen with intravenous miconazole nitrate (800 mg three times a day), oral rifampin (600 mg three times a day), and intravenous pentamidine (340 mg every day). Her condition worsened. A repeat MR study showed diminished to absent enhancement within all preexisting lesions (Fig 1F–H). There were areas of nodular or ringlike increased T1 signal intensity within some of the lesions, suggesting the presence of methemoglobin or another paramagnetic substance. She died 24 days after admission.

A complete autopsy showed that significant findings were isolated to the central nervous system (CNS); systemic organs showed no abnormalities. The brain weighed 1380 g, with diffuse edema and multiple foci of hemorrhage and softening. Axial sections of the brain stem and cerebellum were remarkable for a large central pontine lesion with prominent peripheral vascular congestion, hemorrhage, and central necrosis (Fig 1I). Axial sections of the cerebrum showed multiple, bilateral hemorrhagic lesions with central necrosis, largely within the gray matter and subjacent white matter (Fig 1J). Microscopic examination showed a necrotizing meningoencephalitis with amebic cysts and trophozoites in all lesions accompanied by a prominent lymphocytic infiltrate with occasional neutrophils (Fig 1K and L). Granulomatous inflammation was absent. Organisms were found in large numbers infiltrating perivascular spaces and occasionally invading vessel walls. Thrombosis and fibrinoid necrosis of blood vessels

Received April 24, 1996; accepted after revision August 13.

From the Departments of Radiology (M.T.Z., G.H.Z.) and Pathology (R.J.C., S.C.B.), University of Maryland Medical Center, Baltimore.

Address reprint requests to Michael T. Zagardo, MD, Department of Diagnostic Radiology, University of Maryland Medical Center, 22 S Greene St, Baltimore, MD 21201.

AJNR 18:903–908, May 1997 0195-6108/97/1805-0903 © American Society of Neuroradiology

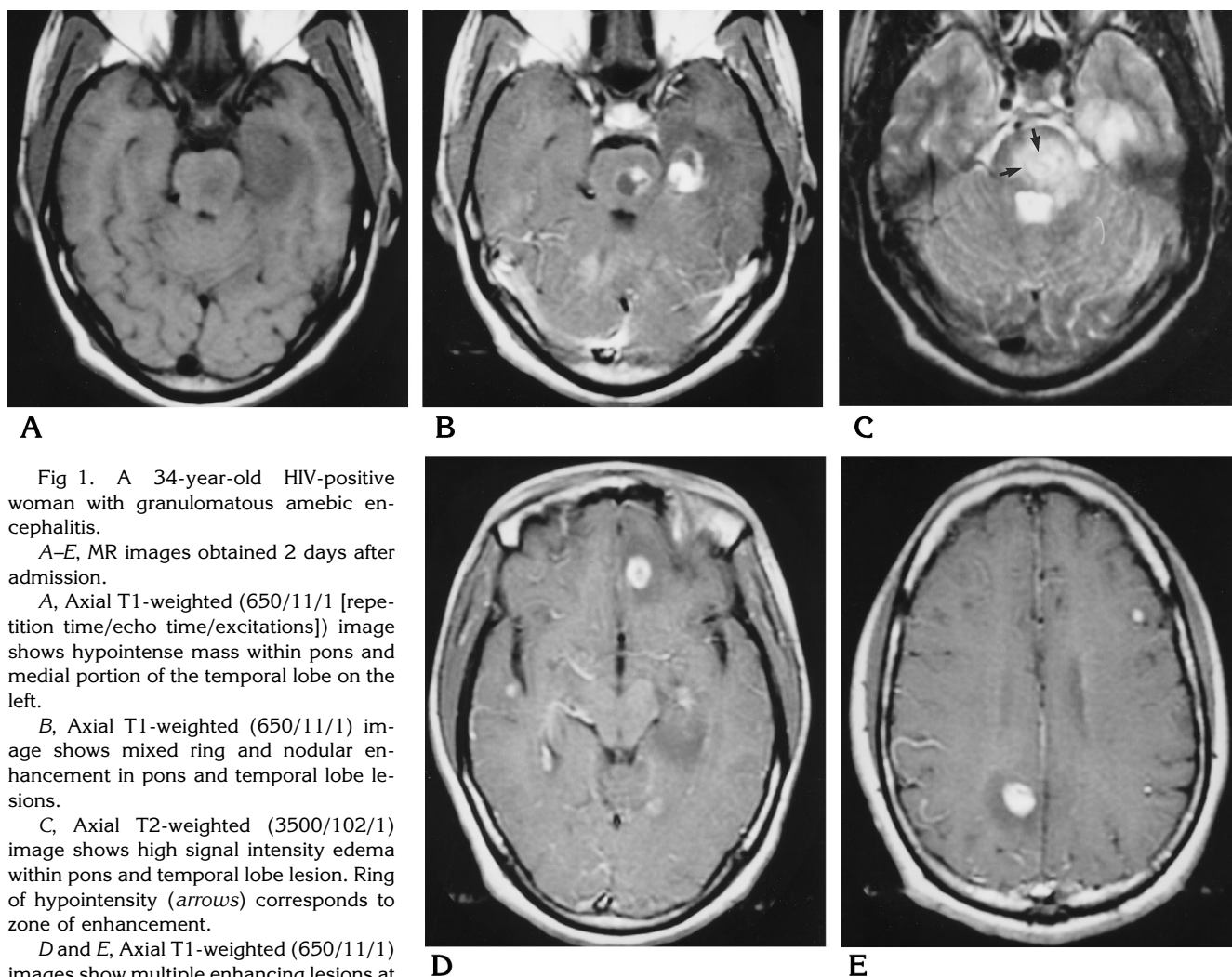


Fig 1. A 34-year-old HIV-positive woman with granulomatous amebic encephalitis.

A–E, MR images obtained 2 days after admission.

A, Axial T1-weighted (650/11/1 [repetition time/echo time/excitations]) image shows hypointense mass within pons and medial portion of the temporal lobe on the left.

B, Axial T1-weighted (650/11/1) image shows mixed ring and nodular enhancement in pons and temporal lobe lesions.

C, Axial T2-weighted (3500/102/1) image shows high signal intensity edema within pons and temporal lobe lesion. Ring of hypointensity (arrows) corresponds to zone of enhancement.

D and E, Axial T1-weighted (650/11/1) images show multiple enhancing lesions at corticomedullary junction of frontal, temporal, and parietal lobes with associated moderate vasogenic edema. *Figure continues.*

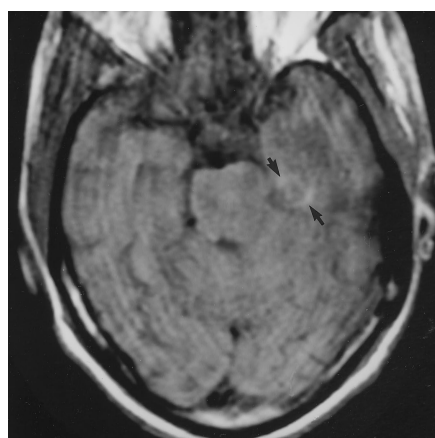
indicated vasculitis as a dominant feature. Immunofluorescent stains performed at the Centers for Disease Control, as well as ultrastructural examination of cysts and trophozoites, indicated *Balamuthia mandrillaris* as the infectious agent.

Discussion

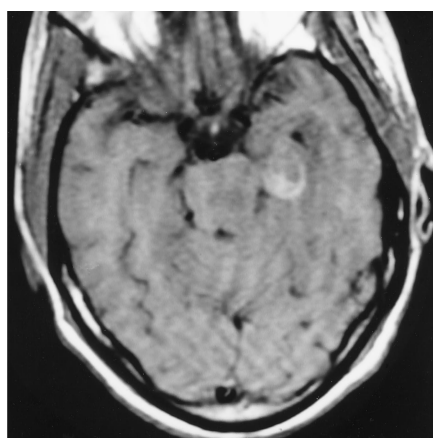
Acanthamoeba and *Naegleria* are two of the most common genera of free-living amebae known to cause disease in humans. *Naegleria* organisms are best known for causing fatal primary amebic meningoencephalitis, which is an acute, hemorrhagic, necrotizing meningoencephalitis usually occurring in previously healthy children and young adults (3). The or-

ganism gains access to the CNS by penetrating olfactory epithelium in a person who has swum in standing, contaminated water (4). Subarachnoid invasion occurs via the olfactory bulbs and tracts (5). Patients have acute onset of severe headache, fever, lethargy, nausea, and vomiting. The clinical course is one of rapid deterioration and death within 48 to 72 hours.

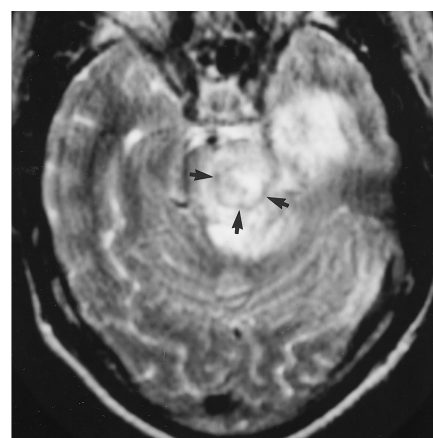
GAE is a subacute to chronic infection most frequently caused by *Acanthamoeba* organisms, but also by amebae of the order Leptomyxida (6). GAE is probably an opportunistic infection affecting chronically ill, debilitated persons with impaired immunity and has a more insidious onset than primary amebic meningoencephalitis, with fever, headache, and fo-



F



G



H

Fig 1, continued.

F-H, MR images obtained 19 days after admission.

F, Unenhanced axial T1-weighted image shows hypointensity within the pons and ringlike hyperintensity in temporal lobe lesion (arrows), the latter indicating paramagnetic effect. Peripheral hemorrhage within temporal lobe lesion was confirmed histopathologically.

G, Contrast-enhanced axial T1-weighted image shows mild to moderate mixed solid/ring enhancement of temporal lobe lesion. The pons lesion enhanced slightly (not visible on this section).

H, Axial T2-weighted image shows moderate edema. Thin rim of hypointensity (arrows) corresponds to abscess wall and indicates presence of paramagnetic substance.

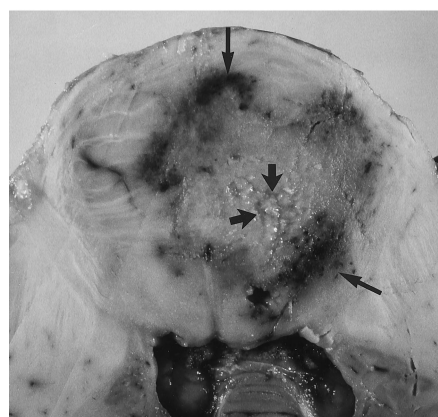
I and J, Gross pathologic specimens.

I, Axial gross section of formalin-fixed brain at the level of the mid pons and cerebellum shows a large pontine abscess. There is central necrosis (short arrows) and peripheral zone of intense vascular congestion and hemorrhage (long arrows).

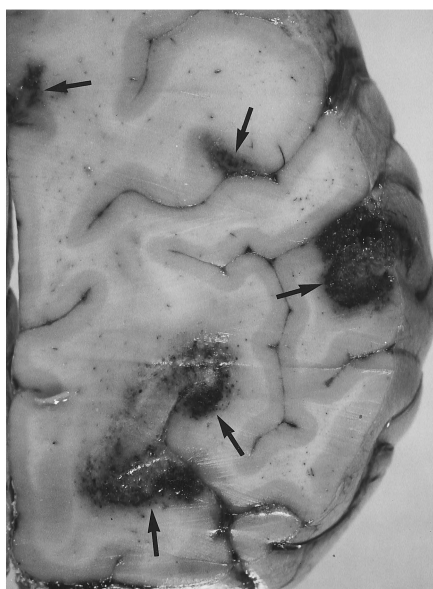
J, Axial section of the left frontal and parietal lobes shows multiple hemispheric lesions involving cortex and subcortical white matter (arrows). The lesions contain central necrosis surrounded by a peripheral zone of congestion and hemorrhage.

K and L, Photomicrographs.

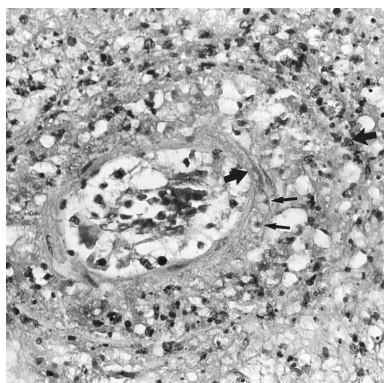
K, A focus of vasculitis with endothelial hyperplasia and necrosis of the media. The media is denoted by thick arrows. Note infiltration of the blood vessel wall by amebic organisms (thin arrows) (hematoxylin-eosin, original magnification $\times 200$).



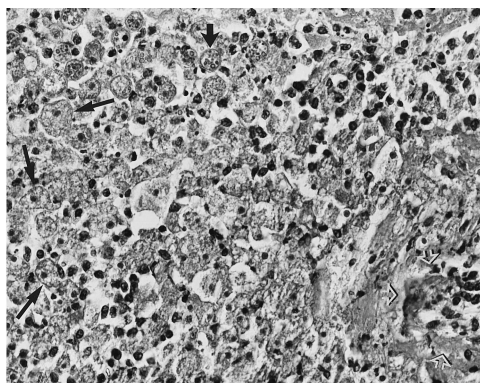
I



J



K



L

L, Numerous amebic cysts and trophozoites (long thin arrows), some with erythrophagocytosis (short wide arrow). Blood vessel in the lower right corner shows necrotizing vasculitis (open arrows) (hematoxylin-eosin, original magnification $\times 200$).

cal findings the prominent features (7). The course of the syndrome, as exemplified by the present case, typically lasts weeks to months and is one of progressive deterioration ultimately leading to death.

One of the etiologic agents of GAE, *Acanthamoeba* organisms, has been isolated from almost every environmental niche including air, dust, soil, tap and bottled water, sewage, air-conditioning filters, dialysis units, aquariums, toxic-waste dump sites, contact lens paraphernalia, and chlorinated pools (8). The organism can be found in the upper respiratory tracts of both symptomatic and asymptomatic patients and usual portals of entry include the sinuses, lungs, skin, or genitourinary tract (7, 9, 10). Involvement of the brain, intestines, prostate, uterus, pancreas, and kidneys in sick patients is best explained by hematogenous spread. The corticomedullary junction location of many of the lesions seen in our patient also suggests hematogenous spread of infection; however, no other organ involvement was detected at autopsy and the portal of entry was not determined. Given the patient's history of recreational intravenous drug use, a potential source includes intravenous injection of contaminated substances.

Focal brain abscesses associated with *Leptomyxida* and *Acanthamoeba* organisms have also been reported in immunocompetent patients. So-called spontaneous GAE may be associated with malnutrition or a more virulent strain of organism. Amebic meningoencephalitis is rare in HIV-infected patients and usually occurs in patients with advanced acquired immunodeficiency syndrome (AIDS). Our patient, while infected with HIV, had no history of opportunistic infection and a normal CD4 lymphocyte count. A case of GAE in an HIV-infected patient with AIDS was in 1987 (11). Since then, there have been at least six additional reports of GAE in AIDS patients within the United States, including one case of GAE caused by *Leptomyxida* (12–16) (C. M. Weldon-Linne, B. A. Tan, D. P. Rhone, C. L. Penning, G. S. Visvesvara, "Acanthamoeba sp. infection presenting as skin lesions in patients with AIDS," *Am J Clin Pathol* 1992;97:460 [abstract]). One other case has been reported from Italy (17). All these patients were men with CD4 cell counts less than 200. This case report establishes the fact that a normal CD4 lymphocyte count in an HIV-

infected patient does not exclude GAE, especially if caused by a leptomyxid ameba.

There has been extensive documentation of the gross and histopathologic findings of GAE. Lesions are often multifocal, located in the cerebellum, basal ganglia, thalamus, pons, midbrain, and cerebral hemispheric subcortical white matter. The olfactory bulbs and inferior frontal lobes are usually spared, in contrast to primary amebic meningoencephalitis (18). Microscopically, there is mild chronic or subacute leptomeningitis, which is most prominent adjacent to parenchymal lesions. The characteristic CNS lesion is a necrotizing subacute or chronic granulomatous encephalitis in which trophozoites and cysts are found in association with giant cells. Granulomatous inflammation may be absent in immunocompromised hosts, most likely reflecting an impairment in cellular immunity, although in our case the CD4 count was in the normal range. Large numbers of trophozoites and cysts may be present within perivascular spaces of affected areas. There may be severe angiitis and amebic organisms may pierce vessel walls, resulting in necrotizing vasculitis and mycotic aneurysms (19).

Contrary to the large volume of pathologic literature addressing the findings of GAE, little has been written about the imaging findings. Sporadic case reports describing the computed tomographic characteristics of lesions typically describe solitary or multiple enhancing lesions that may have the appearance of multiple infarcts, septic emboli, or mass lesions (7, 14, 15, 18–22). Lesions do not always enhance, perhaps because of the hosts' inability to mount an immune response, especially in patients with AIDS (8). One case report describing the MR manifestations of GAE described a homogeneously enhancing pontine lesion mimicking a brain stem glioma in an 11-month-old immunocompetent infant, caused by leptomyxid amebae (23).

Initial MR findings of CNS lesions consequent to GAE in our patient were essentially identical to imaging findings of areas of cerebritis and abscess formation caused by other pyogenic organisms. Smaller lesions had solid enhancement whereas larger lesions showed nodular and/or ring enhancement. There was a moderate amount of associated edema manifested by surrounding T2 hyperintensity. On the follow-up MR study, several of the lesions had a ring of diminished T2 signal intensity that cor-

responded to the area of ring enhancement on postcontrast T1-weighted images. Previous reports have described this appearance in pyogenic abscesses (24, 25). The hypointense T2 rim is typically present in mature and chronic abscesses and is postulated to represent the generation of paramagnetic substances by macrophages within the abscess capsule undergoing a respiratory burst (24). Other CNS lesions in this patient had areas of T2 hypointensity. Similar hypointense areas have been described with CNS tuberculomas, intracranial aspergillosis, and treated toxoplasmosis encephalitis (26–28). In the case of *Aspergillus fumigatus*, diminished T2 signal may be attributable to this organism's ability to concentrate metal elements that cause magnetic susceptibility effects (29). Alternatively, coagulative necrosis and vasculitis with resultant hemorrhage and the presence of blood breakdown products could cause a similar appearance. This latter mechanism probably explains hemorrhagic toxoplasmosis lesions and may be the cause of the hemorrhagic lesions in our patient. The presence of hemorrhage is noteworthy, since spontaneous hemorrhage into abscesses caused by typical pyogenic organisms is rarely encountered clinically or documented pathologically, and suggests infection by organisms causing vasculitis (30).

GAE has a dismal prognosis. Of the 60 or so reported cases, there have been no survivors treated with medical therapy alone. One report documented the survival of a previously healthy 7-year-old girl with a confined left frontoparietal granuloma caused by *Acanthamoeba* infection (20). A favorable outcome was obtained after total excision of the mass and treatment with ketoconazole. That case of a surviving patient with GAE due to *Acanthamoeba* organisms is highly unusual because the presence of multiple lesions in vital areas of the brain precludes surgery as a therapeutic option. Harwood et al (31) described a patient with five discrete *Acanthamoeba*-induced brain abscesses who was treated with 5-fluorocytosine and rifampicin and partial drainage of a large occipital lobe lesion; these authors report that the patient may have survived if she had not succumbed to necrotizing enteritis.

In summary, while relatively uncommon in HIV-infected patients, GAE is a differential consideration in these persons with or without the diagnosis of AIDS, especially if there is MR ev-

idence of intralesional hemorrhage. CNS infection caused by *Toxoplasma* organisms, angioinvasive fungi such as those of *Aspergillus*, and other organisms causing vasculitis can produce a similar radiologic appearance.

References

1. Fowler M, Carter RF. Acute pyogenic meningitis probably due to *Acanthamoeba*: a preliminary report. *Br Med J* 1965;2:740–742
2. Butt CG. Primary amebic meningoencephalitis. *N Engl J Med* 1966;274:1473–1476
3. Willaert E. Primary amoebic meningoencephalitis: a selected bibliography and tabular survey of cases. *Ann Soc Belg Med Trop* 1974;54:429–440
4. Martinez AJ. Free-living amoeba: pathogenic aspects. A review. *Protozool Abstr* 1983;7:293–306
5. Duma RJ, Ferrell HW, Nelson EC, Jones MM. Primary amebic meningoencephalitis. *N Engl J Med* 1969;281:1315–1323
6. Visvesvara GS, Martinez AJ, et al. Leptomyxid amoeba, a new agent of amebic meningoencephalitis in humans and animals. *J Clin Microbiol* 1990;28:2750–2755
7. Martinez AJ. Is *Acanthamoeba* encephalitis an opportunistic infection? *Neurology* 1980;30:567–574
8. DeJonckheere JF. Ecology of *Acanthamoeba*. *Rev Infect Dis* 1991;13(Suppl 5):S385–S387
9. Cerva L, Serbus C, Skocil V. Isolation of limax amoebae from the nasal mucosa of man. *Folia Parasitol (Praha)* 1973;20:97–103
10. Ma P, Visvesvara GS, Martinez AJ, Theodore FH, Daggett PM, Sawyer TK. *Naegleria* and *Acanthamoeba* infections: review. *Rev Infect Dis* 1990;12:490–513
11. Wiley CA, Safran RE, David CE, et al. *Acanthamoeba* meningoencephalitis in a patient with AIDS. *J Infect Dis* 1987;155:130–133
12. Robinson G, Wilson SE, Williams RA. Surgery in patients with acquired immunodeficiency syndrome. *Arch Surg* 1987;122:170–175
13. Gardner HAF, Martinez AJ, Visvesvara GS, Sotrel A. Granulomatous amebic encephalitis in an AIDS patient. *Neurology* 1991;41:1993–1995
14. Anzil A, Rao C, Wrzolek M, Visvesvara G, Sher J, Kozlowski P. Amebic meningoencephalitis in a patient with AIDS caused by a newly recognized opportunistic pathogen. *Arch Pathol Lab Med* 1991;115:21–25
15. Gordon S, Steinberg J, DuPuis M, Kozarski P, Nickerson J, Visvesvara G. Culture isolation of *Acanthamoeba* species and Leptomyxid amoebas from patients with amebic meningoencephalitis, including two patients with AIDS. *Clin Infect Dis* 1992;15:1024–1030
16. Tan B, Weldon-Linne CM, Rhone DP, Penning CL, Visvesvara GS. *Acanthamoeba* infection presenting as skin lesions in patients with acquired immunodeficiency syndrome. *Arch Pathol Lab Med* 1993;117:1043–1046
17. DiGregorio C, Rivosi F, Mongiardo N, DeRienzo B, Wallace S, Visvesvara G. *Acanthamoeba* meningoencephalitis in a patient with acquired immunodeficiency syndrome. *Arch Pathol Lab Med* 1992;116:1363–1365
18. Martinez AJ. Infection of the central nervous system due to *Acanthamoeba*. *Rev Infect Dis* 1991;13(Suppl 5):5344–5402
19. Martinez AJ, Sotelo-Avila C, Alcala H, Willaert E. Granulomatous encephalitis, intracranial arteritis and mycotic aneurysm due to a free living amoeba. *Acta Neuropathol (Berl)* 1980;49:7–12

20. Kwame Ofori-Kwakye S, Sidebottom D, Herbert J, Fischer E, Visvesvara G. Granulomatous brain tumor caused by *Acanthamoeba*. *J Neurosurg* 1986;64:505-509
21. Martinez AJ, Guerra AE, Garcia-Tamaro J, Cispedes G, Gonzalez-Alfonzo JE, Visvesvara GS. Granulomatous amebic encephalitis: a review and report of a spontaneous case from Venezuela. *Acta Neuropathol (Berl)* 1994;87:430-434
22. Schumacher J, Tien R, Lane K. Neuroimaging findings in rare amebic infections of the central nervous system. *AJNR Am J Neuroradiol* 1995;16:930-935
23. Lowichik A, Rollins N, Delgado R, Visvesvara G, Burns D. Leptomyxid amebic meningoencephalitis mimicking brain stem glioma. *AJNR Am J Neuroradiol* 1995;16:926-929
24. Haines A, Zimmerman R, Morgellos S, et al. MR imaging of brain abscesses. *AJR Am J Roentgenol* 1989;152:1073-1085
25. Sze G, Zimmerman R. The magnetic resonance imaging of infections and inflammatory diseases. *Radiol Clin of North Am* 1988;26:839-858
26. Kioumeh P, Dadsetan M, Roohlamini S, Au A. Central nervous system tuberculosis: MRI. *Neuroradiology* 1994;36:93-96
27. Revel MP, Gray F, Brugieres P, Geny C, Sobel A, Gaston A. Hyperdense CT foci in treated AIDS toxoplasmosis encephalitis: MR and pathologic correlation. *J Comput Assist Tomogr* 1992;16:372-375
28. Miaux Y, Guermazi A, Bourrier P. MR of cerebral aspergillosis: different patterns in the same patient. *AJNR Am J Neuroradiol* 1994;15:1193-1195
29. Fellows D, King V, Conturo T, Bryan R, Merz W, Zinreich J. In vitro evaluation of MR hypointensity in *Aspergillus* colonies. *AJNR Am J Neuroradiol* 1994;15:1139-1144
30. Bach D, Goldenberg MH. Hemorrhage into a brain abscess. *J Comput Assist Tomogr* 1983;7:1067-1069
31. Harwood C, Rich G, McAleer R, Cherian G. Isolation of *Acanthamoeba* from a cerebral abscess. *Med J Aust* 1988;148:47-49