

# Generic Contrast Agents

Our portfolio is growing to serve you better. Now you have a *choice*.



[VIEW CATALOG](#)

# AJNR

This information is current as of May 20, 2025.

**Dissecting aneurysms of all four cervicocranial arteries in fibromuscular dysplasia: treatment with self-expanding endovascular stents, coil embolization, and surgical ligation.**

H I Manninen, T Koivisto, T Saari, P J Matsi, R L Vanninen, M Luukkonen and J Hernesniemi

*AJNR Am J Neuroradiol* 1997, 18 (7) 1216-1220

<http://www.ajnr.org/content/18/7/1216>

---

# Dissecting Aneurysms of All Four Cervicocranial Arteries in Fibromuscular Dysplasia: Treatment with Self-expanding Endovascular Stents, Coil Embolization, and Surgical Ligation

Hannu I. Manninen, Timo Koivisto, Tapani Saari, Pekka J. Matsi, Ritva L. Vanninen, Matti Luukkonen, and Juha Hernesniemi

**Summary:** A patient with cervicocranial fibromuscular dysplasia (FMD) presented with subarachnoid hemorrhage. A ruptured dissecting distal vertebral artery aneurysm required clip ligation of the parent artery; a contralateral dissecting proximal vertebral aneurysm was occluded with detachable coils. Progressive dissecting, extracranial aneurysms of the internal carotid artery were treated with self-expanding stents. Subsequent angiography and intravascular sonography revealed patent stents, a smooth luminal surface, and total occlusion of the aneurysm. Clinical outcome was excellent.

**Index terms:** Aneurysm, therapeutic blockade; Interventional neuroradiology

Intracranial arteries are involved in 7% to 20% of cases of fibromuscular dysplasia (FMD) (1). FMD of the internal carotid artery (ICA) frequently causes dissections and macroscopic dissecting aneurysms, and is accompanied in over 20% of cases by intracranial aneurysms. Modern endovascular techniques have been used increasingly in the treatment of cerebral aneurysms. Embolization of saccular aneurysms with detachable coils is done in cases of high-risk surgery (2, 3). Placement of a stent across the mouth of an aneurysm has been done successfully in animal models and even in humans (4–6). These devices require a fairly straight portion of a vessel and therefore seem suitable for the treatment of dissecting aneurysms in cervical arteries. Two cases of carotid artery dissections treated by placement of metallic noncovered balloon-expandable stents (7) and one case of multiple carotid artery aneurysms treated with a self-expanding stent (8) have previously been reported.

We describe a patient with FMD whose progressive aneurysmal and dissecting lesions in all four cervicocranial arteries were treated by direct surgery, coil embolization, and self-expanding stents.

## Case Report

A previously healthy 48-year-old man was found unconscious at home. He had reported compression behind his eyes and noticed temporary facial paralysis on the left. He regained consciousness in the hospital. Computed tomography revealed severe subarachnoid hemorrhage, mainly in the posterior fossa. Four-vessel angiography showed a broad-necked aneurysm in the left vertebral artery distal to the posterior inferior cerebellar artery (PICA) origin, considered to be ruptured. Another bland aneurysm was found in the extracranial right vertebral artery (Fig 1A). However, muscular disease of the medial type was seen in both vertebral arteries. Further, carotid angiography revealed a small right-sided anteromedial aneurysm at the C1–2 level and a luminal narrowing consistent with a dissection (Fig 2A) as well as a small left-sided aneurysm with a tubular stenosis proximal to the aneurysm (Fig 3A). The angiographic findings were diagnostic of FMD. Findings at renal and visceral artery angiography were normal, as were results of a subsequent superficial temporal artery biopsy.

On the second day after the subarachnoid hemorrhage, the left vertebral artery distal to the PICA was clip ligated through a lateral left suboccipital craniotomy. During surgery, the aneurysm was observed to be fusiform and thin walled; thus, ligation of the aneurysm with preservation of the parent artery was regarded as impossible. A control angiogram showed no filling of the aneurysm through the preserved right vertebral artery. The patient's recovery was uncomplicated and he was discharged 2 weeks later in excellent condition. He was maintained on antiplatelet

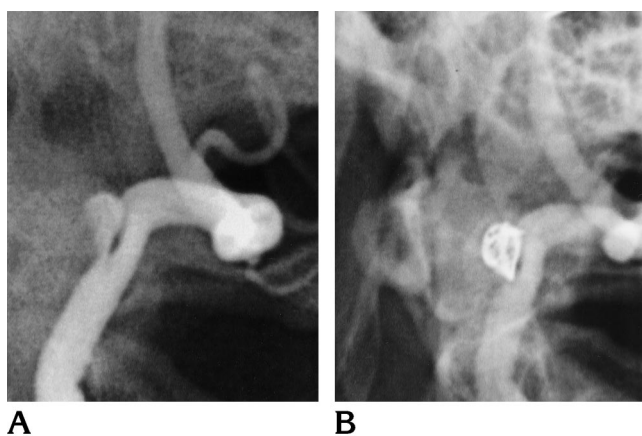
---

Received April 23, 1996; accepted after revision October 9.

From the Departments of Clinical Radiology (H.I.M., T.S., P.J.M., R.L.V.) and Neurosurgery (T.K., M.L., J.H.), Kuopio (Finland) University Hospital, Puijonlaaksontie 2, SF-70210.

Address reprint requests to Hannu I. Manninen, MD, Department of Clinical Radiology, Kuopio University Hospital, Puijonlaaksontie 2, SF-70210, Kuopio, Finland.

AJNR 18:1216–1220, Aug 1997 0195-6108/97/1807-1216 © American Society of Neuroradiology

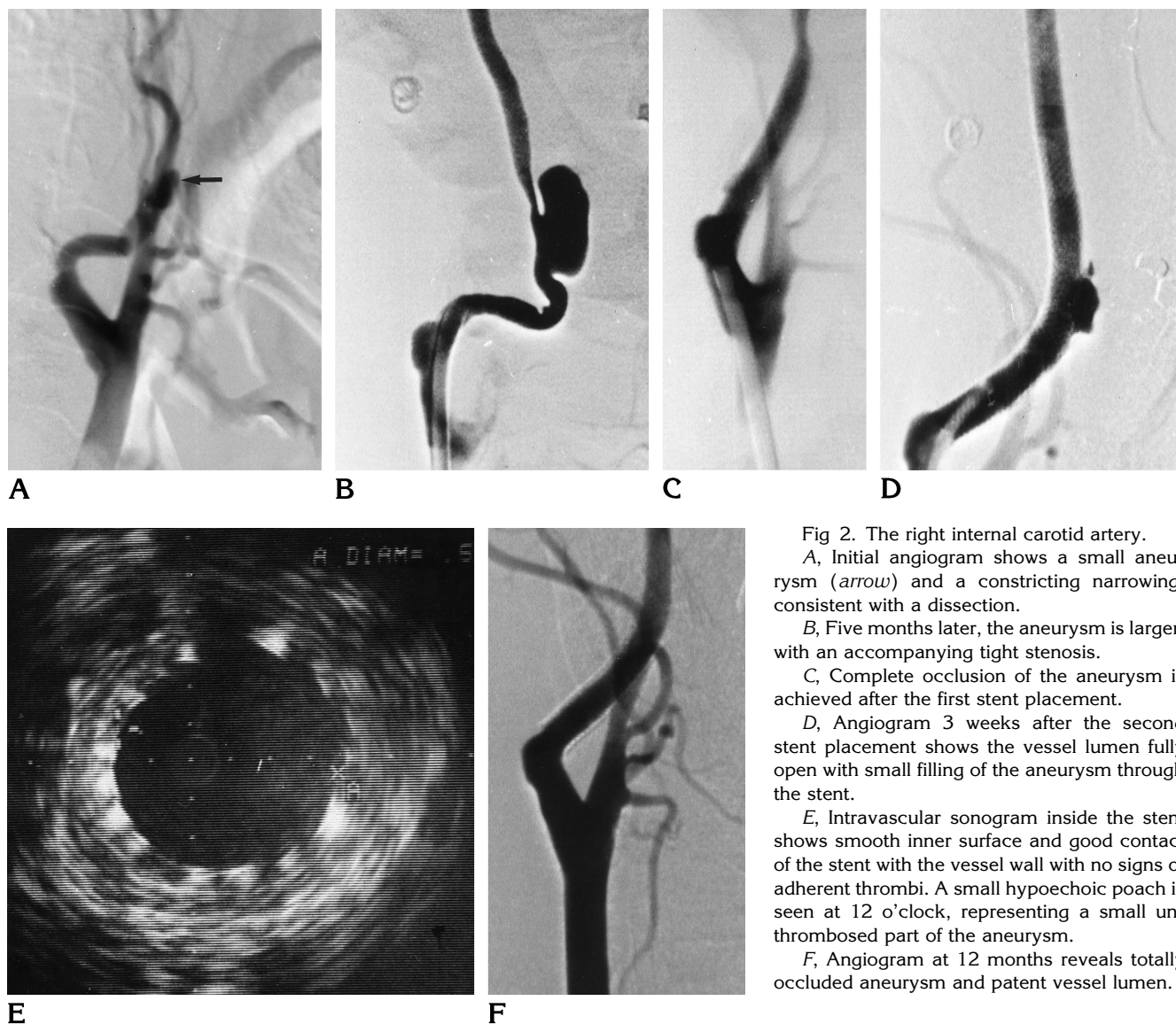


**Fig 1.** The right vertebral artery.  
**A,** Angiogram shows a dissection aneurysm at C-1 level.  
**B,** After detachable coil embolization the aneurysm does not fill and the parent artery is patent.

medication but oral anticoagulation was considered contraindicated because of the recent subarachnoid hemorrhage.

Three months later, after obtaining informed consent, we performed endovascular embolization of the small dissecting right vertebral artery aneurysm using one Guglielmi detachable coil (10 × 6 × 20 mm; Target Therapeutics, Fremont, Calif). Angiography of the ICAs showed progression of the FMD lesions: the aneurysm of the right ICA had enlarged and there was now a tight, short stenosis. In the left ICA, a fusiform dilatation was now seen in the segment in which there previously had been circumferential stenosis, and a wide-necked aneurysm was detected at the distal part of the affected segment (Fig 3B).

At angiography 5 months after the subarachnoid hemorrhage, the embolized aneurysm of the right vertebral artery remained occluded with only a minor deformation in



**Fig 2.** The right internal carotid artery.

**A,** Initial angiogram shows a small aneurysm (arrow) and a constricting narrowing, consistent with a dissection.

**B,** Five months later, the aneurysm is larger, with an accompanying tight stenosis.

**C,** Complete occlusion of the aneurysm is achieved after the first stent placement.

**D,** Angiogram 3 weeks after the second stent placement shows the vessel lumen fully open with small filling of the aneurysm through the stent.

**E,** Intravascular sonogram inside the stent shows smooth inner surface and good contact of the stent with the vessel wall with no signs of adherent thrombi. A small hypoechoic poach is seen at 12 o'clock, representing a small unthrombosed part of the aneurysm.

**F,** Angiogram at 12 months reveals totally occluded aneurysm and patent vessel lumen.

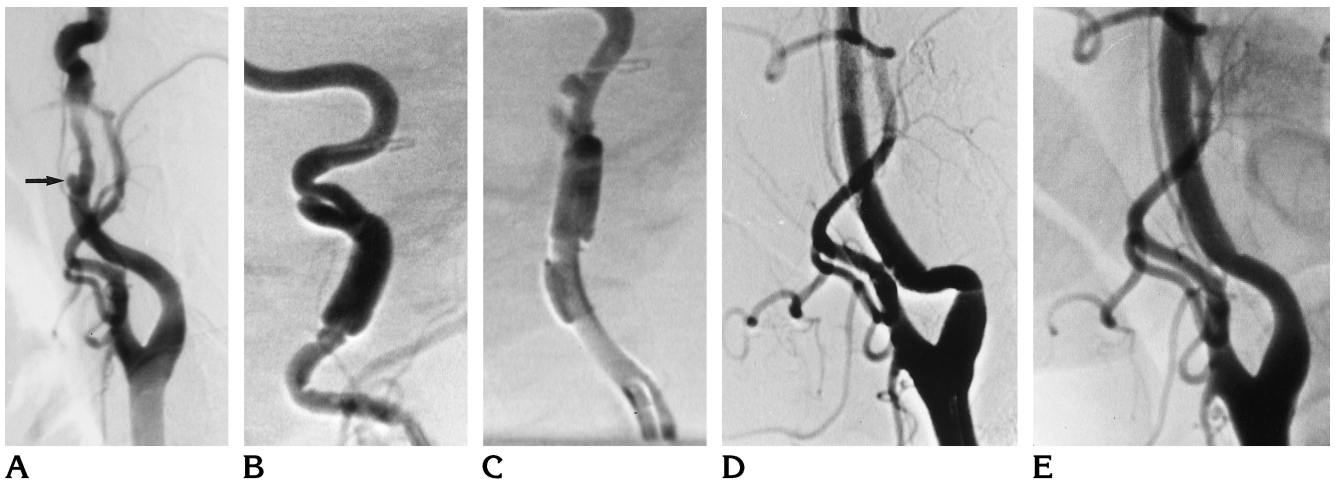


Fig 3. The left internal carotid artery.

A, Initial angiogram shows a small aneurysm (arrow) with circumferential stenosis distally.

B, Three months later, a fusiform dilatation is seen with a wide-necked aneurysm.

C, Immediately after the stent placement, filling of the aneurysm through the filaments of the stent is still seen.

D, Three weeks after stenting, the inner surface of the stent is smooth and no contrast material extends beyond the stent lumen.

E, The vessel has remained patent at angiography 12 months after the procedure.

the vessel wall. The size of the aneurysm in the right ICA had further increased and the shape was now slightly lobular (Fig 2B). Partial thrombosis in the cephalad portion of the aneurysm was seen on magnetic resonance (MR) images. Because of the rapid progression indicative of instability of the lesions, it was decided to treat the ICAs with endovascular stents.

In the stenting procedure, the proximal portion of the right ICA was catheterized with a 9F guiding catheter via a transfemoral route. Direct intraarterial pressure measurement, electrocardiographic monitoring, and systemic anticoagulation with heparin to keep activated clotting time above 200 seconds were used during the procedure. A 0.018-inch guidewire was passed across the lesion and two dilatations of the tight stenosis were performed with a  $3.5 \times 20$  mm coronary perfusion balloon catheter for 20 to 30 seconds each. Remarkable elastic recoil was seen at control angiography. A 0.035-inch guidewire was exchanged, over which a  $6 \times 22$ -mm self-expanding Wallstent (Schneider AG, Bülach, Switzerland) was delivered into the ICA. At control angiography, filling of the aneurysm ceased almost completely and the stenosis was fully open (Fig 2C). Intravenous heparin was continued for 48 hours.

Four weeks later, angiography showed reopening of the aneurysm of the right ICA due to the late shortening and dilatation of the Wallstent. Using similar technique and equipment, we placed a  $6 \times 33$ -mm Wallstent above the previous one with an overlapping segment of approximately 1.5 cm. Flow inside the aneurysm was clearly slower and the accompanying stenosis was fully open. The left ICA was then cannulated and a long,  $6 \times 44$ -mm Wallstent was placed in position over the aneurysm. After stent placement there was still some filling of the aneurysm through the filaments of the stent (Fig 3C).

A control angiogram obtained 3 weeks after stenting showed a smooth stent lumen along with complete occlusion of the aneurysm and an accompanying fusiform dilatation of the left ICA (Fig 3D). The aneurysm of the right ICA was also subtotally occluded and the stented segment of the vessel was fully patent (Fig 2D). Intravascular sonography (3.5F, 30 MHz catheter) showed that the inner surface of the stent was smooth with an approximately 5-mm lumen with no signs of thrombosis. A small hypoechoic pouch was seen in the area of the previous aneurysm, representing the small unthrombosed part (Fig 2E). The vessel wall adjacent to the stent appeared free of disease. Twelve months after stenting, digital subtraction angiography showed total occlusion of the aneurysm also on the right side and fully patent carotid arteries with a thin layer of myointimal hyperplasia within the stents (Figs 2F and 3E). The aneurysm of the right vertebral artery did not fill either, and the patient has remained free of symptoms for 15 months.

## Discussion

Spontaneous cervicocephalic arterial dissections occur with FMD (9–11), but bilateral dissections of both internal carotid and vertebral arteries are rare (1, 12–14). A significant percentage (18% to 56%) of patients with cerebral FMD present with cerebral ischemic symptoms, especially those with associated spontaneous dissections. Spontaneous vertebral extracranial dissecting aneurysms are less frequent than cervical carotid dissections, but they are bilateral in half the cases (13).

Subarachnoid or intracerebral hemorrhage occurs in 13% to 51% of cases of intracranial aneurysms caused by FMD (1). Dissecting aneurysms of intracranial arteries have a high rate of rehemorrhage, and they should be treated as early as possible (15). Successful treatment of FMD lesions in the cervical internal carotid arteries is less well established. In general, aggressive therapeutic interventions have not been recommended, especially with asymptomatic patients who have only angiographic manifestations of FMD. In the short term, serially performed angiography has shown that in the majority of carotid dissections there is a tendency for the normal arterial lumen to be restored during a follow-up period of a few months. However, the lesion may also progress to complete occlusion of the affected vessel (16, 17). After the first month, the risk of recurrent dissection is 1% per year (18).

In the present case, the active approach, with endovascular intervention, was indicated by the multiplicity and rapid progression of the lesions at serial angiography. The partial thrombosis of the large pseudoaneurysm of the right ICA detected on MR images indicated a potential risk of thromboembolism. The risk of stroke was further increased by the tight stenosis in the ICA and the recent ligation of the left vertebral artery caused by the ruptured intracranial aneurysm. Also, the patient, who had already had a subarachnoid hemorrhage, was very concerned about further risks of his disease and was, after receiving detailed information, willing to undergo the offered endovascular treatment.

After previous sacrifice of the left vertebral artery, the patency of the right vertebral artery was vital. Its aneurysm, with a saccular lumen and relatively narrow opening, was well suited for endovascular coil embolization. Marks et al (7) described a patient with a dissecting ICA aneurysm of FMD origin who was treated by a balloon-expanded Palmaz stent. In the present case, flexible Wallstents with inherent active expanding force, rather than rigid Palmaz stents (Johnson and Johnson Interventional Systems, Warren, NJ), were better suited for the treatment of these relatively long lesions in tortuous ICAs. The shortening of Wallstents during delivery is remarkable, and the device can continue to open and correspondingly shorten to its final dimensions for several days after delivery. This process accounts for the late failure of the first stenting of the right ICA in spite of the accept-

able initial result. Similar late failures have previously been reported in renal artery procedures (19). Placement of an overlapping stent above the original one corrected the failure in our patient.

Delayed aneurysmal thrombosis after stent placement, similar to our experience, has been reported (7, 20). Szikora et al (5) described treatment of experimental wide-necked carotid aneurysms in dogs with a combination of a balloon-expanded Strecker stent (Meditech, Waverly, Mass) and coil embolization. O'Brien et al (21) used the same combined technique with Palmaz stents in occluding pseudoaneurysms of the human iliac artery. This technique would probably have been useful also in the present case if the aneurysms had not occluded after stenting. Another possibility would have been the use of covered stents, as previously reported in a case of renal artery aneurysm of FMD origin (22).

Subacute luminal thrombosis may be problematic when stenting long vessel segments owing to poor contact between the stent and the vessel wall. In the present case, because of the apparently good contact between the stent and the vessel wall and because of the full opening of the stenosis, balloon dilatation inside the stent was not performed. Postprocedural intravascular sonography may be especially useful in evaluating the contact achieved in the vessel wall as well as in assessing minor thrombi inside the stent (23). Intravascular sonography is already widely used in coronary and peripheral arteries, and complications are rare (24).

In small-caliber vessels, an important cause of severe stenosis and occlusion of stents is myointimal proliferation, a process that occurs within 6 months (25). In the present case, digital subtraction angiography performed 12 months after stenting indicated patent stents with a thin lining of myointimal proliferation. However, in atherosclerotic lesions, the patency rate of stents may continue to decrease even after 2 years (26). In lesions of FMD origin, the long-term patency of stents is not known, nor is there available data on long-term results of coil embolization in cervical aneurysms. However, good primary results can, in selected cases, be achieved in dissecting aneurysms caused by FMD by using noncovered self-expanding stents and detachable coil embolization.

## References

- Hopkins LN, Budny JL. Fibromuscular dysplasia. In: Wilkins RH, Rengachary SS, eds. *Neurosurgery*. New York, NY: McGraw-Hill; 1985:1293-1296
- Guglielmi G. Endovascular treatment of intracranial aneurysms. *Neuroimaging Clin N Am* 1992;2:269-278
- Gurian JH, Martin NA, King WA, Duckwiler GR, Guglielmi G, Viñuela F. Neurosurgical management of cerebral aneurysms following unsuccessful or incomplete endovascular embolization. *J Neurosurg* 1995;83:843-853
- Gerema G, Haklin M, Brennecke L. Embolization of experimentally created aneurysms with intravascular stent devices. *AJNR Am J Neuroradiol* 1994;15:1223-1231
- Szikora I, Guterman LR, Wells KM, Hopkins LN. Combined use of stents and coils to treat experimental wide-necked carotid aneurysms: preliminary results. *AJNR Am J Neuroradiol* 1994;15:1091-1102
- Turjman F, Massoud TF, Ji C, Guglielmi G, Viñuela F, Robert J. Combined stent implantation and endosaccular coil placement for treatment of experimental wide necked aneurysms: a feasibility study on swine. *AJNR Am J Neuroradiol* 1994;15:1087
- Marks MP, Dake MD, Steinberg GK, Norbash AM, Lane B. Stent placement for arterial and venous cerebrovascular disease: preliminary experience. *Radiology* 1994;191:441-446
- Mase M, Banno T, Yamada K, Katano H. Endovascular stent placement for multiple aneurysms of the extracranial internal carotid artery: technical case report. *Neurosurgery* 1995;37:832-835
- Schievink WI, Mokri B, Piepgras DG. Spontaneous dissections of cervicocephalic arteries in childhood and adolescence. *Neurology* 1994;44:1607-1612
- Friedman WA, Day AL, Guisling RG, et al. Cervical carotid dissecting aneurysms. *Neurosurgery* 1980;7:207-214
- Schievink WI, Bjornsson J, Piepgras DG. Coexistence of fibromuscular dysplasia and cystic necrosis in a patient with Marfan's syndrome and bilateral carotid artery dissections. *Stroke* 1994;25:2492-2496
- Mokri B. Traumatic and spontaneous extracranial internal carotid artery dissections. *J Neurol* 1990;237:356-361
- Hinse P, Thie A, Lachenmayer L. Dissection of the extracranial vertebral artery: report of four cases and review of the literature. *J Neurol Neurosurg Psychiatry* 1991;54:863-869
- Rodacki MA, Mello LR. Bilateral dissecting aneurysms of the extracranial vertebral arteries associated with cervical carotid artery aneurysm. *AJNR Am J Neuroradiol* 1990;11:1147-1149
- Hernesniemi JA, Drake CG, Peerless SJ. Nongiant aneurysms of the vertebral artery. In: Drake CG, Peerless SJ, Hernesniemi JA, eds. *Surgery of Vertebrobasilar Aneurysms: London, Ontario Experience on 1767 Patients*. Vienna, Austria: Springer; 1996:195-206
- Friedman AH, Drake CG. Subarachnoid haemorrhage from intracranial dissecting aneurysms. *J Neuroimaging* 1984;60:325-334
- Amarenco P, Seux-Levieil ML, Cohen A, Levy C, Touboul PJ, Boussier MG. Carotid artery dissection with renal infarcts: two cases. *Stroke* 1994;25:2488-2491
- Schievink WI, Mokri B, O'Fallon VM. Recurrent spontaneous cervical artery dissection. *N Engl J Med* 1994;330:393-397
- Wilms GE, Peene PT, Baert AL, et al. Renal artery stent placement with use of the Wallstent endoprosthesis. *Radiology* 1991;179:457-462
- Vorwerk D, Günther RW, Wendt G, Schürmann K. Ulcerated plaques and focal aneurysms of iliac arteries: treatment with non-covered, self-expanding stents. *AJR Am J Roentgenol* 1994;162:1421-1424
- O'Brien CJM, Rankin MN. Percutaneous management of large-necked pseudoaneurysms with arterial stent placement and coil embolization. *J Vasc Interv Radiol* 1994;5:443-448
- Bui BT, Oliva VL, Leclerc G, et al. Renal artery aneurysm: treatment with percutaneous placement of a stent-graft. *Radiology* 1995;195:181-182
- Goldberg SL, Colombo A, Nakamura S, et al. Benefit of intracoronary ultrasound in the deployment of Palmaz-Schatz stents. *J Am Coll Cardiol* 1994;24:996-1003
- Hausmann D, Erbel R, Alibelli-Chemarin M-J, et al. The safety of intracoronary ultrasound: a multicenter survey of 2207 examinations. *Circulation* 1995;91:623-630
- Duissaillant GR, Mintz GS, Pichard AD, et al. Small stent size and intimal hyperplasia contribute to restenosis: a volumetric intravascular ultrasound analysis. *J Am Coll Cardiol* 1995;26:720-724
- Henry M, Amor M, Ethevenot G, et al. Palmaz stent placement in iliac and femoropopliteal arteries: primary and secondary patency in 310 patients with 2-4-year follow-up. *Radiology* 1995;197:167-174