

# Generic Contrast Agents

Our portfolio is growing to serve you better. Now you have a *choice*.



FRESENIUS  
KABI

[VIEW CATALOG](#)

# AJNR

**Arthur Schüller: pioneer of neuroradiology.**

E Schindler

*AJNR Am J Neuroradiol* 1997, 18 (7) 1297-1302

<http://www.ajnr.org/content/18/7/1297.citation>

This information is current as  
of May 21, 2025.

---

# HISTORY

## Arthur Schüller: Pioneer of Neuroradiology

Erwin Schindler, *Neuroradiological Department, Vienna (Austria) University Hospital*

*Time is passing very fast; remembering may help against the uneasiness thereby evoked, remembering with gratitude.\**

The centennial celebration of the discovery of X rays was last year, and the first radiograms of the skull were made one hundred years ago (1). Thus, it is appropriate to remember Arthur Schüller, who was “without any shadow of doubt the father of neuroradiology” (2). His biography can be considered an example of the fate of many scientists in our century.

Arthur Schüller was born in Brünn (now Brno, Czechia), in the north of Vienna, in 1874. His ancestors were merchants and industrialists, and his father was an otorhinolaryngologist. At the age of 17, Schüller came to Vienna to study medicine. It is a coincidental twist of fate that the very day that Wilhelm C. Röntgen (1845–1923) submitted his famous preliminary communication, “About a New Kind of Rays” (3), to the Society of Physics and Medicine in Würzburg, Germany, Saturday, December 28th, 1895, Schüller celebrated his 21st birthday and attained his majority. Those new kind of rays would considerably influence his professional life. Four years later, on November 5th, 1899, he was graduated with the highest honors from Vienna University; because of his outstanding performance, he became a doctor of medicine “sub auspiciis imperatoris,” namely, a doctor under the patronage of the emperor Franz Joseph, who awarded this distinction only twice during his 68-year reign.

Dr Schüller began his medical career in the

field of neuropsychiatry. His first masters were Richard Krafft-Ebing (1840–1902), a pioneer of research on sexual behavioral disorders, and Julius Wagner-Jauregg (1857–1940), honored with the Nobel Prize in 1927 for having developed malaria therapy against syphilis. Thus, Schüller’s first publications dealt with the clinical application of a soporific (4) and with maniacal jealousy in women (5). It was Wagner-Jauregg who paved the way not only for the acceptance of “medical radiology” by the Vienna University early in our century but also for the cooperation between neuropsychiatry and radiology. He sent Schüller to his colleague and friend Guido Holzkecht (1872–1931), who had been active at the Central Röntgen Laboratory in the Vienna General Hospital since 1901, and who was named head of the laboratory in 1905.

Schüller’s enthusiasm for science and research soon bore fruit, and in 1905 his first book, *The Skull Base on the Radiogram* (6) (Fig 1), was published. It was a comprehensive description of normal and pathologic anatomy as well as of many special radioprojections of the skull base, which confirmed Schüller’s excellent anatomic knowledge as well as his systematic diligence.


The subsequent years brought happiness and success. One could say that Fortune smiled on Schüller during the fourth decade of his life (Fig 2). In December 1906, he married Margarete Stiassni. A few months later he achieved the status of university lecturer (*venia docendi*). His son Franz Ferdinand was born in 1908, and a second son, Hans Heinrich, followed in 1909. In 1912 Schüller’s second monograph, *Röntgen Diagnosis of Diseases of the Head* (7) (Fig 3), was published. It became the standard textbook then and during the whole “classic era” of neuroradiology; its English translation (by Stocking) appeared in 1918 (8).

In January 1914, Schüller was appointed a university professor, thus becoming (at the age of 39) the youngest member of the medical

---

\*From “En Recuerdo de Arthur Schüller,” presented by the author at the Seventh Congress of the Sociedad Iberoamericana de Neuroradiología Diagnóstica y Terapéutica, Buenos Aires, Argentina, November 1995.

Address reprint requests to Erwin Schindler, MD, Neuroradiological Department, Vienna University Hospital, Währinger Gürtel 18-20, A-1090 Vienna, Austria.



1

faculty at that time. This was 6 months before the outbreak of World War I. Four years later, the Austro-Hungarian empire had perished, and Vienna was no longer a significant European center of art and culture but a seedy town crowded with impoverished and desperate people, as well as thousands of war disabled who suffered from famine and infectious diseases. The inflation that consequently developed was devastating to nearly everyone and wrecked the economic efforts of the new Austria, the small state that was the remnant of the former empire. As a result of the escalating inflation, Schüller lost his financial stability, as Frank Morgan (1906–1988) mentions in Schüller's obituary (9), one of the most warm-hearted and poignant memorials in the medical literature.

Nevertheless, scientific activities, particularly the efficiency of the Vienna Medical School, were not damaged by the war. The responsibility for destroying the productivity and innovative scientific exploration that the medical school had held, even during the crisis of World War I and its aftermath, was reserved for Hitler, twenty years later (10). As he had done during the last years of the monarchy and during the war, Schüller maintained, in the new Austria, his position as chief neurologist in a hospital primarily for outpatients (Franz Joseph-Ambulatorium) in the sixth district of Vienna (there he would be active until forced to leave the country). In addition, he offered neurologic consultations to patients in the house in the ninth

district, where the Schüllers lived (Fig 4A and B). It must be emphasized that he never ceased his neuroradiologic research: there was an X-ray apparatus in his consulting room, and Holzkmann's Röntgen laboratory was a few steps from his home. Numerous skull cases were referred to Schüller by colleagues from far and near to obtain his opinion and counsel. Moreover, he gave postgraduate courses that were attended by students from all over the world, since he was an excellent teacher who was famous for his professional expertise, and whose English was perfect (note in his personal dossier from the University).


Despite this amount of daily work, Schüller did not neglect cultural life; he was a gifted violinist and member of the Vienna Doctors' Orchestra. Felix Fleischner remembers that "he and his wife used to enjoy playing duosonatas" (11).

The quantity of Schüller's scientific work is immense. According to Morgan (9), it comprises more than 300 publications. "Schüller" does not only mean a special temporal bone projection. Certainly, Schüller coined the term *Neuro-Röntgenologie* (12), but his activity was not restricted to neuroradiology. It covered neurology and psychiatry and also stimulated neurosurgical progress.

It is well known that Oskar Hirsch (1877–1965) introduced the transsphenoidal approach to pituitary tumors in 1909; this would not have been achieved, however, without the radiologic advice of Schüller (13). (It is interesting that



2



3

Hirsch worked as chief otorhinolaryngologist in the same hospital as Schüller after World War I; in 1938, he was forced to emigrate and went to Boston, Mass.) It is not generally known, however, that Schüller was the first (in 1910) to suggest and recommend, based on his animal experiments, the anterolateral chordotomy in cases of intractable pain (14), an operation that is named after Spiller and Frazier. He also suggested palliative operations in cases of obstructive hydrocephalus and raised intracranial pressure, an anterior (15) and a posterior (16) drainage of the third ventricle. In 1934 he published (together with Urban) *Craniocerebral Diagrams for Radiological Localization* (17); this book is a forerunner of the stereotactic atlases that are used today, and it seems to be one of the few scientific documents that Schüller took along with him when he emigrated (9).

Schüller was not only familiar with the radiologic signs of raised intracranial pressure, with the significance of a shifted pineal calcification, and with the cause of the “growing” of a skull fracture in children. He was also the first to describe the “map-like skull” in the syndrome that is now called Hand-Schüller-Christian disease (18). In 1926 he pointed out the radiologic sign of “circumscribed osteoporosis” of the skull that he had seen in two patients (19). The radiographs of one of them were sent to him by Hendrik Stenvers from Utrecht; the skull of this patient was biopsied by Harvey Cushing, and

histologic findings suggested Paget disease (20). This particular case is also mentioned in a paper (21) by Merrill C. Sosman (1890–1959), who has been called the first neuroradiologist in the United States (22); thereupon, Schüller was the first to discuss a relation between osteoporosis circumscripta and Paget disease (the former being, in fact, the early stage of the latter).

Research on skull diseases is, admittedly, not neuroradiology in the literal sense. Erik Lindgren claimed that Schüller was a forerunner, rather than founder, of neuroradiology, because “at no time did he express interest in the contrast medium studies that are characteristic of true neuroradiology” (23). However, in 1922 (July 3), Schüller had already presented a didactically excellent lecture about air studies of the brain (24), mentioning not only Walter Dandy (1886–1946), who later expressed his high regard for Schüller, but also Adolf Bingel (1879–1953) as the pioneers of ventriculography and pneumoencephalography (25, 26), and demonstrating, as well, ventriculograms from his own material. More remarkable, however, is the fact that Schüller was the first who carried out cisternographies with iodine oil (27). This was more than 25 years before Pantopaque cisternography was presented as a diagnostic modality in the United States.

There is no doubt that in the 1930s, Professor Schüller (Fig 5) was famous everywhere in the medical world and highly esteemed as a neuro-radiologic expert in Vienna. He regularly contributed to the renowned sessions of the Viennese Society of Physicians, whose meeting place and auditorium lay just around the corner



4A



4B



5


from his home. And he frequently published in the Viennese medical journals that still had, at that time, a high level of scientific integrity and a large circulation. His last paper there appeared on February 26, 1938, and was on radiologic findings of epilepsy in children. There he mentioned that there were "countries with regulations referring to the prevention of offspring with hereditary defects" (28). Exactly 2 weeks later, the Nazis, whose "solution" to such hereditary defects was murder, entered Austria. After the annexation of Austria by Hitler's Germany, Arthur and Margarete Schüller were forced to flee Vienna at the ages of 64 and 52, respectively. It is not known how their sons were "at the last moment prevented from leaving Austria" (9).

Oxford, England, was the first place of rest for the emigrating Schüllers. Fortunately, they had substantial help from Alfred E. Barclay (1876–1949), who was the doyen of British radiology and held a leading position in the Nuffield Institute for Medical Research in Oxford at that time. There is one paper by Schüller from this institute (29) that shows that Barclay gave him the opportunity to be active there and proves that Schüller continued his contrast medium studies. Despite the grief and sorrow about leaving their homeland and the worry about the probable fate of their sons, he did not cease his scientific activity, and Schüller published at least 11 papers between 1938 and 1940, during the most stormy and dreadful years of his life. He at-

tended the first Symposium Neuroradiologicum in Antwerp, where he gave a lecture on Thursday, July 27, 1939. On that day, everyone feared but dared not believe that war would really break out, although it did within 5 weeks. The flight, therefore, continued.

Several reasons seem to have moved Schüller to choose Australia as the endpoint of his emigration. Bitterly disappointed with Europe and terrified of the Nazis, he wanted to stay as far away as possible. America, he said, "was too close to Europe" (K. Henderson, personal communication). It was most likely Alfred Barclay who recommended that Schüller go so far; Barclay was for years the representative for the Australian and New Zealand Association of Radiologists on the Council of the British Institute of Radiology and had the best connections with radiologic colleagues there. Moreover, it is almost certain that the Australian radiologist John O'Sullivan (1896–1957), who was Schüller's pupil in Vienna in the 1920s, had influenced him to go to Melbourne.

The Schüllers arrived in Australia late in 1939. Although they were welcomed warmly by Australian colleagues, it was difficult for the Schüllers to begin a new life in a strange land with a different culture. They settled in Melbourne and found a home in a suburb named, in an ironic twist, Heidelberg. Apparently, their financial means were limited, since Margarete Schüller "went into people's homes as a domestic, mainly ironing and cooking, almost from the time of their arrival in Australia up until a year or two before her death" (K. Henderson, personal communication). Her husband, however, pursued his chosen career. He found work in the X-ray department of St Vincent's Hospital (Fitzroy, Melbourne), where John O'Sullivan was active as a radiologist, and where Frank Morgan was the head of the Neurosurgical Unit. Morgan soon became a dear and true friend; to him Schüller was "the most helpful, charming and valuable colleague that one could wish to have" (9). For some years Schüller also worked in the X-ray department of the Repatriation Hospital (Heidelberg, Melbourne). A room was given to him to use at his disposal in the anatomy department at Melbourne University, where he became an honorary research officer, and he obtained the MD degree from the universities of Melbourne and Sydney. He continued, of course, to contribute to the medical literature. Moreover, he gave evening classes in radiology



6

at his home, as he had done in Vienna. Later, after the war, he became an honorary member of the Australian and New Zealand Radiological Society.

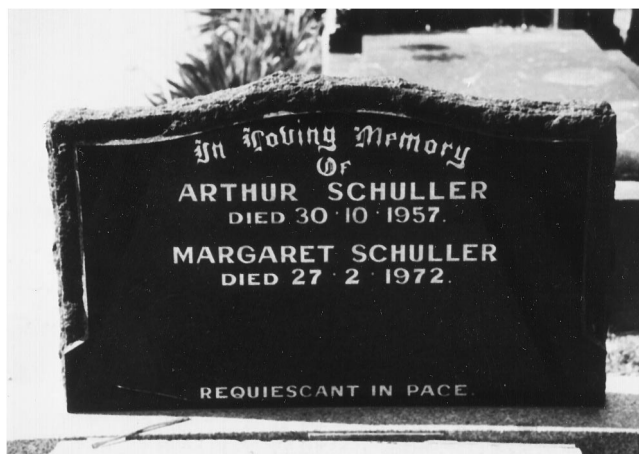
It was some time after the war ended when the Schüllers received confirmation that their sons were dead. They were, like innumerable Jews, "exterminated in a Nazi concentration camp," as Franz Freund has written in his obituary for Schüller (30). Thus, the desperate hope of the Schüllers was destroyed by this most dreadful stroke of fate, which heavily overshadowed their remaining years. Arthur Schüller became severely depressed and even considered leukotomy treatment, but was "persuaded to forgo the fulfillment of his suggestion" (9). In spite of his deep depression, he proved once again his generosity and submitted his next-to-last paper for publication to an Austrian journal (31). In addition, he accepted the invitation of the Austrian Radiological Society to become an honorary member.

That he was free from resentment is evident in his correspondence with George B. Ziedses des Plantes (1902–1993), who was also a former pupil in Vienna during the 1930s and who was one of the greatest personalities of European neuroradiology. Ziedses des Plantes became president of the second Symposium Neuroradiologicum that took place in Rotterdam (September 13–17, 1949) and he invited Schüller to participate. Schüller seemed to be sincerely gratified and assisted with useful advice. Considering the journey to Europe, how-

ever, he hesitated; he wrote that it would be a particular opportunity to meet his friends again, but he physically did not feel up to such a long journey. His fatigue was understandable (Fig 6), but one gets the impression that Schüller was afraid of seeing Europe again. He sent a manuscript that was read by Ziedses des Plantes at the Symposium and was published 1 year later—the last paper from the first neuroradiologist (32). It is generally unknown that Schüller was, in absentia, extremely honored at that Symposium. On September 16, a telegram was transmitted to him with the message, "the participants send their greetings and thanks to the new appointed honorary president of the symposium neuroradiologicum hoping he will accept"; Schüller's telegram reply read, "accepting with pleasure—thanks" (C. B. A. J. Puylaert, personal communication).

Arthur Schüller died on Thursday, October 31, 1957, at St Vincent's Hospital, where he had so many friends. The funeral was 2 days later in Heidelberg. Frank Morgan wrote to Merrill Sosman (who had visited Schüller a few months before) that he "was buried on the feast of All Souls . . . in view of the hills there, which so much reminded him of his beloved Vienna" (11). In Austria, however, Schüller's death was either briefly noted or commented upon with vain pathos and hypocritical fulsome praise (33). There was nothing explicit about his tragic fate and no hint of guilt.

Margarete Schüller, an admirable and valiant woman, survived her husband by more than 14 years. She died at the age of 85 and was buried in the same resting place as her husband. On their tombstone (Fig 7), the date of his decease



7

is incorrect. After her death there was no one left who could remember the exact date of Arthur Schüller's death, and there are few who know his moving biography and his tremendous scientific work. This paper is respectfully written in remembrance of Arthur Schüller, the pioneer of neuroradiology.

## Acknowledgments

I am indebted to M. Hubenstorf (Berlin) for substantial advice and information, as well as to C. B. A. J. Puylaert (Bosch en Duin) for supplying the correspondence between Schüller and Ziedses des Plantes. My most sincere and hearty thanks go to Keith Henderson (Fitzroy) for his providing me with image material and with significant facts and details of his personal contacts with A. Schüller.

## References

1. Fischgold H, Bull JWD. A short history of neuroradiology (reprint). In: Cabanis EA, ed. *Contribution à l'Histoire de la Neuroradiologie Européenne*. Paris, France: Pradel; 1989:3–60
2. Bull JWD. History of neuroradiology. *Br J Radiol* 1961;34:69–84
3. Röntgen WC. Über eine neue Art von Strahlen; vorläufige Mitteilung. *Sitzungs-berichte der Physikalisch-Medizinischen Gesellschaft in Würzburg* 1895;137:132–141
4. Schüller A. Hedonal, ein Hypnoticum der Urethan-Gruppe. *Wien Klin Wochenschr* 1900;13:526–528
5. Schüller A. Eifersuchtswahn bei Frauen. *Jahrb Psychiatr Neurol* 1901;20:292–319
6. Schüller A. *Die Schädelbasis im Röntgenbilde*. Hamburg, Germany: Gräfe & Sillem; 1905
7. Schüller A. *Röntgen-Diagnostik der Erkrankungen des Kopfes*. Wien, Leipzig: Hölder; 1912
8. Schüller A. *Roentgen Diagnosis of Diseases of the Head*. St Louis, Mo: Mosby; 1918
9. Morgan F. Arthur Schüller (obituary). *Proc Coll Radiol Aust* 1959;3:55–58
10. Ernst E. A leading medical school seriously damaged: Vienna 1938. *Ann Intern Med* 1995;122:789–792
11. Fleischner FG. Dr Arthur Schüller: in memoriam. *Radiology* 1958;70:595–596
12. Schüller A. Röntgenologie in ihren Beziehungen zur Neurologie. *Dtsch Z Nervenheilkd* 1914;50:188–207
13. Hirsch O. Eine neue Methode der endonasalen Operation von Hypophysentumoren. *Wien Med Wochenschr* 1909;59:636–638
14. Schüller A. Über operative Durchtrennung der Rückenmarksstränge (Chordotomie). *Wien Med Wochenschr* 1910;60:2292–2296
15. Schüller A. Sellare Palliativtrepanation und Punktion des dritten Hirnventrikels. *Wien Med Wochenschr* 1911;61:182–190
16. Schüller A. Posterior cisternal drainage of the hydrocephalic third ventricle (posterior third ventriculostomy): preliminary note. *Surgery* 1948;24:119
17. Schüller A, Urban H. *Craniocerebrale Schemata für die röntgenographische Lokalisation*. Leipzig, Germany: Deuticke; 1934
18. Schüller A. Über eigenartige Schädeldefekte im Jugendalter. *ROFO* 1915;23:12–18
19. Schüller A. Dysostosis hypophysaria. *Arch Radiol Electrother* 1926;31:156–158
20. Schüller A. Über circumscripste Osteoporose des Schädels. *Med Klin* 1929;25:615–616
21. Sosman MC. Radiology as an aid in the diagnosis of skull and intracranial lesions. *Radiology* 1927;9:396–407
22. Gutiérrez C. The birth and growth of neuroradiology in the USA. *Neuroradiology* 1981;21:227–237
23. Lindgren E. A history of neuroradiology. In: Newton TH, Potts DG, eds. *Radiology of the Skull and Brain*. St Louis, Mo: Mosby; 1971;1:1–25
24. Schüller A. Zur Röntgendiagnose der intrakraniellen Affektionen mit Hilfe des Dandyschen Verfahrens. *Wien Klin Wochenschr* 1922;35:709–711
25. Dandy WE. Ventriculography following the injection of air into the cerebral ventricles. *Ann Surg* 1918;68:4–11
26. Bingel A. Encephalographie, eine Methode zur röntgenographischen Darstellung des Gehirns. *ROFO* 1921;28:205–217
27. Schüller A. Kontrastfüllung der basalen Zisternen des Gehirns mit schwerem Jodöl. *ROFO* 1936;54:251–256
28. Schüller A. Röntgenbefunde bei kindlicher Epilepsie. *Wien Med Wochenschr* 1938;88:229–230
29. Schüller A. Radiography of the sub-arachnoid cisternae at the base of the brain. *Br J Radiol* 1940;13:127–129
30. Friend F. Arthur Schüller, MD (obituary). *Br Med J* 1958;1:525
31. Schüller A. Über seltene pathologische Röntgenbilder. *Radiol Austriaca* 1949;2:31–41
32. Schüller A. A short review of cranial hyperostoses. *Acta Radiol (Stockh)* 1950;34:361–373
33. Weiss K. Arthur Schüller (Nachruf). *ROFO* 1958;89:485–486