

Generic Contrast Agents

Our portfolio is growing to serve you better. Now you have a *choice*.



[VIEW CATALOG](#)

AJNR

Functional MR activation correlated with intraoperative cortical mapping.

F Z Yetkin, W M Mueller, G L Morris, T L McAuliffe, J L Ulmer, R W Cox, D L Daniels and V M Houghton

AJNR Am J Neuroradiol 1997, 18 (7) 1311-1315

<http://www.ajnr.org/content/18/7/1311>

This information is current as of May 23, 2025.

Functional MR Activation Correlated with Intraoperative Cortical Mapping

F. Zerrin Yetkin, Wade M. Mueller, George L. Morris, Timothy L. McAuliffe, John L. Ulmer, Robert W. Cox, David L. Daniels, and Victor M. Haughton

PURPOSE: To evaluate the spatial specificity of functional MR imaging by comparing it with intraoperative electrocortical mapping. **METHODS:** Functional MR imaging was performed in 28 patients before awake craniotomy and intraoperative electrocortical mapping. Activation was mapped for finger movement, lip movement, tongue movement, word generation, and counting paradigms. During surgery, finger movement, lip movement, tongue movement, counting, and/or speaking were mapped. The functional images and the photographic recordings of the brain functions mapped during surgery were converted to bit maps and coregistered by a computer program. The distance between the intraoperatively mapped function site and the MR activation site for a comparable function was measured. **RESULTS:** Forty-six functions were recorded on MR images and intraoperative maps. In 100% of correlations, the intraoperative site and the MR activation site were within 20 mm; in 87% of correlations they were within 10 mm. For each paradigm, 67% or more of the intraoperative stimulation maps correlated within 10 mm of the MR activation site. **CONCLUSIONS:** For the tasks used in this study, the activation site on functional MR images correlated well with the site at which intraoperative stimulation identified function.

Index terms: Brain, magnetic resonance; Magnetic resonance, functional

AJNR Am J Neuroradiol 18:1311-1315, August 1997

The spatial specificity of functional magnetic resonance (MR) imaging warrants additional validation. One method of validating functional MR imaging is by direct comparison with intraoperative mapping, which is used routinely during craniotomy to identify brain regions necessary for language function and voluntary movements (1, 2). One intraoperative mapping method to which we intended to compare functional MR imaging is electrocortical stimulation, by which the sensorimotor cortex and the frontal lobe language regions are identified. Electrical stimulation of the sensorimotor cortex produces either movement, which an observer

monitors, or sensation, which the patient reports. By eliciting movement of the tongue, lips, or fingers, or by producing sensation in these regions, the surgeon can identify the appropriate area of the sensorimotor cortex through stimulation of the cerebral surface. To identify language areas, the surgeon stimulates the cerebral surface while the patient is counting or speaking. Electrical stimulation of a specific region in the inferior frontal or precentral gyri interrupts the counting or speaking, because the stimulation produces a "temporary lesion" (3).

The purpose of this study was to compare the activation in the frontal lobe caused by counting or word generation with the site at which electrocortical stimulation produces speech or counting arrest and to compare the activation from finger movement or tactile stimulation of the hand with the site at which electrocortical stimulation identifies the sensorimotor cortex. A few correlations between intraoperative function imaging and functional MR imaging have been reported previously (4, 5).

Received October 23, 1996; accepted after revision February 13, 1997.

From the Departments of Radiology (F.Z.Y., J.L.U., D.L.D., V.M.H.), Neurosurgery (W.M.M.), Neurology (G.L.M.), Biostatistics (T.L.M.), and Biophysics (R.W.C.), Medical College of Wisconsin, Milwaukee.

Address reprint requests to Victor M. Haughton, MD, Department of Radiology, Medical College of Wisconsin, Froedtert Memorial Lutheran Hospital, 9200 W Wisconsin Ave, Milwaukee, WI 53226

AJNR 18:1311-1315, Aug 1997 0195-6108/97/1807-1311

© American Society of Neuroradiology

Subjects and Methods

A consecutive series of patients underwent functional MR imaging prior to craniotomy and intraoperative electrocortical stimulation mapping. The locations of activation on the MR images and functions on the intraoperative stimulation maps were compared by coregistering the MR images and the intraoperative maps.

Patient Selection

Patients scheduled for intraoperative stimulation mapping in conjunction with a tailored lobectomy for the treatment of seizures or the resection of a tumor near the motor strip were screened. Subjects who were willing and able to cooperate, English speaking, and not claustrophobic were asked to participate. Patients with a contraindication to MR imaging were excluded. Candidates for the studies were informed about the experimental procedure and asked to sign a consent form.

Functional MR Imaging Data Acquisition and Image Processing

After inserting ear plugs, the subject was positioned in a 1.5-T imager equipped with a three-axis gradient coil and end-capped bird cage receiver coil. A series of seven parallel sagittal anatomic spin-echo MR images was obtained with parameters of 600/20 (repetition time/echo time) and 10-mm section thickness to encompass the hemisphere on which surgery was anticipated. The series was programmed with the first image adjacent to the midline. In the same planes as the anatomic images, a series of 140 gradient-echo echo-planar images was acquired at a rate of one per second. The technical factors for each image included 1000/40, 1-cm section thickness, 64×64 matrix, and 24-cm field of view. During the acquisitions, 20-second periods of rest and task were alternated. The time course of the signal intensity in each pixel over 140 seconds was plotted and compared with a reference function by means of a cross-correlation program (6). A modified square wave with a period of 40 seconds was used as the reference function. The first 5 seconds of the time course and the first 5 seconds of each rest and task period were disregarded in the cross-correlation calculation. The correlation coefficients were calculated for each pixel. Pixels that exceeded a correlation coefficient of 0.6 were defined as activated pixels. The activated pixels in the functional images were then overlaid on the exactly corresponding anatomic reference images by means of an image processing program (6). The paradigms used during the task period included silent word generation (7), which typically produces activation in the left inferior frontal and precentral gyri; counting by twos, which produces activation in the same locations as the word generation task; finger tapping (8), which produces activation ventral and dorsal to the central sulcus; and pursing of the lips and movement of the tongue, both of which produce activation in the subcentral gyrus. The word generation task consisted of

the subject's thinking of words beginning with a letter supplied by the investigator for the 20-second task period (7). A different letter was supplied for each task period. During the rest periods, the subject was instructed to lie still and not to move or to think about moving any parts of the body. For counting by twos, the subject was instructed to begin counting when cued and then to count forward to 20 and backward to 0 until instructed to stop. For the finger-tapping task, the subject apposed the thumb and fingers repeatedly at a self-paced rate when cued (8, 9). For the tongue or lip movement, the subject was instructed to purse the lips repeatedly or to move the tongue repeatedly when cued without opening the mouth or moving the head. A series of sagittal images was acquired in the same planes as the anatomic images with a spoiled gradient-echo sequence, 50/9, a flip angle of 50° , and flow compensation to provide a map of the venous anatomy of the convexity.

Surgical Methods

For the intraoperative stimulation mapping, the patient was premedicated and sedated. With the patient under local anesthesia, the scalp was reflected. After administration of a short-acting intravenous barbiturate to achieve a light transient anesthesia, a craniotomy was performed to expose portions of the inferior frontal, inferior parietal, and superior parietal lobes. For the 15 minutes immediately preceding the cortical stimulation, no anesthetic was given. In the surgical field, vascular and gyral landmarks were identified. To identify the sensorimotor cortex, selected locations of the cortex were stimulated by means of a bipolar electrical probe 5 mm in diameter with an alternating current of 10 mA. The response of the patient to each stimulation was carefully monitored by a trained observer who could see the patient's hands, fingers, and face and could query the patient regarding sensation felt in the hand, fingers, face, or tongue. Objective signs or subjective experiences temporally related to stimulation of a location were recorded. To identify the frontal lobe location of language function, the patient was asked to count or to recite sentences while the brain surface was stimulated intermittently with the electrode. A location in which stimulation reproducibly interrupted speech or counting was recorded as the site of a speech function. A numbered marker was placed on the surface of the brain at each stimulation site and the correlated response recorded. The mapping was performed intraoperatively at the discretion of the surgeon. At the conclusion of the stimulation mapping procedure, the marker placement was recorded photographically with the camera positioned so as to minimize parallax and distortion.

Graphic Methods for Comparing Functional MR Images and Intraoperative Maps

Distance was calculated between functional MR imaging activation and intraoperative mapping of a similar function. For this purpose, functional MR imaging activa-

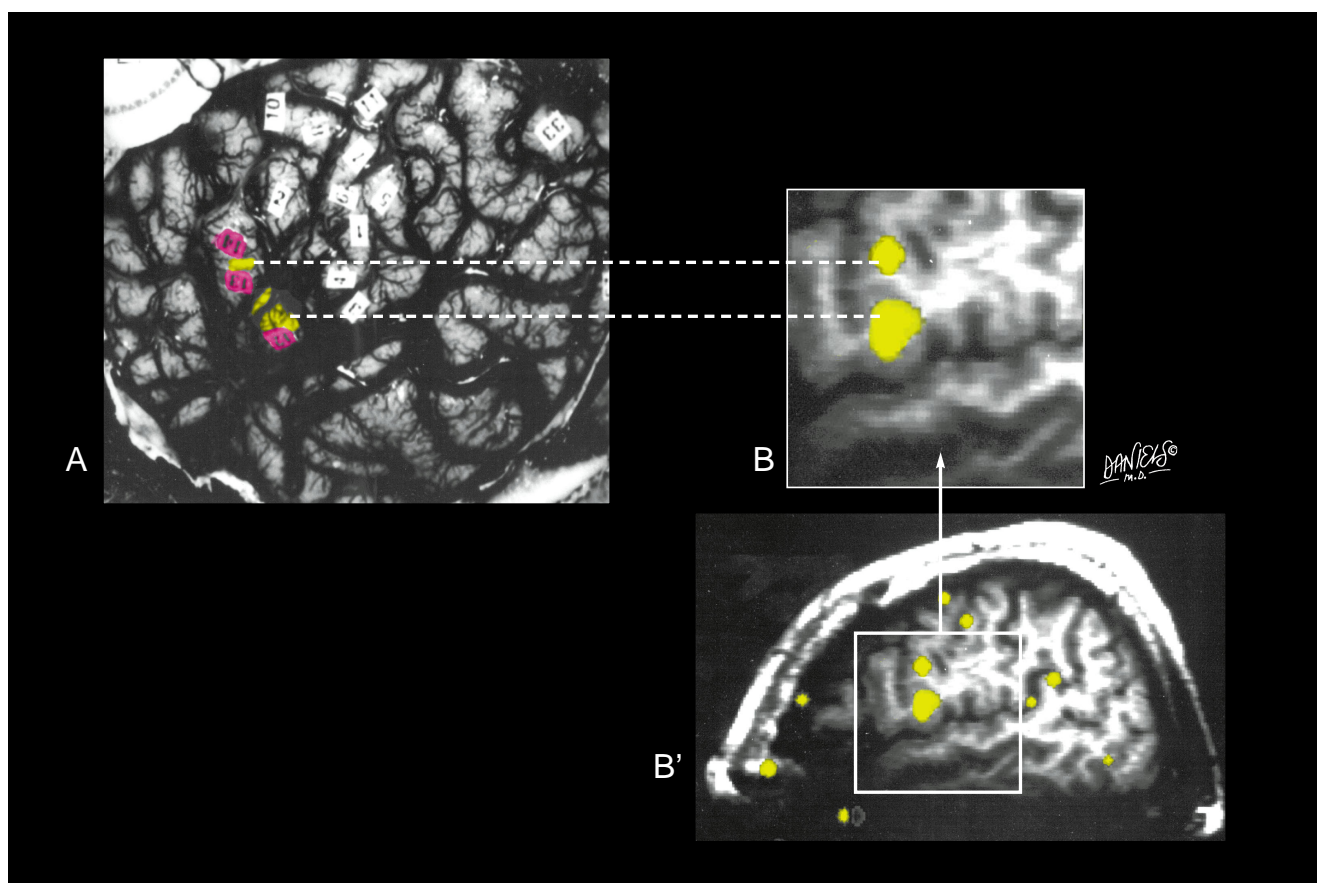


Fig 1. Comparison of a photographic recording of intraoperative mapping (A) and a functional MR image (B') in a patient with epilepsy. The sylvian fissure is evident in both. In the photograph, 12, 13, and 14 represent locations at which stimulation interrupted the patient's speaking. In the functional MR image, the cortical activation from the silent word generation task is shown. After scaling (B) the functional MR image and superimposing it on the photograph, the location of activation is seen to overlap markers 12 and 13.

tion caused by counting or word generation was considered a language function and was compared with the intraoperative mapping site at which stimulation interrupted speaking or counting. Functional MR imaging activation produced by apposing the first finger and thumb was compared with the mapping site at which stimulation caused the contralateral hand or any finger to move. Activation caused by the lip pursing task was compared with the intraoperative site at which stimulation caused the lips to twitch or move in any way. Activation caused by the tongue movement task was compared with the intraoperative site at which stimulation produced any tongue movement or sensation of movement.

The photograph of the surgical site and the most superficial functional MR image that showed activation (usually No. 7) were converted to bit maps (Fig 1). The bit maps were adjusted to the same scale by using a centimeter scale on the photograph and the matrix and field-of-view dimensions on the functional MR image. The images were coregistered by using a commercial graphics program (Adobe Photoshop, Adobe Systems Inc, San Jose, Calif). For this purpose, the sulci and the veins visible in the photograph were superimposed as precisely as possible

on the corresponding veins and sulci visible in the functional MR image. The coregistration was performed to maximize the closeness of the fit of the anatomic landmarks in the region of the activation. The spoiled gradient-echo images were used to help identify the location of the larger convexity veins in the functional MR image. The distance between the center of the cortical stimulation site for a specific function and the center of the nearest activation site for the function was measured with the graphics software. For activation from the language tasks with multiple activated pixels that were not contiguous, the distance between the closest activated pixel and intraoperative site was measured. The distances were grouped into categories of less than 1 cm, 1 to 2 cm, and 2 cm or greater.

Results

Twenty-eight patients had functional MR imaging and intraoperative mapping. In all cases activation was obtained from finger movement and from word generation or counting. The pa-

tients had chronic epilepsy ($n = 22$), cerebral tumors ($n = 5$), and an arteriovenous malformation ($n = 1$). The left hemisphere was mapped intraoperatively in 20 patients and the right in eight. Intraoperative mapping was performed as needed in the portions of the temporal, inferior frontal, and parietal lobes that were exposed at surgery.

In the 28 patients, 43 comparisons were obtained between an intraoperatively mapped function and a function mapped at MR imaging. Comparisons included the word generation task in 13 patients, the counting task in 13 patients, the finger movement task in eight patients, the lip movement task in six patients, and the tongue movement task in three patients. Of the comparisons made for word generation, 12 were made in the left hemisphere and one in the right hemisphere; of the counting tasks compared, 10 were in the left hemisphere and three in the right hemisphere.

Technically satisfactory functional MR imaging maps were obtained for the 43 comparisons. In all 28 patients, the counting and word generation tasks activated predominantly the inferior frontal gyral regions; the finger, lip, and tongue motor tasks activated a region at the frontoparietal junction. The finger movement task activated primarily the hemisphere contralateral to the finger moved, while the tongue and lip movement tasks activated regions in both hemispheres.

For all the comparisons, the area of activation on the functional image was 20 mm or less from the intraoperative measurement; in 37 (86%) of the 43 comparisons, it was within 10 mm. Word generation, finger movement, hand movement, and tongue movement tended to map more closely to the intraoperative measurement; counting and lip movement tended to map less closely. However, the differences between any of the tasks and the average for the group were not significant (within the 95% confidence limit for the group average). Of the five instances in which both counting and word generation were compared in the same person, the distances were the same in three and differed by 10 mm or less in two.

The activations that were not within 10 mm included two from the lip movement task (15 and 20 mm, respectively), two from the counting task (20 mm), one from the word generation task (15 mm), and one from the finger movement task (15 mm). In one of the two patients in

whom the right hemisphere was mapped intraoperatively, activation on the functional MR image was 20 mm from the site at which electrical stimulation interrupted counting. One counting activation in the right hemisphere was 20 mm from the site mapped during surgery. The one comparison in the right hemisphere between activation from word generation and an intraoperative speech location was within 10 mm.

Discussion

This study shows that in a series of 28 patients, the area of activation on a functional MR image produced by performance of a task and the site mapped intraoperatively during performance of a similar task were within 2 cm. Good correlations have also been reported in previous studies. In one study, the location of activation caused by hand motion was compared with intraoperative stimulation mapping of the cerebral cortex at craniotomy in six patients (4). Activation detected with fast low-angle shot images acquired during rest and hand movement was found in a "diffuse area" in the postcentral and precentral gyri, where intraoperative mapping demonstrated function. In another study of two patients, activation for hand, foot, and face was recorded with a spoiled gradient-echo acquisition at 1.5 T. In one patient, the activation was compared with motor function mapped by means of subdural electrodes and in the other by evoked potentials recorded on the brain surface after median nerve stimulation. Results of functional MR imaging and cortical mapping matched in these two cases (5). Our study includes activation from word generation, counting, and motor tasks, correlated with intraoperative mapping of comparable functions.

The accuracy of the functional MR imaging activation compares well with the estimates of precision for functional MR imaging and of intraoperative mapping. The pixels in the functional images for this experiment measured $10 \times 3.75 \times 3.75$ mm. Distortion in the echo-planar images was estimated to reach one pixel. Reproducibility studies of functional MR imaging indicate that while the first and second iteration of a task produced a similar number of activated pixels in a similar location, 50% to 80% of the pixels are common to both activations (10). On the basis of these observations, activation is estimated to locate the neuronal activity with a precision of about 5 mm. While

the intraoperative stimulation method is considered the standard of reference for functional mapping, its precision, because of the spread of current through the cerebral cortex, is about 10 mm (11). Therefore, the accuracy of distance measurements between the functional MR imaging activation and the intraoperative location is limited to 15 to 20 mm. The six instances in which the functional MR imaging and the intraoperative localization were 2 cm distant from each other may represent the cumulative inaccuracies in the measurements.

The methodological problems in comparing functional MR imaging activation and intraoperative mapping are significant. The task paradigm necessary for good activation is repetitive performance of a task, whereas the effect of stimulating the cerebral cortex is a single event. Furthermore, the movement produced by stimulation does not replicate exactly the task paradigm used for functional MR imaging. Intraoperative mapping may show a single site for function or multiple overlapping sites for individual wrist and finger movements (12). Intraoperative cortical stimulation identifies only those eloquent brain regions that are on the surface of the brain (11), whereas functional MR imaging maps both superficial and deep regions of activation. Generally, only one hemisphere is studied with cortical stimulation mapping, although activation from some tasks may be bilateral. In our study, right hemisphere language localization was studied without reference to possible left hemisphere contributions, since only one hemisphere is exposed for intraoperative mapping. When a function has bilateral representation, the cortical stimulation mapping may less reliably produce a "temporary lesion" (12).

This study helps to confirm the spatial accuracy of functional MR imaging. The region of activation shown on functional MR images is presumed to represent a region in which blood flow increases as the result of neuronal activity. To what degree the blood flow changes correlate spatially with the active neurons is not known. In principle, some of the signal intensity changes detected on functional MR images may occur in draining veins some distance from the site of activity. While additional studies are needed to verify the spatial specificity of the functional MR imaging activation, our data suggest that the regions of activation on functional

MR images correspond to regions of significant neuronal activity demonstrated by intraoperative mapping techniques.

Although functional MR imaging is not being evaluated as a replacement for intraoperative mapping, it may have applications in preoperative evaluation if it correlates well with intraoperative mapping. Whether activation from word generation or counting identifies all the frontal lobe regions necessary for language function is not known. For the sensorimotor cortex, functional MR imaging identifies activation that is deep in the central sulcus that may not be detected with stimulation of the brain surface. Nevertheless, functional MR imaging represents a noninvasive means of anticipating the results of cortical mapping and of determining the probable margin between the eloquent brain region and the portion of the brain to be resected.

References

1. Mueller WM, Yetkin FZ, Hammeke TA, et al. Functional magnetic resonance imaging mapping of the motor cortex in patients with cerebral tumors. *Neurosurgery* 1996;19:515-521
2. Berger MS, Ojemann GA. Intraoperative brain mapping techniques in neuro-oncology. *Stereotact Funct Neurosurg* 1992;58:153-161
3. Ojemann GA, Creutzfeldt OD, Lettich E. Neuronal activity in human temporal cortex related to naming and short-term verbal memory. In: Engel J Jr, ed. *Fundamental Mechanisms of Human Brain Function*. New York, NY: Raven Press; 1987:61-68
4. Yousry TA, Schmid UD, Jassoy AG, et al. Topography of the cortical motor hand area: prospective study with functional MR imaging and direct motor mapping. *Radiology* 1995;195:23-29
5. Jack JR Jr, Thompson R, Butts RK, et al. Sensory motor cortex: presurgical mapping with functional MR imaging and invasive cortical mapping. *Radiology* 1994;190:85-92
6. Bandettini PA, Jesmanowicz A, Wong EC, et al. Processing strategies for time-course data sets in functional MRI of the human brain. *Magn Reson Med* 1993;30:161-173
7. Yetkin FZ, Hammeke TA, Swanson SJ, et al. A comparison of functional MR activation patterns during silent and audible language tasks. *AJNR Am J Neuroradiol* 1995;16:1087-1092
8. Bandettini PA, Wong EC, Hincks PS, et al. Time course EPI of human brain function during task activation. *J Magn Reson* 1992;25:390-397
9. Hammeke TA, Yetkin FZ, Mueller WM, et al. Functional magnetic resonance imaging of somatosensory stimulation. *Neurosurgery* 1994;35:677-681
10. Yetkin FZ, McAuliffe TL, Cox R, Haughton VM. Test-retest precision of functional MR in sensory and motor task activation. *AJNR Am J Neuroradiol* 1996;17:95-98
11. Ojemann G. Brain organization for language from the perspective of electrical stimulation mapping. *Behav Brain Sci* 1983;6:189-206
12. Sanes JN, Donoghue JP, Thangaraj V, Edelman RR, Warach S. Shared neural substrates controlling hand movements in human motor cortex. *Science* 1995;268:1775-1777