

# Generic Contrast Agents

Our portfolio is growing to serve you better. Now you have a *choice*.



[VIEW CATALOG](#)

# AJNR

## **Clinical and economic impact of incidental thyroid lesions found with CT and MR.**

D M Yousem, T Huang, L A Loevner and C P Langlotz

*AJNR Am J Neuroradiol* 1997, 18 (8) 1423-1428

<http://www.ajnr.org/content/18/8/1423>

This information is current as  
of May 20, 2025.

# Clinical and Economic Impact of Incidental Thyroid Lesions Found with CT and MR

David M. Yousem, Tammy Huang, Laurie A. Loevner, and Curtis P. Langlotz

**PURPOSE:** To estimate the prevalence and the clinical and economic consequences of management strategies for thyroid lesions detected incidentally on cross-sectional imaging of the head and neck. **METHODS:** Two hundred consecutive CT scans and 200 consecutive MR images of the neck performed over a 1-year period in patients being examined for other purposes were reviewed retrospectively to determine the prevalence of unexpected thyroid lesions. After excluding patients with prior thyroidectomies, known thyroid disease, and inadequate examinations, 231 imaging studies were analyzed. **RESULTS:** Incidental thyroid lesions were originally reported in 14 (6%) of the 231 patients, but an additional 22 (9.5%) were found on retrospective review for a total of nearly 16% (36 of 231). Six of the 36 patients received further workup, consisting of nuclear medicine scintigraphy (n = 3), sonography (n = 3), thyroid function tests (n = 5), fine-needle aspiration (n = 4), and thyroid lobectomy (n = 1). Final diagnoses, obtained in four of the six patients, included three multinodular goiters and one follicular adenoma. Two patients, one with nondiagnostic findings at fine-needle aspiration and a second with normal thyroid function test results, are being followed up. The mean cost of the workup and treatment per examined patient was \$1158. **CONCLUSION:** Incidental thyroid lesions are frequently present and often overlooked on cross-sectional images of the neck in patients being examined for other reasons. The cost of pursuing a workup of these lesions and their high prevalence in the population raise questions regarding appropriate management strategies.

**Index terms:** Efficacy studies; Thyroid gland, abnormalities and anomalies

*AJNR Am J Neuroradiol* 18:1423–1428, September 1997

Incidental thyroid abnormalities are common in asymptomatic patients, but the vast majority of them are benign. It has been estimated that approximately 6% of women and 2% of men have solitary or multiple nodules in their thyroid glands on palpation (1, 2), and that more than 25% of the healthy population may have some nodularity to their glands on sonographic studies (3, 4). Furthermore, 50% of asymptomatic persons show focal nodular lesions in the thyroid gland at postmortem histopathologic examination (1).

We reviewed our experience in the detection

and management of incidental thyroid lesions in patients being studied for other reasons in order to understand and quantify the clinical and economic ramifications for the patient and the health care system when a nonspecific thyroidal nodule is incidentally noted at computed tomography (CT) or magnetic resonance (MR) imaging of the neck.

## Materials and Methods

Four hundred consecutive enhanced imaging studies (200 CT scans and 200 MR images) of the neck obtained within a 1-year period (1994) at our institution were reviewed retrospectively by one of two head and neck neuroradiologists working independently to ascertain the incidence of incidental thyroid lesions. One hundred sixty-nine studies were eliminated because they 1) did not include the full extent of the thyroid gland, 2) were performed for suspected thyroid disease, 3) were performed in patients with known thyroid disease, 4) were of insufficient quality to evaluate the thyroid gland, or 5) were repeat studies on

---

Received November 27, 1996; accepted after revision March 17, 1997.

From the Department Radiology, Hospital of the University of Pennsylvania, 3400 Spruce St, Philadelphia, PA 19104. Address reprint requests to David M. Yousem, MD.

*AJNR* 18:1423–1428, Sep 1997 0195-6108/97/1808–1423

© American Society of Neuroradiology

the same patient. The remaining 231 studies (123 CT scans and 108 MR images) composed the study sample. There were 133 studies in men (58%) and 98 in women (42%). Mean age of the patients was 56 years (range, 16 to 89 years). Over 80% of the cases were referred for staging of a head and neck squamous cell carcinoma. All positive imaging studies for thyroid lesions reported herein were identified by one reader and then confirmed by a consensus reading of both neuroradiologists. In those patients with incidental thyroid lesions discovered on the retrospective review, the dictated report from the original reading of the study was surveyed to see whether the abnormality was mentioned. There were no instances in which a thyroid abnormality reported originally was not detected at the retrospective review.

All CT examinations were performed with either an HSA or 9800 Quick scanner (General Electric Medical Systems, Milwaukee, Wis). The patient was placed in the supine position with the neck extended in a modified coronal head-holder and was asked to breathe quietly and resist swallowing during acquisitions. Axial scans were obtained with 3- to 5-mm-thick contiguous sections from the cavernous sinuses to the thoracic inlet. The field of view was 22 × 22 cm. The total scan time was 1 to 1.5 minutes (HSA) to 5 to 10 minutes (9800 Quick), and the dosage was 300 to 340 mAs at 140 kV. A total of 150 mL iohalamate meglumine was administered intravenously by an injector with an automated two-phasic program consisting of an initial 100-mL bolus at 2 mL/s followed by 50 mL at 1 mL/s. Scanning was initiated after a 50-second delay.

MR imaging was performed on a 1.5-T Signa System (General Electric), and included 5-mm-thick contiguous T1-weighted images, fat-suppressed fast spin-echo T2-weighted images, and fat-suppressed contrast-enhanced T1-weighted images. Gadolinium contrast agents were injected at standard doses (0.1 mmol/kg for gadopentetate dimeglumine injected over 20 seconds).

The clinical consequences of incidentally discovered thyroid lesions were determined by chart review, phone conversations with clinicians, subsequent imaging studies, and clinical follow-up. The medical record was reviewed to determine what studies were subsequently performed to evaluate the thyroid lesion (for those detected on the original examination). Office notes, radiologic and pathologic reports, and medical records were also surveyed to ascertain whether any lesion not subsequently worked up became clinically evident.

The base rate and 95% confidence intervals (CIs) were computed for the prevalence of incidental lesions. We also calculated the proportion of lesions detected at the original examination, and the rate at which surgeons elected to pursue further workup.

We estimated the cost of each medical service rendered for purposes of evaluating the incidental thyroid lesion. The Medicare Resource-Based Relative Value Scale was used to estimate outpatient costs and relevant inpatient professional costs. Medicare departmental ratios of costs to charges for our institution were used to estimate the

**TABLE 1: Procedures, current procedural terminology codes, and costs**

Service Description	Code(s)	Total Cost, \$*
Thyroid panel with thyrotropin	80092	33
Echography, soft tissues of head and neck	76536	80
Fine-needle aspiration, evaluation of smear, interpretation of smear, office visit (level 2)	88170, 88172, 88173, 99212	197
Thyroid imaging with uptake	78006	111
Thyroid procedures	DRG290	5161

Note.—DRG indicates diagnostic related group.

\* Total costs include both technical and professional costs.

technical component of the costs (Table 1). Each service rendered was multiplied by its estimated cost. These costs were summed for each patient to determine the total incremental cost of each patient's workup. Total and mean incremental costs for the entire study sample were calculated under three scenarios: 1) the workup that actually occurred; 2) the workup that would have occurred if all lesions had been detected on the original study and a similar proportion of thyroid lesions had been worked up; and 3) the workup that would have occurred if all lesions had been detected on the original study and all detected lesions had been worked up.

## Results

Incidental thyroid lesions were discovered on the retrospective review in 36 (16%; 95% CI, 11.5% to 21%) of the 231 patients. In the original dictation, lesions were reported in 14 of these 36 patients (6% of the original 231 subjects), while the remaining 22 lesions (9.5%) were not reported. There were no lesions reported in the original dictations that were not discovered on retrospective review by the two neuroradiologists. All the lesions detected had a size greater than or equal to 5 mm in one dimension.

Of the 14 patients in whom lesions were reported in the original dictations, six (43%) had subsequent studies to elucidate the pathogenesis of the lesion. Three had nuclear medicine scintigraphy, three had sonography, and five had thyroid function tests (Table 2). Fine-needle aspiration (FNA) was performed in four patients. Three patients carried a final diagnosis of multinodular goiter (two diagnosed by cytologic examination and one by imaging/clinical examination) (Fig 1). One patient had a cold nodule at nuclear scintigraphy, indeterminate FNA results, and a thyroidectomy, which revealed a

TABLE 2: Workups of six patients with incidental thyroid lesions

Case	Studies Performed	Cost of Workup, \$	Final Diagnosis
1	TFT	33	None
2	TFT, sonography	113	Multinodular goiter
3	Sonography, FNA	277	Multinodular goiter
4	TFT (×3), NM, FNA	407	Multinodular goiter
5	TFT, sonography, NM, FNA	421	None
6	TFT, NM, FNA (×2), thyroidectomy	5699	Adenoma
<b>Total</b>		<b>6950</b>	
Mean (all patients)		1158	
Mean without patient who had surgery		250	

Note.—TFT indicates thyroid function tests; FNA, fine-needle aspiration; and NM, nuclear medicine scintigraphy.

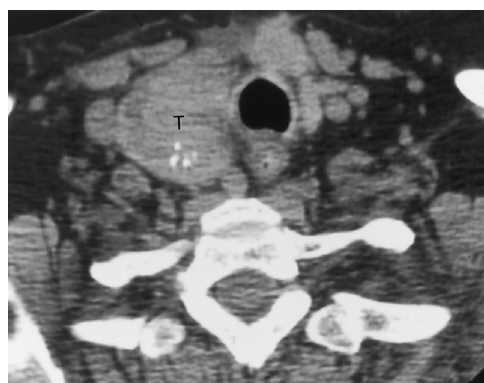

Fig 1. Incidental right thyroid mass reported on initial examination. Patient was being examined for a parotid abscess, but the unenhanced CT scan revealed a right thyroid mass (T) with stippled calcification. As the lesion was not palpable, a thyroid function test and a nuclear medicine study (revealing a cold lesion) were performed, and two specimens were obtained from CT-guided FNA, which showed changes of a multinodular goiter.

follicular adenoma within a multinodular goiter. No definitive final diagnosis was made in two patients (one with indeterminate FNA results), but they are both alive and well. None of the 14 patients was known to have had thyroid carcinoma develop by the follow-up 24 to 32 months later (median follow up, 31 months; mean, 30 months; standard deviation, 2 months).

Among the 22 patients in whom thyroid lesions were not found at the initial examination but were discovered on retrospective review, none had subsequent imaging or evaluation of the thyroid. And none of these patients (one patient was lost to follow-up) had clinical findings suggestive of thyroid cancer on follow-up (median follow-up, 29 months; mean, 28 months; standard deviation, 3 months; range, 23 to 32 months).

Table 2 shows cost estimates for the range of medical services provided as part of the six

workups that were undertaken. Table 3 shows the results of an analysis in which these costs were used to estimate the incremental costs of workup for three scenarios. Results from the first scenario show that \$6950 in costs were actually incurred by the patients in our study sample. The second scenario projects the incremental costs that might have been incurred if all the lesions subsequently detected in this study had been mentioned in the original report. We assumed that none of these lesions would result in thyroid surgery; consequently, the mean cost per nonsurgical workup served as an estimate of workup cost for the additional lesions. For this second scenario, we assumed that only 43% of these additional lesions would trigger a workup, since only six (43%) of 14 lesions were worked up when the lesions were reported in the official reading. A total incremental workup cost of \$9307 resulted [(22 new lesions) × (43% worked up) × (mean cost per nonsurgical workup of \$250)] + \$6950 (cost to work up six patients who had thyroid lesions reported) = \$9307 (mean, \$665 for 14 patients worked up). Using the same method, we projected that \$14 450 in costs would result if all 36 incidental thyroid lesions were detected and worked up [(30 incidental lesions not worked up) × (\$250 for nonsurgical workup)] + \$6950 (cost to work up six patients who had thyroid lesions reported) = \$14 450 (mean, \$401 for 36 patients worked up nonsurgically).

Assuming the same proportion of patients went on to surgery as the six initially worked up (17%), with the mean cost of the workup of those six being \$1158, then the total cost to work up 43% of the 22 new patients would be \$10 919 (mean, \$863 for 14 patients worked

TABLE 3: Scenarios for various workup profiles (nonsurgical workups)

Clinical Scenario	No. of Workups	Malignant Neoplasms Detected (95% CI)	Incremental Cost, \$	Mean Cost per Workup, \$	Mean Cost per Examination, \$
Actual (low detection rate; selective workup)	6	0 (0–3.7)	6950	1158	30
Optimal detection rate; selective workup	14	0 (0–3.7)	9307	665	40
Optimal detection rate; universal workup	36	0 (0–3.7)	14 450	401	63

Note.—CI indicates confidence interval.

up). If all 36 patients were worked up in the fashion of the six reported, the cost would be (36 patients  $\times$  \$1158 mean cost for six patients) \$41 688 (mean, \$1158 for 36 patients worked up).

## Discussion

Several autopsy series have cited prevalence rates for occult thyroid carcinoma ranging from 6.5% to 28% (5–9). A wide variation between different geographic areas has also been found; the Japanese have a particularly high rate of thyroid cancer while North Americans have a lower rate (8–10). Even within specific geographic regions, such as in the Scandinavian countries, the prevalence rate of occult papillary carcinoma of the thyroid gland has ranged from 6% to 36% in Finland, based on autopsy studies (6, 10–12). Multifocal malignant disease at autopsy is not uncommon (approximately 10%) (1, 11). At the same time, screening sonographic studies have shown focal lesions in 27% of all subjects and in 36% of middle-aged Finnish women (3, 4). In patients with hyperparathyroidism, the prevalence is even higher: sonographic and MR studies of these patients have reported nodules in the thyroid gland at a rate of 40% to 45% (13, 14).

Clinically, how does one know when to get concerned about the incidentally detected thyroid lesion? Since any nodule could represent an early thyroid cancer, the challenge lies in identifying those lesions that are malignant in the most cost-effective, noninvasive manner. Any patient with a history of irradiation, growth of the nodule over time, hoarseness (suggesting recurrent laryngeal nerve infiltration), multiple endocrine neoplasia syndromes, a family history of thyroid cancer, fixation of the nodule to adjacent structures, or regional lymphadenopathy deserves a more aggressive approach to this finding (15). Appearance of a thyroid nod-

ule in the very young or very old and in male subjects is worrisome for carcinoma. FNA might be justified in this patient population, directed either by palpation or sonography. Unfortunately, indeterminate thyroid aspirations are not uncommon (approximately 20%) in most published series (2, 15–19). Superimposed on these statistics is the natural course of differentiated thyroid cancer, which is compatible with long-term survival. The prognosis for patients with thyroid cancer is generally measured in decades rather than years when it is of the follicular or papillary type. However, the anaplastic and undifferentiated types tend to have a poor prognosis, with survival measured in months.

No malignant lesions were definitively detected in our study sample, but the follow-up in our study was short for thyroid cancers (just 2 years on average) and pathologic confirmation was limited to FNAs and just one patient with histologic confirmation. In one follow-up study of palpable nontoxic thyroid nodules from the Framingham, Mass, constituency ( $n = 5127$  subjects, 30 to 50 years old), no malignant thyroid lesions were identified on 15-year follow-up studies in 218 persons with a palpable thyroid nodule (20). Within the 15 years, 67 new lesions were palpated and, again, none of these proved to be malignant. The sample size of our study is not sufficient to exclude the possibility that patient outcomes and the prognosis for malignant lesions could be improved by working up incidentally detected thyroid lesions. However, our study raises the question as to what incremental health benefits arise from extensive workup of nonpalpable thyroid lesions.

The cost of examining a patient with an incidental thyroid nodule detected on a neck imaging study performed for other reasons can range from hundreds to thousands of dollars, depending on the extent of the examination performed. At the same time, as the sensitivity of imaging

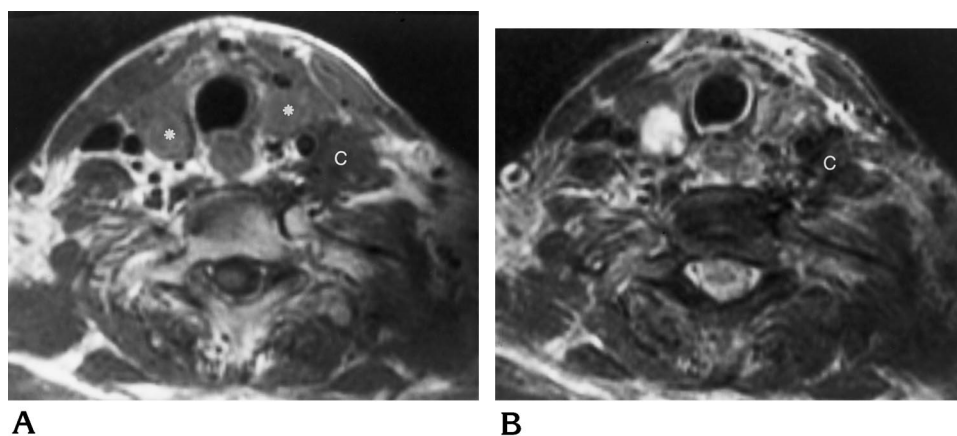


Fig 2. Nonspecific thyroid masses not reported on first reading.

A, T1-weighted MR image (600/11/2) shows bilateral well-defined masses (*asterisks*) in the inferior thyroid gland of a man being examined for nodal spread of squamous cell carcinoma (C).

B, The right nodule is hyperintense and the left nodule is intermediate in intensity on T2-weighted image (4000/80/2). Squamous cell carcinoma (C) is dark.

studies has increased, more and more patients (and referring clinicians) are facing this quandary (21, 22). Black and Welch (21) and Feldman et al (22) have noted that as imaging studies are able to detect cancers at an earlier and earlier stage, there is a cycle of increasing intervention that may confer little benefit to patient outcome. False perceptions of the natural history of a disease and therapeutic effectiveness are created when imaging detects subclinical disease—patients appear to live longer with the disease, and treatments seem to confer better responses, when the disease may never have become clinically apparent. “There is no way of accurately estimating the probability that a subclinically detected abnormality will naturally progress to an adverse outcome” (21, 22). In the case of most forms of thyroid cancer, which have an exceptionally benign course and an excellent response to conventional therapies, the value of detecting nonpalpable thyroid cancers may be called into question. Black and Welch (23) also refer to the concept of “pseudodisease,” which is inapparent disease that would never produce signs or symptoms during the patient’s lifetime. The disease may not progress (type I pseudodisease) or may progress at so slow a rate that it never comes to attention and the patient dies of other causes (type II pseudodisease). Given the high rate of subclinical malignant thyroid lesions found at autopsy, thyroid carcinoma may exhibit both types of pseudodisease. This also makes defining a critical point of therapy (before which treatment of incidentally detected thyroid cancer is most effective) difficult to ascertain. We recommend more research into these issues.

The low rate of detection of thyroid lesions reported in the original dictations of the neck

studies described herein (14, or 39%, of the 36 lesions found on retrospective review) could be a reflection of the peripheral location of the gland with respect to the primary reason for imaging a patient, usually to stage an aerodigestive tract squamous cell carcinoma. Thyroid lesions by and large are easily detectable on CT scans, since the native thyroid tissue (with and without contrast administration) is of high attenuation owing to its iodine content. Most lesions are seen as a low-density nodule within the hyperdense gland. Similarly, most lesions are readily detectable on T2-weighted MR images as hyperintense masses or on fat-suppressed contrast-enhanced T1-weighted images as non-enhancing lesions within the hyperintense gland (Fig 2). Nondetection, therefore, is likely to be a mistake of neglect rather than sensitivity.

Inherent to this discussion is the notion that imaging features do not distinguish malignant from benign nodules of the thyroid gland. Except in those infrequent circumstances in which benignity (a pure cyst at sonography, CT, or MR imaging, or a hot nodule on thyroid scintigraphy) or malignancy (invasion into adjacent viscera, pathologic lymphadenopathy, or distant metastases) is nearly assured, no reliable imaging features can be used to predict the histology of a nondescript mass in the thyroid gland. Calcification, hemorrhage, colloid accumulation, cyst formation, necrosis, multifocality, and irregular and regular margins may be seen in benign or malignant masses of the thyroid gland (24–32).

There is a near audible groan from the head and neck surgeon as the radiologist comments on an incidental thyroid mass in a patient being staged for a head and neck squamous cell carcinoma. How obligated is the surgeon to sample

the lesion if it is not palpable and does not have typical benign features on imaging that would preclude a formal evaluation of the mass? Assuming a modest rate of 16% of patients have a thyroidal abnormality on 1 year's worth of CT scans ( $n = 471$ ) and MR images ( $n = 594$ ) of the neck at our institution, and assuming the mean cost of working up the patients is between \$30 and \$63 per examination (as demonstrated in this study), the annual cost for pursuing incidental thyroid nodules would run \$67 095 just at our hospital. Can we treat inhomogeneity in the thyroid gland like the classic "unidentified bright object" of the white matter—as an age-related phenomenon that does not warrant a massive workup? One thing is clear: As we become more cognizant of detecting and reporting incidental thyroid lesions, radiologists, internists, surgeons, and third-party payers must question a policy of universal evaluation. We hope that this study engenders a prospective multiinstitutional longitudinal study to look at this issue.

## References

- Mortensen JD, Woolner LB, Bennett WA. Gross and microscopic findings in clinically normal thyroid glands. *J Clin Endocrinol* 1955;15:1270–1280
- Mazzaferri EL, de los Santos ET, Rofagha-Keyhani S. Solitary thyroid nodule: diagnosis and management. *Med Clin of North Am* 1988;72:1177–1211
- Brander A, Viikinkoski P, Nickels J, Kivisaari L. Thyroid gland: US screening in a random adult population. *Radiology* 1991;181:683–687
- Brander A, Viikinkoski P, Nickels J, Kivisaari L. Thyroid gland: US screening in middle-aged women with no previous thyroid disease. *Radiology* 1989;173:507–510
- Bondeson L, Ljungberg O. Occult papillary thyroid carcinoma in the young and the aged. *Cancer* 1984;53:1790–1792
- Bondeson L, Ljungberg O. Occult thyroid carcinoma at autopsy in Malmö, Sweden. *Cancer* 1981;47:319–323
- Sobrinho-Simoes MA, Sambade MC, Goncalves V. Latent thyroid carcinoma at autopsy: a study from Oporto, Portugal. *Cancer* 1979;43:1702–1706
- Fukunaga FH, Yatani R, Sasano N. Thyroid carcinoma in Sendai, Japan. *Tohoku J Exp Med* 1974;113:181–185
- Fukunaga FH, Lockett LJ. Thyroid carcinoma in the Japanese in Hawaii. *Arch Pathol* 1971;92:6–13
- Fukunaga FH, Yatani R. Geographic pathology of occult thyroid carcinomas. *Cancer* 1975;36:1095–1099
- Harach HR, Franssila KO, Wasenius VM. Occult papillary carcinoma of the thyroid, a "normal" finding in Finland: a systematic autopsy study. *Cancer* 1985;56:531–538
- Franssila K, Saxen E, Teppo L. Incidence of different morphological types of thyroid cancer in the nordic countries. *Acta Pathol Microbiol Scand Sect A* 1981;89:49–55
- Funari M, Campos Z, Gooding GA, Higgins CB. MRI and ultrasound detection of asymptomatic thyroid nodules in hyperparathyroidism. *J Comput Assist Tomogr* 1992;16:615–619
- Stark DD, Clark OH, Gooding GA, Moss AA. High-resolution ultrasonography and computed tomography of thyroid lesions in patients with hyperparathyroidism. *Surgery* 1983;94:863–868
- Woeber KA. Cost-effective evaluation of the patient with a thyroid nodule. *Surg Clin North Am* 1995;75:357–363
- Mazzaferri EL. Management of a solitary thyroid nodule [see comments]. *N Engl J Med* 1993;328:553–559
- Caplan RH, Strutt PJ, Kiskien WA, Wester SM. Fine needle aspiration biopsy of thyroid nodules. *Wis Med J* 1991;90:285–288
- Caplan RH, Wester S, Kiskien WA. Fine-needle aspiration biopsy of solitary thyroid nodules: effect on cost of management, frequency of thyroid surgery, and operative yield of thyroid malignancy. *Minn Med* 1986;69:189–192
- Piomalli D, Martelli G, Del Prato I, Collini P, Pilotti S. The role of fine needle aspiration in the diagnosis of thyroid nodules: analysis of 795 consecutive cases. *J Surg Oncol* 1992;50:247–250
- Vander JB, Gaston EA, Dawber TR. The significance of nontoxic thyroid nodules: final report of a 15-year study of the incidence of thyroid malignancy. *Ann Intern Med* 1968;69:537–540
- Black WC, Welch HG. Advances in diagnostic imaging and overestimations of disease prevalence and the benefits of therapy. *N Engl J Med* 1993;328:1237–1243
- Feldman AR, Kessler L, Myers MH, Naughton MD. The prevalence of cancer: estimates based on the Connecticut Tumor Registry. *N Engl J Med* 1986;315:1394–1397
- Black WC, Welch HG. Screening for disease. *AJR Am J Roentgenol* 1997;168:3–11
- Solbiati L, Giangrande A, De Pra Lea. Percutaneous ethanol injection of parathyroid tumors and ultrasound guidance: treatment for secondary hyperparathyroidism. *Radiology* 1985;155:607–610
- Yousem DM, Scheff AM. Thyroid and parathyroid gland pathology: role of imaging. *Otolaryngol Clin North Am* 1995;28:621–649
- Christensen SB, Bondeson L, Ericsson UB, Lindholm K. Prediction of malignancy in the solitary thyroid nodule by physical examination, thyroid scan, fine-needle biopsy and serum thyroglobulin: a prospective study of 100 surgically treated patients. *Acta Chir Scand* 1984;150:433–439
- Gooding GA. Sonography of the thyroid and parathyroid. *Radiol Clin North Am* 1993;31:967–989
- Som PM, Brandwein M, Lidov H, Lawson W, Biller HF. The varied presentations of papillary thyroid carcinoma cervical nodal disease: CT and MR findings. *AJNR Am J Neuroradiol* 1994;15:1123–1128
- Ohnishi T, Noguchi S, Murakami N, et al. MR imaging in patients with primary thyroid lymphoma. *AJNR Am J Neuroradiol* 1992;13:1196–1198
- Shibata T, Noma S, Nakano Y, Konishi J. Primary thyroid lymphoma: MR appearance. *J Comput Assist Tomogr* 1991;15:629–633
- Takashima S, Ikezoe J, Morimoto S, et al. Primary thyroid lymphoma: evaluation with CT. *Radiology* 1988;168:765–768
- Takashima S, Morimoto S, Ikezoe J, et al. Primary thyroid lymphoma: comparison of CT and US assessment. *Radiology* 1989;171:439–443