

Generic Contrast Agents

Our portfolio is growing to serve you better. Now you have a *choice*.



FRESENIUS
KABI

[VIEW CATALOG](#)

AJNR

Aggressive fibromatosis of the neck: MR findings.

M Garant, H Remy and N Just

AJNR Am J Neuroradiol 1997, 18 (8) 1429-1431

<http://www.ajnr.org/content/18/8/1429>

This information is current as
of May 20, 2025.

Aggressive Fibromatosis of the Neck: MR Findings

M. Garant, H. Remy, and N. Just

Summary: We present a case of aggressive fibromatosis of the scalene and longus colli muscles with surgically proved secondary involvement of the brachial plexus and carotid sheath in a 29-year-old woman in whom MR imaging failed to show involvement of the carotid sheath. The well-defined lesion was isointense on T1-weighted images and hyperintense on T2-weighted images relative to adjacent normal muscle and enhanced brightly.

Index term: Neck, neoplasms

Aggressive fibromatosis is a rare locally infiltrative disorder of mesenchymal tissues. Fewer than 12% of cases involve the head and neck. Cross-sectional imaging is useful but might not fully depict the invasiveness of this process. We present the magnetic resonance (MR) imaging findings in a patient with aggressive fibromatosis of the scalene and longus colli muscles in whom involvement of the carotid sheath could not be predicted before surgery.

Case Report

A 29-year-old woman had a 1-year history of progressive fullness and intermittent pain in the right side of the neck. In the preceding few months, she had also experienced tingling in the right upper extremity. Her medical history was unremarkable except for recent childbirth and remote minor neck injury.

MR imaging showed homogeneous enlargement of the right anterior prevertebral muscles, mainly in the region of the scalene and longus colli muscles. The signal intensity of the lesion was similar to that of normal muscle on spin-echo T1-weighted images (Fig 1A and B), and hyperintense relative to normal muscle on long-repetition-time (TR) sequences (not shown). A few areas of vascular signal void were noted. After administration of intravenous contrast material, the lesion showed intense and homogeneous enhancement (Fig 1C and D), facilitating evaluation of its extent. The lesion, measuring approximately 12 cm

in length by 5 cm in width by 4 cm in thickness, appeared to be confined to the right prevertebral space of the infrahyoid portion of the neck, without extension through the neural foramina toward the spinal canal. It was in proximity to the intact C-2 to C-6 vertebral bodies. Even though the brachial plexus was not directly seen, it was most likely involved, given the location of the lesion. The adjacent visceral and right carotid spaces were displaced to the left, anterolaterally and anteriorly, respectively. There was no convincing evidence to suggest transfascial extension of the lesion, especially to the right carotid space. Also, there was no suspicious lymph node. Fine-needle aspiration cytology was suggestive of fibromatosis.

At surgery, the lesion was infiltrative and adherent, mostly to the right carotid space structures, including the wall of the carotid artery, but also to the brachial plexus; thus preventing complete excision. Branches of the thyrocervical trunk were surrounded by the lesion, which explained the areas of flow void seen at MR imaging. The lesion itself was relatively avascular. Pathologic examination of the resected specimen confirmed the presence of benign fibrous proliferation wrapping around blood vessels, nerves, and muscle bundles, without significant mitotic activity or necrosis. Adjacent nodes were free of tumor. Postoperative MR studies (not shown) depicted the presence of residual tumor in close relation to the right carotid space.

Discussion

Aggressive fibromatosis, also known as extraabdominal desmoid, is part of the spectrum of fibrous tissue proliferative disorders (1–7). There is a progression in the microscopic picture of fibrous tissue proliferations, starting with the normal reparative scar formation, followed by fibroma, keloid, pseudosarcomatous fasciitis, fibromatosis, differentiated fibrosarcoma, and undifferentiated fibrosarcoma (1, 3, 4). Aggressive fibromatosis occupies the middle position of that spectrum, and is distinguished

Received June 27, 1996; accepted after revision November 22.

From the Department of Department of Radiology, Montreal General Hospital (M.G., H.R.); and the SMBD Jewish General Hospital, McGill University (N.J.); Montreal, Quebec, Canada.

Address reprint requests to M. Garant, MD, Department of Diagnostic Radiological Sciences, Neuroradiology Section, Room B2-188 CHS, UCLA Medical Center, 10833 Le Conte Ave, Los Angeles, CA 90095.

AJNR 18:1429–1431, Sep 1997 0195-6108/97/1808–1429 © American Society of Neuroradiology

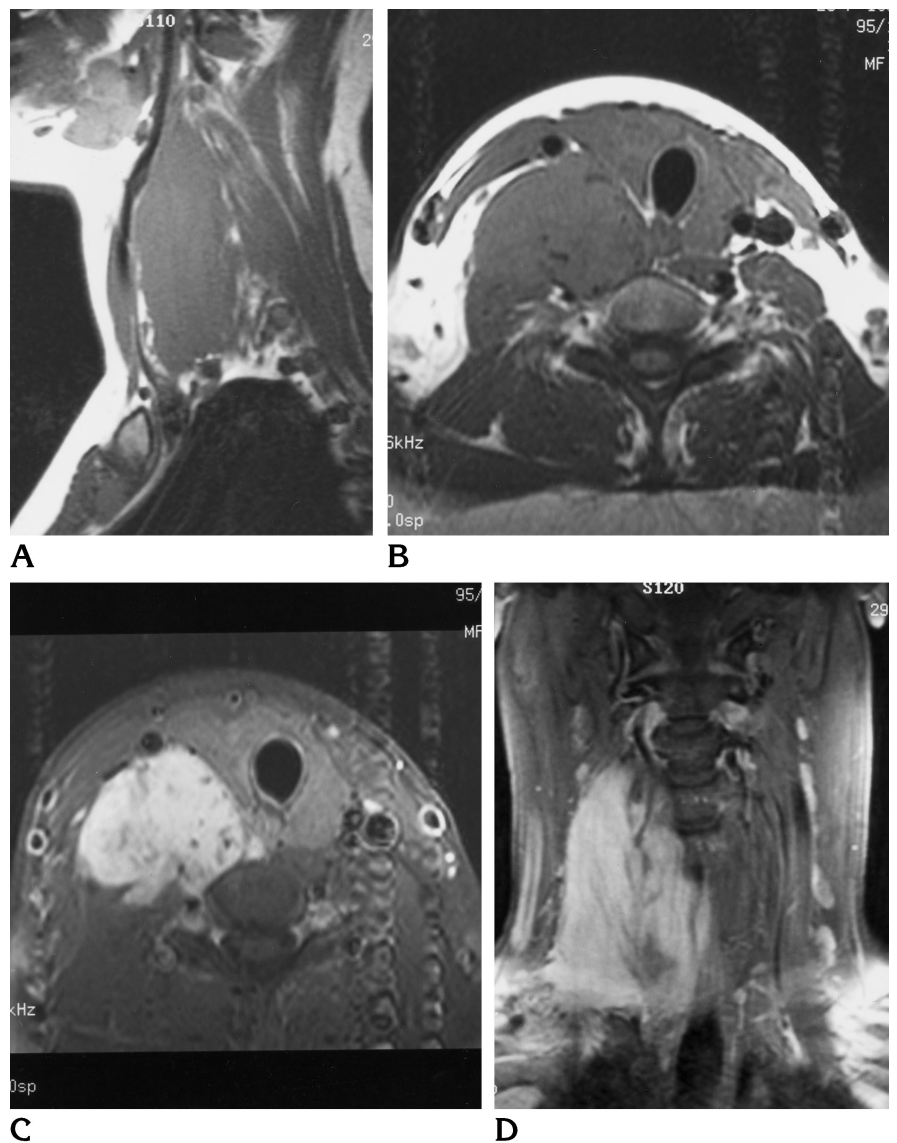
Fig 1. MR findings in a 29-year-old woman with aggressive fibromatosis of the neck.

A, Sagittal unenhanced spin-echo T1-weighted image (400/11/2 [repetition time/echo time/excitations]) shows homogeneous enlargement in the region of the right scalene muscles.

B, Axial unenhanced spin-echo T1-weighted image (600/14/2) shows the mass to be isointense with muscle. The adjacent visceral and right carotid spaces are displaced to the left, anterolaterally and anteriorly, respectively.

C, Axial enhanced spin-echo T1-weighted image (600/11/2) with fat saturation shows bright and relatively homogeneous enhancement in the region of the right scalene and longus colli muscles. The carotid sheath appears intact.

D, Coronal enhanced spin-echo T1-weighted image (600/11/2) with fat saturation shows the superoinferior extent of the lesion, from the C-2 to C-6 vertebral bodies.



from fibrosarcoma by its lack of anaplastic cells and absence of distant metastasis (1). Malignant degeneration of aggressive fibromatosis is exceedingly rare, but has been reported (1, 3).

Aggressive fibromatosis represents a locally infiltrative process composed of mature fibroblasts and collagen, without evidence of cellular anaplasia or abnormal mitotic figures (1–5, 8). Its exact pathogenesis remains unclear, but there may be an association with local trauma or surgery and exposure to estrogen and progesterone (1, 4, 6, 9–12). One case has reportedly occurred after radiation therapy for Hodgkin disease (6). Female subjects tend to be affected more commonly than male (1, 2, 13). The process also tends to involve a

younger population, mainly between puberty and 40 years old, but has been described in all age groups (1, 3, 13). There does not seem to be a predilection for any ethnic group (3). Two subtypes have been described: the superficial and deep types (3, 13). The superficial type is mostly limited to the wrist, hand, ankle, and foot (13). The deep type is similar to the one described in our patient. The remainder of the discussion will focus on this last type only.

Aggressive fibromatosis can virtually involve any part of the body (13). Seven percent to 12% will occur in the head and neck region (2, 3, 13). Of these, 85% will affect the neck (2). Multicentric fibromatosis is rare (1, 3). The clinical presentation is somewhat variable, but patients

typically present with a rapidly enlarging neck mass (over a period of months) that, in some instances, is painful (1, 3, 4). Involvement of adjacent nerves and vascular structures may occur (1, 3). Death subsequent to involvement of vital structures has also been reported (1).

Our patient presented with a neck mass that had been causing discomfort and pain for a year. Neurologic symptoms, mainly tingling in the right arm, had been present for a few months and were most likely related to involvement of the brachial plexus. A history of remote minor neck trauma was present. It remains unclear whether the recent pregnancy resulted in accelerated growth of the tumor. MR imaging revealed the presence of a mass in the right anterior prevertebral infrahyoid portion of the neck, related to the scalene and longus colli muscles. The mass was homogeneous and appeared well circumscribed on all pulse sequences. The lesion was isointense on T1-weighted images and hyperintense on long-repetition-time sequences. The signal characteristics were nonetheless nonspecific. The favored preoperative diagnosis was that of aggressive fibromatosis limited to the prevertebral space. The appearance of the lesion on long-repetition-time sequences did not exclude the diagnosis of fibrous tumor. Indeed, fibrous tumors have a variable appearance related to the cellular component of the lesion. The differential diagnoses included nerve sheath tumor, hemangioma, lymphoma, and metastasis (3).

The mainstay of therapy in patients with aggressive fibromatosis is en-bloc resection of the tumor, even though it can sometimes leave patients with functional and cosmetic deficits (1–5). Involvement of vital structures can prevent complete surgical resection. When surgical excision is subtotal, recurrence rates have been reported as high as 70% (1–4, 14). Radiation therapy has been used in such cases (1). Recent reports have indicated that there may be a place for adjuvant medical therapy with antiestrogens, nonsteroid antiinflammatory drugs, warfarin, vitamin K₁, and testolactone, either alone or in combination (9–12).

Conclusion

Aggressive fibromatosis is a locally infiltrative lesion that can involve the neck. It is more common in female subjects. Remote trauma, surgery, and hormonal stimulation might be involved in its development and growth. As in this case, radiologic studies, including MR imaging, can fail to suggest local invasion. Surgery remains the treatment of choice. Radiation therapy, and possibly medical therapy, could be of benefit.

References

1. Masson JK, Soule EH. Desmoid tumors of the head and neck. *Am J Surg* 1966;112:615–622
2. Wilkins SA, Waldron CA, Mathews WH, Droulias CA. Aggressive fibromatosis of the head and neck. *Am J Surg* 1975;130:412–415
3. Chui M. Fibromatosis of the brachial plexus and shoulder girdle. *J Can Assoc Radiol* 1989;40:28–31
4. Conley J, Healey WV, Stout AP. Fibromatosis of the head and neck. *Am J Surg* 1966;112:609–614
5. Siemssen SJ, Anagnostaki T. Aggressive fibromatosis (extra-abdominal desmoids) of the head and neck. *Br J Plast Surg* 1984;37:453–457
6. Ben-Izhak O, Kuten A, Pery M, Quitt M, Guilbord J, Weyl-Ben-Arush M. Fibromatosis (desmoid tumor) following radiation therapy for Hodgkin's disease. *Arch Pathol Lab Med* 1994;118:815–818
7. Batsakis JG, Raslan W. Extra-abdominal desmoid fibromatosis. *Ann Otol Rhinol Laryngol* 1994;103:331–334
8. Plaat BE, Balm AJ, Loftus BM, Gregor RT, Hilgers FJ, Keus RB. Fibromatosis of the head and neck. *Clin Otolaryngol* 1995;20:103–108
9. Alman BA, Naber SP, Terek RM, Jiranek WA, Goldberg MJ, Wolfe HJ. Platelet-derived growth factor in fibrous musculoskeletal disorders: a study of pathologic tissue sections and in vitro primary cell cultures. *J Orthop Res* 1995;13:67–77
10. Tonelli F, Valanzano R, Brandi ML. Pharmacologic treatment of desmoid tumors in familial adenomatous polyposis: results of an in vitro study. *Surgery* 1994;115:473–479
11. Alman BA, Goldberg MJ, Naber SP, Galanopoulos T, Antoniadis HN, Wolfe HJ. Aggressive fibromatosis. *J Pediatr Orthop* 1992;12:1–10
12. Waddell WR, Kirsch WM. Testolactone, sulindac, warfarin, and vitamin K₁ for unresectable desmoid tumors. *Am J Surg* 1991;161:416–421
13. Kransdorf MJ. Benign soft-tissue tumors in a large referral population: distribution of specific diagnoses by age, sex, and location. *AJR Am J Roentgenol* 1995;164:395–402
14. Greager JA, Patel MK, Briele HA, Walker MJ, Das Gupta TK. Soft tissue sarcomas of the adult head and neck. *Cancer* 1985;56:820–824