

Generic Contrast Agents

Our portfolio is growing to serve you better. Now you have a *choice*.



[VIEW CATALOG](#)

AJNR

MR imaging, MR angiography, and MR spectroscopy of the brain in eclampsia.

A R Sengar, R K Gupta, A K Dhanuka, R Roy and K Das

AJNR Am J Neuroradiol 1997, 18 (8) 1485-1490

<http://www.ajnr.org/content/18/8/1485>

This information is current as
of May 28, 2025.

MR Imaging, MR Angiography, and MR Spectroscopy of the Brain in Eclampsia

Anju R. Sengar, Rakesh K. Gupta, Arun K. Dhanuka, R. Roy, and K. Das

PURPOSE: To compare the MR imaging and MR angiographic changes with in vivo proton MR spectroscopic findings and to determine the spectral differences between edema and ischemia in patients with eclampsia. **METHODS:** Spin-echo MR imaging, MR angiography, and single-voxel proton MR spectroscopy were performed in 10 patients with eclampsia. MR studies were obtained within 3 to 5 days of diagnosis and repeated after 2 weeks with identical parameters. **RESULTS:** Multifocal subcortical/cortical hyperintensities were noted in all 10 patients on T2-weighted images; in two patients, hyperintensities were seen in both cerebral hemispheres. In nine patients, MR angiograms showed narrowing of the major vessels constituting the circle of Willis that resolved after 2 weeks. In one patient with subtle imaging changes, MR angiography showed mild bilateral narrowing of the proximal middle and posterior cerebral arteries that did not change after 2 weeks, whereas imaging abnormalities worsened. Findings at single-voxel MR spectroscopy of the reversible T2 hyperintense lesions were significantly different from findings in the control group for *N*-acetylaspartate (NAA)/creatine ratios. One patient with mild abnormalities at MR imaging and MR angiography had lactate and decreased creatine and NAA, and on a follow-up study had a further decrease of NAA and creatine as well as a decrease in lactate. **CONCLUSION:** In vivo proton MR spectroscopy may help to differentiate cerebral edema from ischemia in patients with eclampsia and thus may help to determine the prognosis for these patients.

Index terms: Brain, magnetic resonance; Magnetic resonance, spectroscopy; Magnetic resonance angiography

AJNR Am J Neuroradiol 18:1485–1490, September 1997

The neuropathogenesis of preeclampsia/eclampsia is poorly understood. Multiple factors have been implicated, including cerebral vasospasm, hemorrhage, ischemia, edema, and hypertensive and metabolic encephalopathy (1–3). One of the many hypotheses proposed is that an acute elevation in mean arterial pressure exceeds the capillary resistance, resulting in cerebral edema (4, 5). Magnetic resonance (MR) imaging has been useful in demonstrating tran-

sient bilateral parietooccipital high signal intensities involving the cortex and subcortical white matter (6–12). Contrast-enhanced angiography and MR angiography have demonstrated reversible vasospasm of the medium and large intracranial vessels (8, 13–16). In vivo proton MR spectroscopy has been used in the examination of a wide variety of intracranial lesions (17). Characteristic spectral changes in acute cerebral ischemia have been reported in human and animal studies (18, 19). The present study was performed to compare the MR imaging and MR angiographic changes with in vivo proton MR spectroscopic findings and to determine spectral differences between edema and ischemia in patients with eclampsia.

Materials and Methods

Ten women, 17 to 21 years old, who fulfilled the clinical criteria of the American Society of Obstetrics and Gyne-

Received November 26, 1996; accepted after revision March 11, 1997.

From the Department of Obstetrics and Gynecology, KG Medical College (A.R.S., K.D.), the Departments of Radiology (R.K.G.) and Neurology (A.K.D.), Sanjay Gandhi Post-Graduate Institute of Medical Sciences, and the Regional Sophisticated Instrumentation Center (R.R.), Lucknow, India.

Address reprint requests to Rakesh K. Gupta, MD, Department of Radiology, Sanjay Gandhi Post-Graduate Institute of Medical Sciences, Lucknow 226014, India.

AJNR 18:1485–1490, Sep 1997 0195-6108/97/1808–1485

© American Society of Neuroradiology

cology for the diagnosis of eclampsia were included in the study (20). Antepartum eclampsia was seen in six women in the late trimester of pregnancy, two women had intrapartum eclampsia, and two had postpartum eclampsia. Convulsive episodes ranged in number from three to 12. All MR studies were performed within 3 to 5 days of the diagnosis of eclampsia, and all patients were treated conservatively. Nine patients had no focal neurologic deficits, and one patient was in a coma. All patients were mildly hypertensive at the time of the first study; nine were clinically normal at the time a repeat examination was performed after 2 weeks. None of the patients complained of visual problems, but no detailed neuroophthalmologic examination was performed. One patient worsened while being treated conservatively.

MR studies were performed on a 1.5-T superconducting system with a circularly polarized head coil. The brain MR imaging protocol included axial spin-echo T1-weighted images (550/14/3 [repetition time/echo time/excitations]) and proton density- and T2-weighted images (2200/20,80) with a 192×256 matrix, 5-mm-thick sections, and a 0.5-mm intersection space. MR angiograms were obtained with a three-dimensional time-of-flight magnetization transfer prepared sequence. MR venograms were obtained in all patients after intravenous injection of contrast material. Single-voxel proton MR spectroscopy was performed with a spin-echo sequence (3000/135/128). A voxel of $2 \times 2 \times 2$ cm³ was selected and placed on the hyperintense lesion visible on T2-weighted images in the right frontal lobe ($n = 4$) and the parietal lobe ($n = 6$) on the first and subsequent studies. The location of the voxel was ensured with the help of anatomic landmarks. Repeat MR imaging and spectroscopy were performed with identical parameters as used in the first study. The images were analyzed for the location of hyperintense signal and narrowing of vessels. Spectral postprocessing was done with zero-filling (4K data points), gaussian multiplication, Fourier transformation, constant phase correction, and real part extraction. No baseline correction was done. The peak heights of *N*-acetylaspartate (NAA) at 2.02 ppm, choline-containing compounds (Cho) at 3.22 ppm, and creatine (Cr) at 3.02 ppm were measured, and NAA/Cho, NAA/Cr, and Cho/Cr ratios were calculated. Spectral evaluation was done independently by two of the investigators. The assignment of resonances was based on the existing literature (17). These ratios were compared with follow-up studies and with those in 10 healthy age- and sex-matched control subjects to ascertain significant differences. Sedation was given in appropriate doses when required.

Results were expressed as mean \pm standard deviation. One-way analysis of variance was used for between-group comparisons.

Results

A summary of the clinical, MR imaging, and MR spectroscopic findings appears in the Table.

All patients had involvement of the occipital

and parietal lobes. The frontal lobes were involved in seven patients, the temporal lobes in two, the basal ganglia in two, and the cerebellum in one. Imaging abnormalities reversed completely when the study was repeated after 2 weeks in nine patients, who also made a complete clinical recovery. MR angiograms in these patients showed narrowing of vessels of the circle of Willis (Fig 1) in the first study. On follow-up examination after 2 weeks, the MR angiographic findings were normal in six patients while residual spasm persisted in three. However, all three of these patients made a complete clinical recovery. Repeat examination in these patients was not possible, as they were lost to follow-up. Findings on MR venograms were normal in all cases. In vivo proton MR spectroscopy showed NAA/Cho, NAA/Cr, and Cho/Cr ratios to be 1.985 ± 0.06 , 1.841 ± 0.03 , and 0.947 ± 0.03 , respectively, in the first study; after 2 weeks, the ratios were 1.986 ± 0.05 , 1.850 ± 0.04 , and 0.969 ± 0.07 , respectively. In the age- and sex-matched control subjects, NAA/Cho, NAA/Cr, and Cho/Cr ratios from the corresponding normal regions were 2.110 ± 0.10 , 1.900 ± 0.02 , and 0.896 ± 0.06 , respectively. In the initial study, NAA/Cho and NAA/Cr ratios were significantly less than those for the healthy control subjects ($P = .02$, $P = .004$, respectively). The same findings persisted on follow-up studies. NAA/Cho and NAA/Cr ratios were significantly lower ($P = .02$, $P = .028$) than those in the control subjects, suggesting persistence of spectral changes on repeat studies. There was no significant difference in Cho/Cr ratios among the three groups (Fig 1).

One patient had an increase in T2 hyperintensities after 2 weeks as compared with the first study, along with dilatation of the lateral ventricles. An MR angiogram in this patient showed narrowing of both middle cerebral and posterior cerebral arteries, which persisted after 2 weeks. Initial MR spectroscopy of the right frontal lobe showed a decrease in NAA and Cr, with the presence of lactate at 1.33 ppm; at follow-up, NAA and Cr showed further decrease, with a decrease in lactate as well. Cho did not exhibit any change relative to the first study.

Discussion

Cranial MR imaging in women with eclampsia reveals characteristic multifocal curvilinear ab-

Clinical and MR findings in 10 patients with eclampsia

Patient	Age, y	Diagnosis	Interval between Symptom Onset and MR Study, d	Neurologic Status		MR Imaging (T2 Hyperintensity)		MR Angiography		Proton MR Spectroscopy			Clinical Outcome
				1st Study	2nd Study	1st Study	2nd Study	1st Study	2nd Study	Voxel Region	1st Study	2nd Study	
1	17	APE	3	Confused	Normal	F, P, O, subcortical basal ganglia	Normal	Narrow CW, narrow BA	Marked recovery	R F	↓ NAA	No change	CR
2	19	APE	3	Confused, Normal irritable	Normal	F, P, O, T, cortical/subcortical basal ganglia	Normal	Generalized narrow CW	Nearly normal	R F	↓ NAA	No change	CR
3	21	APE (Fig 1)	4	Confused	Normal	F, P, O, T, subcortical, cortical	Normal	Nonvisible CW	Residual changes	R F	↓ NAA	No change	CR
4	18	IPE	5	Confused	Normal	F, P, O, T, subcortical, cortical	Normal	Narrow CW	Normal	R P	↓ NAA	No change	CR
5	17	APE	4	Confused	Normal	F, P, O, subcortical	Normal	Narrow CW	Normal	R P	↓ NAA	No change	CR
6	17	IPE	5	Irritable	Normal	O, P, subcortical	Normal	Narrow CW	Normal	R P	↓ NAA	No change	CR
7	19	APE	5	Confused	Normal	F, P, O, cerebellar, subcortical	Normal	CW, BA	Normal	R P	↓ NAA	No change	CR
8	18	PPE	5	Confused	Normal	P, O, subcortical	Normal	Narrow CW	Normal	R P	↓ NAA	No change	CR
9	20	PPE	4	Coma	Deep coma	Cortical, subcortical, F, P, O, subtle changes	Lesions more prominent	Proximal PCA, MCA, spastic	No change	R F	↓ ↓ NAA, ↓ ↓ Cr, Lac++	↓ ↓ NAA, ↓ ↓ Cr, Lac+	Died
10	18.5	APE	5	Confused	Normal	O, P, subcortical	Normal	Narrow CW	Normal	R P	↓ NAA	No change	CR

Note.—APE indicates antepartum eclampsia; IPE, intrapartum eclampsia; PPE, postpartum eclampsia; NAA, *N*-acetylaspartate; Cr, creatine; Cho, choline; Lac, lactate; F, frontal; P, parietal; O, occipital; T, temporal; PCA, posterior cerebral artery; MCA, middle cerebral artery; BA, basilar artery; CW, circle of Willis; ↓, depletion; ↓ ↓, moderate depletion; CR, complete recovery; and ↓ ↓ ↓, marked depletion.

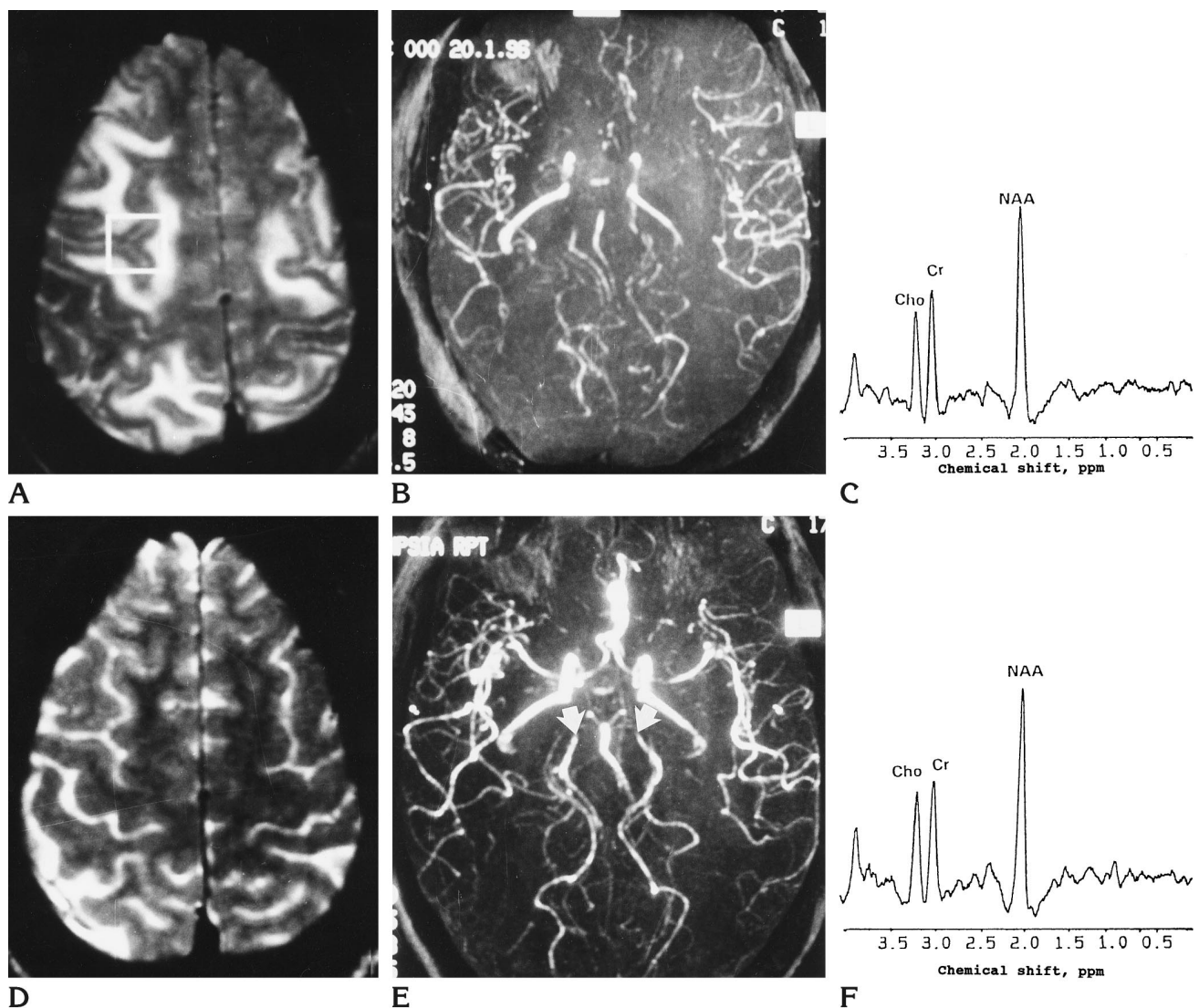


Fig 1. Reversible T2 hyperintensities in eclampsia.

A, Axial T2-weighted image (2200/80/1) through the preventricular level shows cortical and subcortical hyperintensities in the frontal and occipital lobes.

B, MR angiogram shows nonvisibility of the proximal anterior cerebral, middle cerebral, posterior cerebral arteries. The carotid arteries and basilar artery are narrowed.

C, Proton spectrum obtained with spin-echo imaging at 135 milliseconds in the right frontal region (inset in A) shows significantly lower NAA/Cho and NAA/Cr ratios than the same region in healthy control subjects.

D, After 2 weeks, repeat T2-weighted MR image (2200/80/1) in the same region of the brain as in A shows complete resolution of the lesions.

E, MR angiogram shows marked resolution of the narrowing relative to that in B, with most vessels in the circle of Willis visible. Minimal narrowing of both proximal posterior cerebral arteries persists (arrows).

F, Repeat spectrum from the same region shows no significant change in NAA/Cho and NAA/Cr ratios as compared with C.

normalities at the gray-white matter junctions (6–12). The MR imaging findings have also been confirmed on gross pathologic specimens (21). These findings are considered to be characteristic of preeclamptic-eclamptic/hypertensive encephalopathy (21). The lesions appear hyperintense on T2-weighted images and hypointense on T1-weighted images, and in some

cases small areas of hemorrhage may also be visible (6–12). These lesions are usually reversible (6–12). In our study, the distribution of abnormalities was similar to that described in previous studies. The changes were reversible, with no atrophy after 2 weeks in nine patients; one patient had more prominent lesions along with atrophy on the follow-up study. We did not

observe hemorrhage. Although these imaging features have been described as characteristic of eclampsia, similar reversible abnormalities have been described in patients treated with cyclosporine and other immunosuppressants, and are collectively termed *reversible posterior leukoencephalopathy syndrome* (22).

Conventional angiographic findings in patients with preeclampsia-eclampsia include reversible cerebral segmental arterial narrowing of large and medium vessels (8, 13, 14). These changes are thought to be due to intimal hyperplasia and reversible vasospasm (13, 14). Recently, MR angiography in preeclampsia/eclampsia has shown reversible vasospasm of the arteries of the circle of Willis and extending peripherally (15, 16). We observed diffuse narrowing of the circle of Willis in nine patients that returned to normal on follow-up studies in the majority of cases. Reversibility of MR angiographic changes was associated with reversibility of imaging abnormalities. It has been shown experimentally that sudden elevation of the mean arterial pressure exceeds the autoregulatory capability of brain vasculature and results in its failure (5). Regions of vasodilatation and vasoconstriction develop, especially at the arterial boundary zone, and there is a breakdown of the blood-brain barrier with focal transudation of fluid and petechial hemorrhage (1, 5). Levels of plasma endothelin, which is a potent vasoconstrictive peptide, have been reported to be increased in patients with preeclampsia (23). In our one patient with irreversible imaging changes and poor clinical outcome, MR angiography showed bilateral spasm of the proximal middle cerebral and posterior cerebral arteries, which persisted on the follow-up study.

In patients with acute cerebral ischemia, in vivo proton MR spectroscopy shows an increase in lactate less than 24 hours after the onset of stroke, even when no conventional MR imaging abnormalities are detectable (18, 19). In patients with T2 hyperintensities, highly depleted NAA along with the presence of lactate and variable Cho levels suggests infarction (19). In the present study, there was a significant decrease in NAA in nine patients with reversible imaging changes, which persisted even after 2 weeks relative to levels in healthy age- and sex-matched control subjects. The absence of any detectable lactate and the reversibility of the imaging changes in these nine patients exclude infarction as a possible cause of the T2 hyper-

intensities. Persistence of low NAA even after complete reversibility of imaging abnormalities suggests some neuronal loss, although probably not enough to cause cerebral atrophy. In one patient, the presence of lactate along with a decrease in NAA and Cr in the first study, when imaging abnormalities were subtle, suggested the presence of infarction. The repeat study after 2 weeks showed abnormal imaging findings along with further depletion of NAA and poor clinical outcome, confirming the presence of infarction. The marked decline in NAA in this patient correlated well with the development of cerebral atrophy, which probably resulted from gross neuronal damage.

We believe that cerebral vasospasm plays an important role in the development of cerebral edema (seen as increased T2 signal intensity in the parietooccipital regions) in patients with eclampsia. Differentiation of cerebral edema from ischemia with in vivo proton MR spectroscopy is possible and may help to predict the outcome of patients with eclampsia.

References

1. Friedman SA, Taylor RM, Roberts JM. Pathophysiology of pre-eclampsia. *Clin Perinatol* 1991;18:661-682
2. Kaplan PW, Repka JT. Eclampsia. *Neurol Clin North Am* 1994;12:565-582
3. Cunningham FC, MacDonald RC, Grant NF. Hypertensive disorders in pregnancy. In: *Williams' Obstetrics*. 18th ed. Norwalk, Conn: Appleton and Lange; 1989:653-690
4. Byrom FB. The pathogenesis of hypertensive encephalopathy and its relation to the malignant phase of hypertension: experimental evidence from the hypertensive rat. *Lancet* 1954;2:201-211
5. Dinsdale HB, Robertson DM, Hass RA. Cerebral blood flow in acute hypertension. *Arch Neurol* 1974;31:80-87
6. Raroque HG Jr, Orrison WW, Rosenberg GA. Neurological involvement in toxemia of pregnancy: reversible MRI lesions *Neurology* 1990;40:167-169
7. Sanders TG, Clayman DA, Sanchez-Ramos L, Vines FL, Russo L. Brain in eclampsia: MR imaging with clinical correlation. *Radiology* 1991;180:475-478
8. Rape EC, Galetta SL, Broderick M, Atlas SW. Delayed peripartum vasculopathy: cerebral eclampsia revisited. *Ann Neurol* 1993;33:222-225
9. Digre KB, Varner MW, Osborn AG, Crawford S. Cranial magnetic resonance imaging in severe preeclampsia vs eclampsia. *Arch Neurol* 1993;50:399-406
10. Cunningham FG, Fernandez CO, Hernandez C. Blindness associated with preeclampsia and eclampsia. *Am J Obstet Gynecol* 1995;172:1291-1298
11. Schwartz RB, Jones KM, Kalina P, et al. Hypertensive encephalopathy: findings on CT, MR imaging, and SPECT imaging in 14 cases. *AJR Am J Roentgenol* 1992;159:379-383
12. Brick JF. Vanishing cerebrovascular disease of pregnancy. *Neurology* 1988;38:804-806

13. Trommer BL, Homer D, Mikhael MA. Cerebral vasospasm and eclampsia. *Stroke* 1988;19:326-329
14. Call GK, Fleming MC, Sealfon S, et al. Reversible cerebral segmental vasoconstriction. *Stroke* 1988;19:1159-1170
15. Kanayama N, Nakajima A, Maehara K, et al. Magnetic resonance imaging angiography in a case of eclampsia. *Gynecol Obstet Invest* 1993;36:56-58
16. Ito T, Sakai T, Inagawa S, Utsu M, Bun T. MR angiography of cerebral vasospasm in preeclampsia. *AJNR Am J Neuroradiol* 1995;16:1344-1346
17. Castillo M, Kwok L, Mukherji SK. Clinical application of proton MR spectroscopy. *AJNR Am J Neuroradiol* 1996;17:1-15
18. Combs DJ, Dempsey RJ, Maley M, Donaldson D, Smith C. Relationship between plasma glucose, brain lactate and intracellular pH during cerebral ischemia in gerbils. *Stroke* 1990;21:936-942
19. Gillard JH, Barker PB, van Zijl PCM, Bryan RN, Oppenheimer SM. Proton MR spectroscopy in acute middle cerebral artery stroke. *AJNR Am J Neuroradiol* 1996;17:873-886
20. American College of Obstetricians and Gynecologists. *Management of Preeclampsia. Technical Bulletin No. 91.* February 1986
21. Sheehan HL, Lynch JB. *Pathology of Toxemia of Pregnancy.* New York, NY: Churchill Livingstone; 1973
22. Hinghey J, Chaves C, Appignani B, et al. A reversible posterior leukoencephalopathy syndrome. *N Engl J Med* 1996;334:494-500
23. Mastrogiannis DS, O'Brien WF, Krammer J, Benoit R. Potential role of endothelin-1 in normal and hypertensive pregnancies. *Am J Obstet Gynecol* 1991;165:1711-1716