

# Generic Contrast Agents

Our portfolio is growing to serve you better. Now you have a *choice*.



[VIEW CATALOG](#)

# AJNR

## **Dural arteriovenous fistulas of the marginal sinus.**

C G McDougall, V V Halbach, C F Dowd, R T Higashida, D W Larsen and G B Hieshima

*AJNR Am J Neuroradiol* 1997, 18 (8) 1565-1572

<http://www.ajnr.org/content/18/8/1565>

This information is current as of May 24, 2025.

# Dural Arteriovenous Fistulas of the Marginal Sinus

Cameron G. McDougall, Van V. Halbach, Christopher F. Dowd, Randall T. Higashida, Donald W. Larsen, and Grant B. Hieshima

**PURPOSE:** To investigate the clinical presentation, angiographic findings, endovascular management, and clinical outcome in dural arteriovenous fistulas (DAVFs) of the marginal sinus. **METHODS:** Fourteen patients with DAVFs of the marginal sinus were identified from angiographic studies and medical records of all patients treated for DAVFs at our institution between July 1990 and August 1995. The endovascular treatment and clinical outcomes of these patients are reported. **RESULTS:** Eleven patients had pulse-synchronous bruit, two had intracranial hemorrhage, and one had ataxia. Thirteen patients were cured with endovascular techniques alone and one was cured by a combination of preoperative embolization followed by surgical obliteration of the fistula. The sole complication of treatment was a partial left hypoglossal nerve palsy, which resolved spontaneously. **CONCLUSION:** DAVFs of the marginal sinuses are potentially life-threatening lesions that can be treated with endovascular techniques for a high rate of cure and a low rate of morbidity.

**Index terms:** Fistula, arteriovenous; Interventional neuroradiology

*AJNR Am J Neuroradiol* 18:1565–1572, September 1997

Dural arteriovenous fistulas (DAVFs) are abnormal arteriovenous connections located within the dura mater. They are usually associated with or drain into a specific dural sinus or involve an adjacent cortical vein. DAVFs are classified according to either the name of the dural sinus with which they are associated or the anatomic location at which the abnormal arteriovenous connection exists (1–15). While most DAVFs have a benign course, they can result in life-threatening hemorrhage (16–19) and debilitating venous hypertension (20–25). The clinical presentation, management strategy, and clinical outcome depend on the location of the DAVF.

The marginal sinus is located between the layers of the dura at the rim of the foramen magnum (Fig 1). This sinus encircles the foramen magnum, communicating with the basal venous plexus of the clivus anteriorly and with

the occipital sinus posteriorly. It normally drains to the sigmoid sinus or jugular bulb by a series of small sinuses (26). During embryonic development, the marginal sinus is more prominent and contributes more to the extracranial venous drainage of the posterior fossa. Anastomotic connections to the internal vertebral venous plexus as well as to paravertebral and/or deep cervical veins are typically present (27).

In recent years, endovascular techniques have been proved effective in treating many DAVFs (3, 7, 9–11, 28–31). It has been observed that although DAVFs at different locations might be similar pathophysiologically, the clinical presentation and management principles may vary. During the past 10 years, over 290 DAVFs have been treated at our institution, and since 1990, 14 patients with fistulas involving the marginal sinus have been treated. The purpose of this review is to describe the specific features associated with DAVFs at this location and to discuss the endovascular treatment and outcome of the patients treated for this lesion.

## Materials and Methods

Patients' files from the interventional neuroradiology service at our institution were reviewed to identify all pa-

---

Received October 31, 1995; accepted after revision March 6, 1997.

From the Department of Radiology, University of California, San Francisco, Medical Center.

Address reprint requests to Cameron G. McDougall, Neurosurgical Associates, Barrow Neurological Institute, 2910 N 3rd Ave, Phoenix, AZ 85013.

AJNR 18:1565–1572, Sep 1997 0195-6108/97/1808–1565

© American Society of Neuroradiology

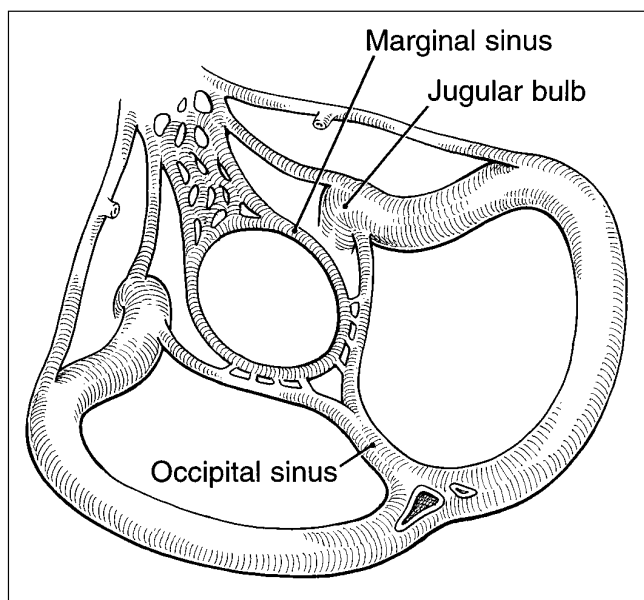


Fig 1. Schematic diagram of the venous anatomy of the posterior fossa (as seen from above) shows the marginal sinus and related dural venous sinuses.

tients treated for DAVFs of the marginal sinus between July 1990 and August 1995. All angiographic studies were reviewed as were the medical records. All available patients were contacted by the primary author for follow-up. Office records were relied upon for follow-up in three patients who could not be contacted directly.

Fourteen patients, consisting of seven men and seven women, 35 to 76 years old (mean, 54.5 years; median, 55 years), were identified as having DAVFs of the marginal sinus. All patients underwent endovascular treatment. Before transfer to our institution, three patients had undergone unsuccessful treatment for these lesions by transarterial endovascular therapy, craniotomy, and combined endovascular therapy and craniotomy, respectively. The identifying clinical symptom in 11 patients was pulse-synchronous bruit. All the patients with bruit found the symptom disabling owing to sleep disturbance, hearing loss, or concentration difficulties. One of these 11 patients also had diplopia, chemosis, and proptosis due to retrograde venous drainage up the inferior petrosal sinus. Similarly, a second patient had chemosis but without proptosis or diplopia. Of the three patients who did not have bruit, one had subarachnoid hemorrhage, one had intracerebellar hemorrhage, and one had tremor and ataxia that had persisted for over 1 year. The latter patient, apart from those patients presenting with orbital venous hypertension or hemorrhage, was the only one with objective neurologic findings attributable to the fistula. The bruit was heard objectively in all patients who reported it, and it had typically been present for months to years before treatment. This time period reflects delays in initial presentation as well as delays in diagnosis. Mean time from onset of symptoms to initial treatment was 14 months (median, 9 months).

Three patients had a history of head trauma, two with mild concussion only and one with a basal skull fracture. In this latter patient, the onset of symptoms began shortly after the injury, and at the time of angiography two dural fistulas were identified, the second involving the contralateral transverse sinus.

Lesions were classified into three grades depending on the pattern of venous drainage: grade 1 involved drainage to the ipsilateral jugular bulb without obvious obstruction; grade 2 consisted of absent or restricted drainage to the jugular bulb; and grade 3 indicated retrograde cortical drainage with or without additional venous drainage. Restriction was considered present when the majority of the anterograde venous drainage was to collateral vertebral, paravertebral, or cervical veins or when retrograde venous drainage to the ipsilateral inferior petrosal sinus was present. In grade 2 fistulas, retrograde cortical venous drainage was absent.

Venous drainage was unrestricted to the region of the jugular bulb (grade 1) in six of 14 cases, all of whom presented with bruit alone. Venous outflow restriction (grade 2) was present in five of 14 patients, three of whom had no drainage to the adjacent jugular bulb. All five of these patients also reported bruit, but two had signs of elevated orbital venous pressure in addition. Exclusively retrograde cortical venous drainage was present in the three remaining cases. Two of these patients had severe intracranial hemorrhage and the third patient (case 14) had ataxia and marked signal changes on MR images of the brain stem and upper cervical spinal cord. Table 1 shows the venous drainage pattern of the fistulas as related to the pattern of clinical presentation.

#### Representative Cases

**Case 10.**—A 50-year-old man without significant medical history had sudden onset of a left-sided pulse-synchronous bruit, which worsened to the point of causing significant hearing and sleep disturbances. A loud bruit could be heard over the left mastoid. Physical examination was otherwise within normal limits. Initial radiologic studies, including computed tomography (CT) and magnetic resonance (MR) imaging, were unremarkable. Angiography revealed arteriovenous shunting at the marginal sinus with venous drainage to the jugular bulb (grade 1) (Fig 2A). The site of the fistula was accessed from a transfemoral venous approach (Fig 2B), and the fistula was cured by the transvenous placement of fibered platinum coils at the

TABLE 1: Clinical presentation of 14 patients based on the pattern of fistulous venous drainage

Venous Drainage Pattern	Bruit Only	Bruit Plus Chemosis	Hemorrhage or Neurologic Deficits
Grade 1 (unrestricted)	6	0	0
Grade 2 (restricted)	3	2	0
Grade 3 (retrograde cortical)	0	0	3

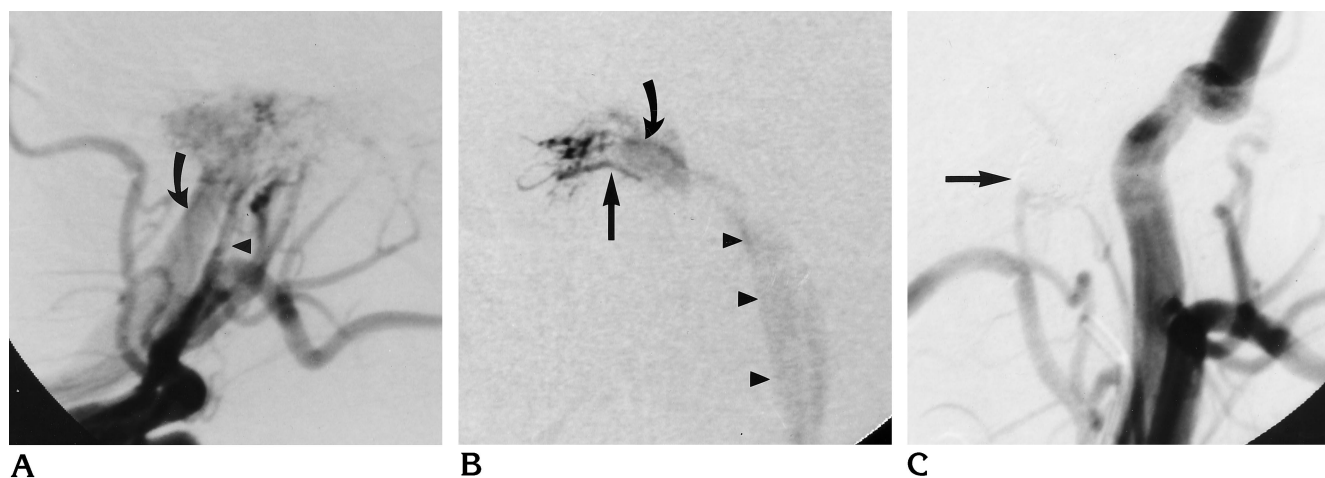


Fig 2. Case 10: 50-year-old man with sudden onset of a left-sided pulse-synchronous bruit.

A, Left external carotid arteriogram, lateral view, shows arteriovenous shunting at the level of the foramen magnum. Principal arterial supply is via the ascending pharyngeal artery (*arrowhead*) and the venous drainage is to the internal jugular vein (*arrow*).

B, Towne's view of the skull after placement of transvenous and transarterial catheters at the fistula site. Injection through the transvenous microcatheter shows retrograde filling of arteriovenous channels (*straight arrow*) and fistulous pouch (*curved arrow*), and drainage to the internal jugular vein (*arrowheads*).

C, Left common carotid arteriogram, lateral view, after transvenous coil embolization, shows no residual arteriovenous shunting. Coils are barely visible as subtraction artifacts (*arrow*).

fistula site (Fig 2C). The patient's symptoms resolved immediately, and he remains asymptomatic after 8 months of follow-up.

**Case 2.**—A 68-year-old man had a right-sided pulsatile bruit of 5 years' duration. Although he had found the bruit distressing, intervention was not pursued until he experienced a new onset of diplopia. His medical history was remarkable only for hypertension. Examination revealed an audible bruit on the right; in addition, proptosis, chemosis, and restricted extraocular movements were noted on the right. Visual acuity was not impaired. Angiographic findings showed arteriovenous shunting at the marginal sinus. The primary venous drainage was retrograde up the ipsilateral inferior petrosal sinus with no anterograde drainage to the ipsilateral internal jugular vein (grade 2) (Fig 3A). Because of the absence of a direct transvenous route to the fistula site, a microcatheter was navigated up the contralateral inferior petrosal sinus, across the midline through the circular sinus, and then down the ipsilateral inferior petrosal sinus to the fistula site (Fig 3A and B). Placement of fibered platinum coils at this location resulted in obliteration of the fistula (Fig 3C and D). The patient's bruit ceased at the time of treatment and the ocular symptoms resolved within a few days. No symptoms have recurred after more than 4 years of follow-up.

**Case 4.**—A 40-year-old man came to the emergency department of an outside institution with a headache, reporting that he had fallen from a bicycle 1 week earlier. No neurologic findings were noted, and the patient was discharged. Subsequently, he returned with a worsened headache and ataxia. While in the emergency department, the patient's condition deteriorated rapidly and he lost consciousness. A CT study revealed a large posterior fossa

hemorrhage (Fig 4A), which was evacuated emergently. After evacuation of the hematoma and a brief recovery period, angiography showed what appeared to be a posterior fossa aneurysm, and the patient was returned to the operating room. At this second procedure, the lesion was thought to be an arteriovenous malformation, and the surgical exploration was aborted pending further evaluation. At that time, the patient was referred to our institution.

Further angiography revealed the presence of a DAVF at the level of the foramen magnum, with venous drainage in an exclusively retrograde fashion to cortical veins (grade 3) (Fig 4B and C). In the absence of any venous approach to the fistula, we attempted transarterial embolization using liquid adhesives via the ascending pharyngeal artery, which resulted in angiographic cure of the fistula (Fig 4D and E). The patient made an uneventful recovery before being discharged from the hospital; he did not return for long-term follow-up.

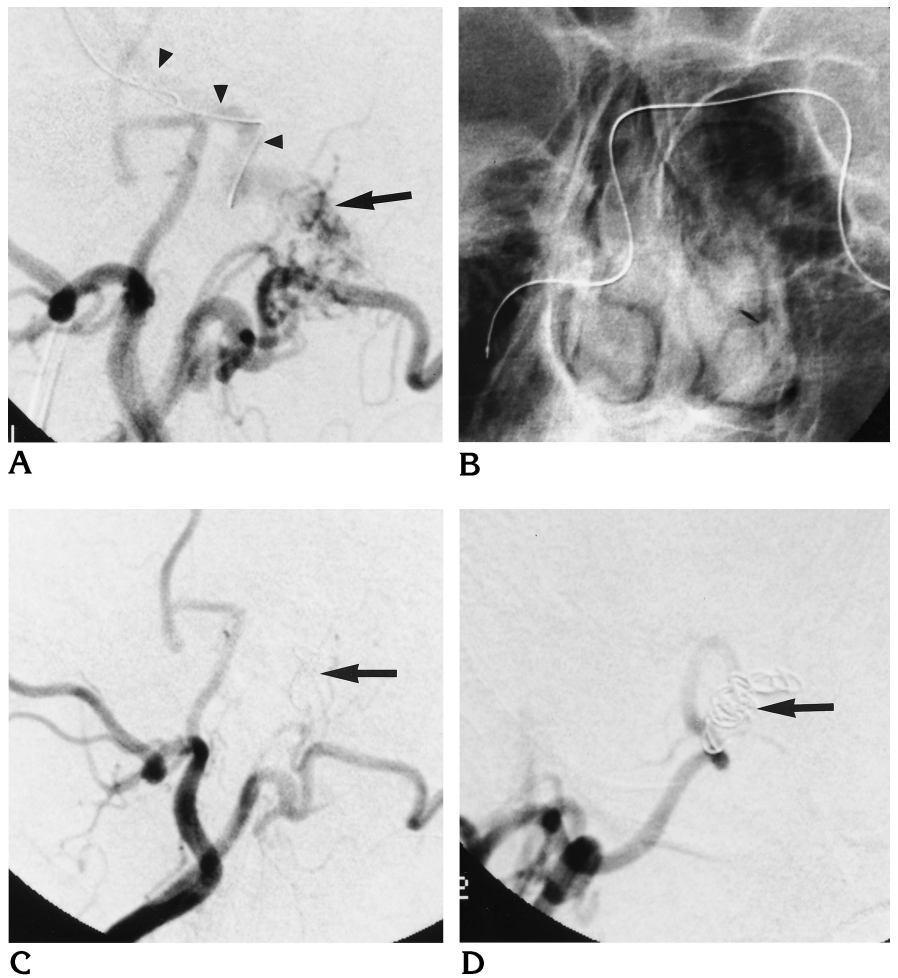
#### Treatment

Treatment was carried out by transvenous coil embolization to the fistula site in all patients with grade 1 and 2 lesions. This transvenous embolization was preceded by transarterial polyvinyl alcohol embolization in five patients and by transarterial ethanol embolization in two patients. The role of transarterial embolization in these grade 1 and 2 lesions was considered adjunctive, with the goal of slowing the flow through the fistula to encourage thrombosis at the time of transvenous embolization of the fistula. In the three patients with grade 3 lesions in whom no transvenous route to the fistula site existed, definitive treatment was by transarterial embolization with liquid adhesives in

Fig 3. Case 2: 68-year-old man with right-sided pulsatile bruit of 5 years' duration.

A and B, Lateral view of right external carotid arteriogram (A) shows arteriovenous shunting (arrow) with arterial supply from the right occipital artery. No venous drainage to the internal jugular vein is apparent, but retrograde venous drainage up the ipsilateral inferior petrosal sinus is seen (arrowheads). Also seen traversing both inferior petrosal sinuses is the transvenously placed microcatheter. This retrograde catheterization up the left inferior petrosal sinus, across the circular sinus, and down the right inferior petrosal sinus is better illustrated on the unsubtracted frontal view (B).

C and D, Postembolization arteriograms of the right external carotid artery in the lateral (C) and frontal (D) planes show no residual shunting. The transvenously placed coils (arrows) are best seen on the frontal view.



two patients and by surgical obliteration after transarterial polyvinyl alcohol embolization in the third patient.

## Results

### Angiographic Findings

The fistula site was on the right in eight cases and on the left in the other six. Usually, the feeding arteries to the fistula site were multiple. Typical arterial supply included the neuromeningeal division of the ascending pharyngeal artery, radicular or muscular collateral branches of the vertebral artery, and transmastoid perforators of the occipital artery. Contribution from the meningohypophyseal trunk via posterior clival dural branches was also frequent. Arterial supply was bilateral in five of the 14 patients. Table 2 summarizes the sites of the fistulas and their respective arterial supplies.

### Outcome and Complications

Clinical follow-up ranged from less than 1 month in the most recently treated patient to over 5 years in the patients seen earlier (mean, 19 months; median, 13 months). Clinical cure of the fistula was achieved in all patients. In one patient, the fistula was slowed but not obliterated angiographically at the time of treatment; however, shortly after treatment, the symptoms resolved completely and the patient remains asymptomatic 17 months after treatment. One patient reported a brief episode of mild recurrent symptoms a few weeks after the initial treatment, but these symptoms resolved with carotid compression and the patient remains asymptomatic after 4 years of follow-up. In the remaining 12 patients, angiographic cure was documented at the time of treatment or at the last angiographic follow-up.

The sole complication of treatment was the delayed development of a partial ipsilateral cra-

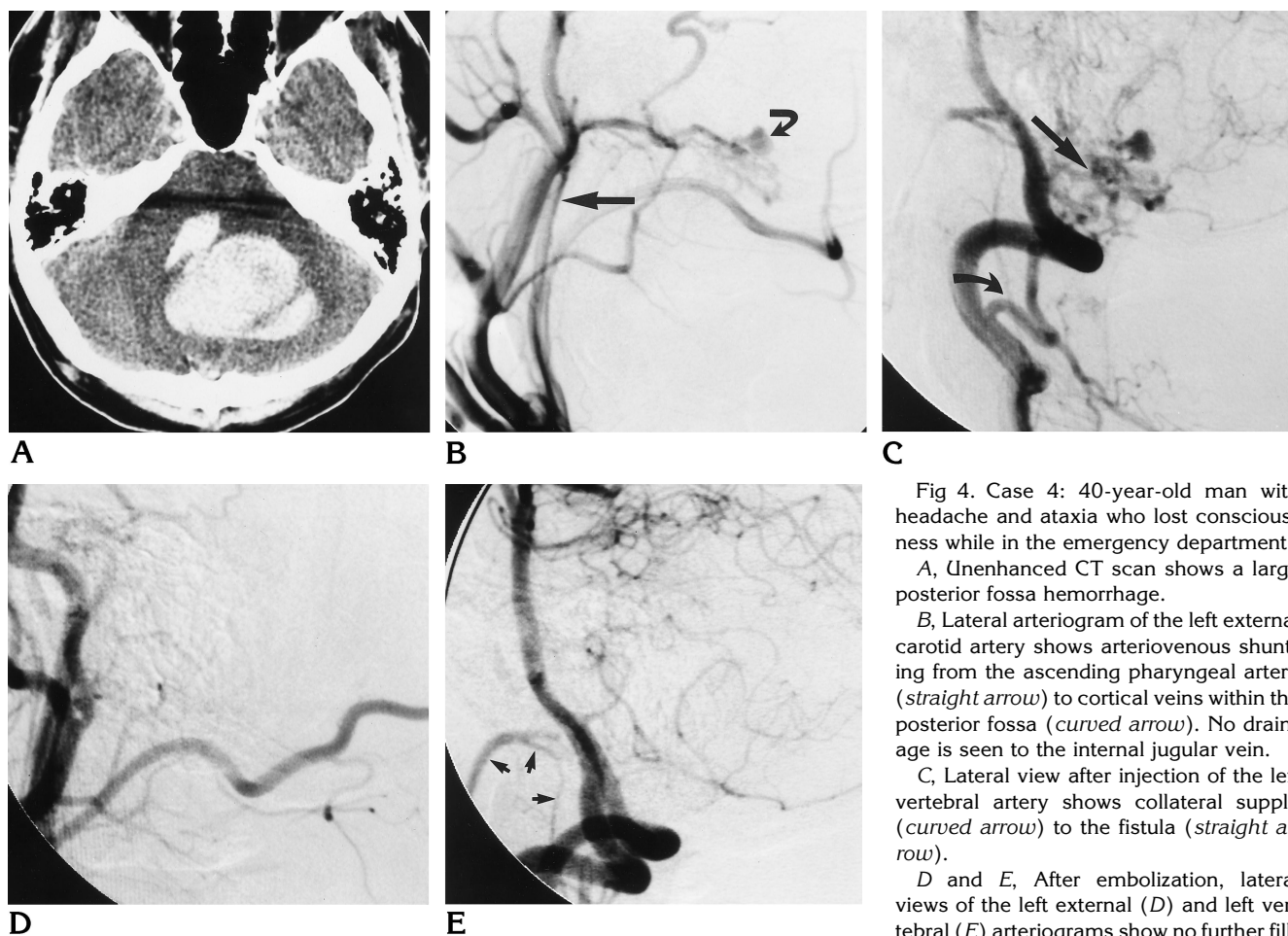


Fig 4. Case 4: 40-year-old man with headache and ataxia who lost consciousness while in the emergency department.

A, Unenhanced CT scan shows a large posterior fossa hemorrhage.

B, Lateral arteriogram of the left external carotid artery shows arteriovenous shunting from the ascending pharyngeal artery (straight arrow) to cortical veins within the posterior fossa (curved arrow). No drainage is seen to the internal jugular vein.

C, Lateral view after injection of the left vertebral artery shows collateral supply (curved arrow) to the fistula (straight arrow).

D and E, After embolization, lateral views of the left external (D) and left vertebral (E) arteriograms show no further fill-

ing of the fistula. The vertebral artery injection also shows collateral retrograde filling of the stump of the embolized ascending pharyngeal artery (arrows, E).

nial nerve XII palsy, which completely resolved after 4 months.

## Discussion

The majority of DAVFs are known to develop in association with an adjacent dural sinus. In this series, the fistulas were located at the margin of the foramen magnum and were not directly associated with the sigmoid sinus or jugular bulb. The sigmoid sinuses and jugular bulbs filled normally and the fistula sites were identified medial to these structures. Given these features, it is likely that these fistulas developed in association with the marginal sinus. Previous scattered references to DAVFs involving the marginal sinus exist (22, 32). More frequently, fistulas in this area are grouped together with posterior fossa DAVFs or described as fistulas of the skull base or foramen magnum region (15, 23, 24, 33-39). Previous authors have sug-

gested that endovascular techniques are not effective in the treatment of fistulas at this location (33). The largest series previously published described 12 posterior fossa DAVFs, six of which were in the region of the foramen magnum (37). In that series, all six of the patients had retrograde cortical venous drainage; four presented with hemorrhage and a fifth with myelopathy caused by venous congestion. Only three were known to be cured, all by direct surgical means; one death occurred after incomplete embolization by a transarterial route, and two patients were not treated. The current series compares favorably in that all fistulas were cured, including those in patients with retrograde cortical venous drainage; moreover, treatment resulted in no permanent morbidity or mortality.

The importance of the venous pattern of drainage in understanding the pathophysiology and risks associated with DAVFs has been em-

TABLE 2: Arterial supply of marginal sinus dural arteriovenous fistulas

Patient	Side of Fistula	Artery						
		Ascending Pharyngeal	Occipital	Vertebral or Posterior Meningeal	Middle Meningeal	Meningohypophyseal Trunk	Posterior Auricular	Accessory Meningeal
1	R	...	R	R	...	B	...	...
2	R	...	R	...	...	...	R	...
3	R	B	...	...	...	R	...	...
4	L	L	...	L	...	...	...	...
5	R	R	R	...	...	...	...	...
6	R	R	...	...	...	R	...	...
7	R	R	...	...	...	R	...	...
8	L	B	L	...	...	B	...	...
9	R	R	R	R	...	...	R	...
10	L	L	...	L	L	L	...	...
11	L	...	L	L	L	B	...	...
12	L	B	...	L	L	...	...	L & B imax
13	R	R	R	R	...	R	...	...
14	L	L	...	L	...	...	...	...

Note.—R indicates right; L, left; B, bilateral; and imax, internal maxillary artery.

phasized previously (16–25, 39–41). The significance of the venous drainage pattern in dictating the management options available is similarly well recognized. This understanding is reflected in the descriptions of transvenous embolization previously described for fistulas at other locations (3, 11, 31) and in the direct surgical treatment of intracranial DAVFs by interruption of leptomeningeal venous drainage as reported by Thompson et al (39).

In the present series, hemorrhage occurred in two of three cases in which retrograde cortical venous drainage was present (grade 3) and in no other cases. In the third case with retrograde cortical venous drainage, pronounced neurologic symptoms were present, again a situation not otherwise observed. In two of the five patients with obstruction or restriction of drainage to the jugular bulb (grade 2), venous hypertension in the cavernous sinus resulted in chemosis or other symptoms of orbital venous congestion. All patients with grade 1 lesions had disabling bruit alone. Grade 1 lesions are benign and treatment should not be undertaken if the bruit is not significantly disruptive to the patient. DAVFs can change over time, progressing from low-risk to high-risk lesions. A change in symptoms, such as the loss or reduction in a bruit, may represent worsening rather than improvement in the risk category.

In the current series, all patients who were treated via a transvenous endovascular route were cured. Although transvenous coil embolization emerged as the treatment of choice in this series, this route is difficult or impossible in

the absence of a connection with the jugular bulb. A Water's projection is often helpful in showing the relationship of the fistula to the jugular bulb and the clivus. In our patients with only retrograde cortical venous drainage, the problem of inadequate venous access was overcome by embolization with liquid adhesives from a transarterial approach or by direct surgical obliteration of the fistula. Although the transarterial route is generally considered less effective, cure was effected in both patients with grade 3 lesions who were treated with transarterial liquid adhesives. Liquid adhesives had been used unsuccessfully via a transarterial approach at an outside institution in one of the patients with a grade 1 lesion; however, cure was subsequently effected via a transvenous approach. Because of the inability to embolize the exact site of the fistula and all its feeding artery pedicles, transarterial treatment with polyvinyl alcohol is unlikely to result in permanent cure. Transarterial embolization with polyvinyl alcohol can, however, be useful in reducing the rate of flow through a fistula before attempting definitive treatment.

In the setting of a grade 3 fistula, the decision to treat by transarterial embolization versus direct surgical obliteration should be made on an individual basis. Important considerations in making this decision include the clinical condition of the patient, the surgical accessibility of the fistula, and the suitability of the angiographic anatomy for transarterial embolization, especially the number and configuration of the

feeding arteries. Most of these fistulas are supplied by the ascending pharyngeal artery, and great care must be taken in embolizing this artery to avoid occlusion of the arterial supply to the lower cranial nerves or embolization through anastomotic connections to the vertebral artery and spinal cord. A fistula located along the posterior rim of the foramen magnum is readily accessed surgically, and the single case in this series treated surgically at our institution resulted in cure of the fistula. In contrast, two other patients in this series had undergone unsuccessful surgical explorations at other institutions before definitive cure was achieved by endovascular means.

In conclusion, DAVFs of the marginal sinus are rare. Presentation depends on the pattern of venous drainage, and life-threatening hemorrhage can occur when retrograde cortical venous drainage is present. Contrary to previous reports, endovascular treatment is safe and highly effective.

## References

- Albright AL, Latchaw RE, Price RA. Posterior dural arteriovenous malformations in infancy. *Neurosurgery* 1983;13:129-135
- Aminoff MJ. Vascular anomalies in the intracranial dura mater. *Brain* 1973;96:601-612
- Barnwell SL, Halbach VV, Dowd CF, Higashida RT, Hieshima GB. Dural fistulas involving the inferior petrosal sinus. *AJNR Am J Neuroradiol* 1990;11:511-517
- Barrow DL, Spector RH, Braun IF, Landman JA, Tindall SC, Tindall GT. Classification and treatment of carotid-cavernous sinus fistulas. *J Neurosurg* 1985;62:248-256
- Chaudhary M, Sachdev VP, Cho SH, Weitzner I Jr, Puljic S, Huang YP. Dural arteriovenous malformation of the major venous sinuses: an acquired lesion. *AJNR Am J Neuroradiol* 1982;3:13-19
- Dion J. Dural Arteriovenous malformations: definition, classification and diagnostic imaging. In: Awad IA, Barrow DL, eds. *Dural Arteriovenous Malformations*. Park Ridge, Ill: American Association of Neurological Surgeons Publications Committee; 1993:1-21
- Halbach VV, Higashida RT, Hieshima GB, Reicher M, Norman D, Newton TH. Dural fistulas involving the cavernous sinus: results of treatment in 30 patients. *Radiology* 1987;163:437-442
- Halbach VV, Higashida RT, Hieshima GB, Wilson CW, Barnwell SL, Dowd CF. Dural arteriovenous fistulas supplied by ethmoidal arteries. *Neurosurgery* 1990;25:816-823
- Halbach VV, Higashida RT, Hieshima GB, Goto K, Norman D, Newton TH. Dural fistulas involving the transverse and sigmoid sinuses: results of treatment in 28 patients. *Radiology* 1987;163:443-447
- Halbach VV, Higashida RT, Hieshima GB, Cahan L, Rosenblum M. Treatment of dural arterial venous malformations involving the superior sagittal sinus. *AJNR Am J Neuroradiol* 1988;9:337-343
- Halbach VV, Higashida RT, Hieshima GB, Mehringer CM, Hardin CW. Transvenous embolization of dural fistulas involving the transverse and sigmoid sinuses. *AJNR Am J Neuroradiol* 1989;10:385-392
- Halbach VV, Higashida RT, Hieshima GB, Wilson CW. Treatment of dural fistulas involving the deep cerebral venous system. *AJNR Am J Neuroradiol* 1989;10:393-399
- Kobayashi H, Hayashi M, Noguchi Y, Tsuji T, Handa Y, Caner HH. Dural arteriovenous malformations in the anterior cranial fossa. *Surg Neurol* 1988;30:396-401
- Martin NA, King WA, Wilson CB, Nutik S, Carter LP, Spetzler RF. Management of dural arteriovenous malformations of the anterior cranial fossa. *J Neurosurg* 1990;72:692-697
- Newton TH, Weidner W, Greitz T. Dural arteriovenous malformation in the posterior fossa. *Radiology* 1968;90:27-35
- Awad IA, Little JR, Akrawi, Ahl J. Intracranial dural arteriovenous malformations: factors predisposing to an aggressive neurological course. *J Neurosurg* 1990;72:839-850
- Brown RD, Wiebers DO, Nichols DA. Intracranial dural arteriovenous fistulae: angiographic predictors of intracranial hemorrhage and clinical outcome in nonsurgical patients. *J Neurosurg* 1994;81:531-538
- Lalwani AK, Dowd CF, Halbach VV. Grading venous restrictive disease to predict the clinical presentation and guide therapy in patients with dural arteriovenous fistulas of the transverse sigmoid sinus. *J Neurosurg* 1993;79:11-15
- Malik GM, Pearce JE, Ausmann JI. Dural arteriovenous malformations and intracranial hemorrhage. *Neurosurgery* 1984;15:332-339
- Halbach VV, Hieshima GB, Higashida RT, Reicher M. Carotid cavernous fistula: indications for urgent therapy. *AJNR Am J Neuroradiol* 1987;8:627-633
- Hurst RH, Hackney DB, Goldberg HI, Davis RA. Reversible arteriovenous malformation-induced venous hypertension as a cause of neurological deficits. *Neurosurgery* 1992;30:422-425
- Lasjaunias P, Chiu M, TerBrugge K, Tolia A, Hurth M, Bernstein M. Neurological manifestations of intracranial dural arteriovenous malformations. *J Neurosurg* 1986;64:724-730
- Vinuela F, Fox AJ, Pelz DM, Drake CG. Unusual clinical manifestations of dural arteriovenous malformations. *J Neurosurg* 1986;64:554-558
- Willinsky R, TerBrugge K, Lasjaunias P, Montanera W. The variable presentations of craniocervical and cervical dural arteriovenous malformations. *Surg Neurol* 1990;34:118-123
- Wrobel CJ, Oldfield EH, DiChiro G, Tarlov EC, Baker RA, Doppman JL. Myelopathy due to intracranial dural arteriovenous fistulas draining intrathecally into spinal medullary veins: report of three cases. *J Neurosurg* 1988;69:934-939
- de Oliveira E, Rhoton AL, Peace D. Microsurgical anatomy of the region of the foramen magnum. *Surg Neurol* 1985;24:293-352
- Okudera T, Huang YP, Ohta T, et al. Development of posterior fossa dural sinuses, emissary veins and jugular bulb: morphological and radiological study. *AJNR Am J Neuroradiol* 1994;15:1871-1883
- Barnwell SL, Halbach VV, Higashida RT, Hieshima GB, Wilson CB. Complex dural arteriovenous fistulas: results of a new combined neurosurgical and interventional neuroradiology treatment in 16 patients. *J Neurosurg* 1989;71:352-358
- Barnwell SL, Halbach VV, Dowd CF, Higashida RT, Hieshima GB, Wilson CB. A variant of arteriovenous fistulas within the wall of dural sinuses. *J Neurosurg* 1991;24:199-204
- Djindjian R, Cophignon J, Theron J. Embolization by superselective arteriography from the femoral route; review of 60 cases: technique, indications, complications. *Neuroradiology* 1973;6:20-26
- Halbach VV, Higashida RT, Hieshima GB, Hardin CW, Pribram H. Transvenous embolization of dural fistulas involving the cavernous sinus. *AJNR Am J Neuroradiol* 1989;10:377-384



32. Lasjaunias PL, Rodesch G. Lesion types, hemodynamics and clinical spectrum. In: Awad IA, Barrow DL, eds. *Dural Arteriovenous Malformations*. Park Ridge, Ill: American Association of Neurological Surgeons Publications Committee; 1993:49–80
33. Awad IA. Tentorial incisura and brain stem dural arteriovenous malformations. In: Awad IA, Barrow DL, eds. *Dural Arteriovenous Malformations*. Park Ridge, Ill: American Association of Neurological Surgeons Publications Committee; 1993:131–146
34. Barnwell S. Endovascular therapy of dural arteriovenous malformations. In: Awad IA, Barrow DL, eds. *Dural Arteriovenous Malformations*. Park Ridge, Ill: American Association of Neurological Surgeons Publications Committee; 1993:193–212
35. Gaensler EH, Jackson DE, Halbach VV. Arteriovenous fistulas of the cervicomedullary junction as a cause of myelopathy: radiographic findings in two cases. *AJNR Am J Neuroradiol* 1990;11:518–521
36. Kuwayama N, Akai T, Horie Y, Nishijima M, Endo S, Takaku A. Dural arteriovenous fistulae involving the transverse-sigmoid sinus and foramen magnum. *Surg Neurol* 1994;41:389–395
37. Pierot L, Chiras J, Mender JF, Rose M, Rivierez M, Marsault C. Dural arteriovenous fistulas of the posterior fossa draining into subarachnoid veins. *AJNR Am J Neuroradiol* 1992;13:315–323
38. Rodesch G, Comoy J, Hurth M, Lasjaunias P. Jugular foramen arteriovenous shunt with subarachnoid hemorrhage. *Skull Base Surg* 1991;1:132–136
39. Thompson BG, Doppman JL, Oldfield EH. Treatment of cranial dural arteriovenous fistulae by interruption of leptomeningeal venous drainage. *J Neurosurg* 1994;80:617–623
40. Djindjian R, Merland JJ. *Super-selective Arteriography of the External Carotid Artery*. New York, NY: Springer-Verlag; 1978
41. Gaston A, Chiras J, Bourbotte G, Leger JM, Guibert-Tranier F, Merland JJ. Meningeal arteriovenous fistulae draining into cortical veins: 31 cases. *J Neuroradiol* 1984;11:161–177