

Generic Contrast Agents

Our portfolio is growing to serve you better. Now you have a *choice*.



FRESENIUS
KABI

[VIEW CATALOG](#)

AJNR

MR in cisternal hydatid cysts.

J Tsitouridis, A S Dimitriadis and E Kazana

AJNR Am J Neuroradiol 1997, 18 (8) 1586-1587

<http://www.ajnr.org/content/18/8/1586>

This information is current as
of May 20, 2025.

MR in Cisternal Hydatid Cysts

John Tsitouridis, Athanasios S. Dimitriadis, and Elpida Kazana

Summary: We describe a case of multiple hydatid cysts in the cerebral subarachnoid space. The diagnosis was based on clinical findings, latex test results, cerebrospinal fluid examination, and MR imaging findings.

Index terms: Subarachnoid space, cysts; Brain, magnetic resonance

Cerebral hydatid disease is rare, and it usually occurs in children. We report a case of multiple hydatid cysts in the cerebral cisterns.

Case Report

A 58-year-old man reported having headaches for several years that had worsened in the 3 months preceding examination. He had no history of recent trauma, vomiting, or seizures.

Magnetic resonance (MR) imaging revealed multiple small multiloculated lesions in the interhemispheric fissure, sylvian fissures, and suprasellar, ambiens, and quadrigeminal cisterns. The lesions had high signal intensity on T2-weighted images (Fig 1A) and low signal intensity on T1-weighted images, and were slightly hyperintense with respect to cerebrospinal fluid (CSF) on balanced images (Fig 1B). After contrast administration, the walls of the lesions enhanced mildly (Fig 1C).

CSF examination revealed hooks of scolices. Casoni and latex tests were positive for *Echinococcus granulosus*. At imaging, no cysts were found in the liver or lungs, and the patient had no communicating hydrocephalus.

Discussion

Intracranial granulosus echinococcosis is uncommon. Only about 2% of cases of hydatid disease involve the brain, even in endemic areas (1). The most common sites of involvement are the cerebral parenchyma (especially the parietal lobes) and the subarachnoid spaces after secondary involvement (2, 3).

Cysts are usually single and unilocular and may be large. Rarely, the cysts may be mul-

tilocular or multiple. Cysts in the subarachnoid space are commonly found in the spinal canal as a complication of ruptured cysts involving the spinal column; they are less likely to be the result of rupture and dissemination of intracranial cysts (4–6). In the cerebral cisterns, the most likely pathway of dissemination is hematogenous spread to the meninges and rupture into the subarachnoid space.

MR imaging findings of intracranial hydatid cysts have been described (7). The fluid of the hydatid cyst and the pericyst, which is a peripheral capsule of the cyst, are the two components that may be visible by imaging. A secondary process involving the cyst, such as calcification, infection, rupture of entodermic membrane, or perifocal edema, may also be identified.

MR imaging is believed to be more sensitive and reliable than computed tomography (CT) in depicting the pericyst layer, which appears as a halo, or in showing perilesional edema (2). CT is, however, more sensitive and accurate than MR imaging in detecting hydatid cyst calcifications (2, 8).

Our patient had multiple small cysts close together in the cerebral subarachnoid space. On contrast-enhanced T1-weighted MR images, we clearly identified the pericyst capsules. CT scans showed neither calcification in the cysts nor hydatid disease elsewhere in the body.

In formulating a differential diagnosis, the most difficult lesions to distinguish from hydatid cyst are arachnoid cyst and epidermoid tumor (9, 10). Epidermoids usually have slightly hyperintense signal intensity on proton density-weighted MR images and they usually engulf nerves and vessels, whereas arachnoid and hydatid cysts displace adjacent structures. Rameuse cysticercosis in the subarachnoid space also should be considered in the differential diagnosis (11). These cysts may then become

Received July 17, 1996; accepted after revision November 11.

From the Department of Radiology, AHEPA University Hospital 1 Kyriakidis Str, 54636 Thessaloniki, Greece. Address reprint requests to John Tsitouridis, MD.

AJNR 18:1586–1587, Sep 1997 0195-6108/97/1808–1586 © American Society of Neuroradiology

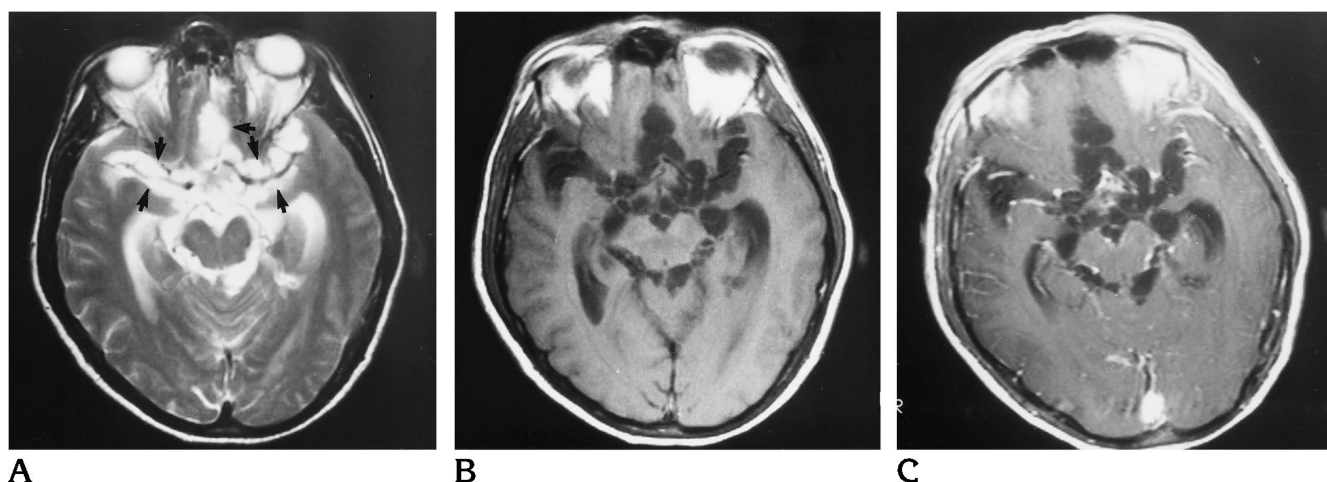


Fig 1. A 58-year-old man with cerebral hydatid disease.

A, Axial T2-weighted image (2500/120/1 [repetition time/echo time/excitations]) shows multiple subarachnoid cysts (arrows) with thin hypointense capsules.

B, Axial T1-weighted image (600/20/1) shows multiple cysts in the subarachnoid space. The signal intensity is higher than that of CSF, and in some of the lesions a capsule is visible.

C, Axial T1-weighted contrast-enhanced image (600/20/1) shows the faint enhancement of pericyst capsules.

multiloculated, simulating a cluster of grapes (12, 13). The presence of hooks in the CSF examination and the positive latex and Casoni tests confirmed the diagnosis of hydatid disease in our patient.

References

1. Rudman MA, Khaffai S. CT of cerebral hydatid disease. *Neuroradiology* 1988;30:496-499
2. Topal U, Parlak M, Kilic E, Sivri Z, Sadikoglu MY, Tuncel E. CT and MRI findings in cerebral hydatid disease. *Eur Radiol* 1995;5: 244-247
3. Karak PK, Mittal M, Bhatia S, Mukhopadhyay S, Berry M. Isolated cerebral hydatid cyst with pathognomonic CT sign. *Neuroradiology* 1992;34:9-19
4. Sharman A, Kashyap V, Abraham J, Kurian S. Intradural hydatid cysts. *Surg Neurol* 1981;16:235-237
5. Akhan O, Dincer A, Saatci I, Gulekon N, Besim A. Spinal intradural hydatid cyst in a child. *Br J Radiol* 1991;64:465-466
6. Rayport M, Wisoff HS, Zaiman H. Vertebral echinococcosis. *J Neurosurg* 1964;21:647-659
7. Pumar J, Alveraz M, Leira R, et al. Multiple intracranial hydatid cysts: MR findings. *Eur Radiol* 1992;2:385-387
8. Ogut AG, Kanberoglu K, Altug A, Cokyuksek O. CT and MRI in hydatid disease of cervical vertebral. *Neuroradiology* 1992;34: 430-432
9. Quint DJ. Retroclival arachnoid cyst. *AJNR Am J Neuroradiol* 1992;13:1503-1504
10. Tien RD, Macfall J, Heinz ER. Evaluation of complex cystic masses of the brain: value of steady-state free precession MR imaging. *AJR Am J Roentgenol* 1992;159:1049-1055
11. Byrd S, Locke G, Biggers G, Peroy A. The computed tomographic appearance of cerebral cysticercosis in adults and children. *Radiology* 1982;144:819-823
12. Davis LE, Korufeld M. Neurocysticercosis: neurologic, pathogenic, diagnostic and therapeutic aspects. *Eur Neurol* 1991;31: 229-240
13. Sze G. Infections and inflammatory disease. In: Stark D, Bradley W, eds. *Magnetic Resonance Imaging*. St Louis, Mo: Mosby; 1988: 316-343