

Generic Contrast Agents

Our portfolio is growing to serve you better. Now you have a *choice*.



FRESENIUS
KABI

[VIEW CATALOG](#)

AJNR

Association of posterior fossa dermoid cyst and Klippel-Feil syndrome.

P T Kennedy and D J McAuley

AJNR Am J Neuroradiol 1998, 19 (1) 195

<http://www.ajnr.org/content/19/1/195.citation>

This information is current as
of May 25, 2025.

We approached the question of why these patients have such a high percentage of breech presentation. The fetal contribution to its final position in utero in general is still unclear; congenital muscular dystrophies, hypotonic syndromes, and some severe malformations of the nervous system are associated with breech presentation. Breech presentation is exceedingly high (up to 50%) in Prader Willi syndrome (8); these patients present with diffuse hypotonia that could justify an abnormal presentation but also have a definite hypothalamic dysfunction. An abnormal hypothalamus could not respond properly to hormones that could play a crucial role in timing the correct position of the fetus. Can we suggest that in pituitary dwarfs breech delivery is a consequence, and not a cause, of an hypothalamic-pituitary abnormality?

F. Triulzi
G. Scotti

Department of Neuroradiology
San Raffaele Hospital
University of Milano (Italy)

References

1. Fujisawa I, Kikuchi N, Nishimura K, et al. **Transection of the pituitary stalk: development of an ectopic posterior lobe assessed with MR imaging.** *Radiology* 1987;165:487-489
2. Fujisawa I, Asato R, Nishimura K, et al. **Anterior and posterior lobes of the pituitary gland: assessment by 1.5 T MR imaging.** *J Comput Assist Tomogr* 1987;11:214-220
3. di Natale B, Scotti G, Pellini C, et al. **Empty sella in children with pituitary dwarfism: does it exist?** *Pediatrician* 1987;14:246-252
4. Triulzi F, Scotti G, di Natale B, et al. **Evidence of a congenital midline brain anomaly in pituitary dwarfs: a magnetic resonance imaging study in 101 patients.** *Pediatrics* 1994;93:409-416
5. Couly GF, Le Douarin N. **Mapping on the early primordium in quail-chick chimeras: the prosencephalic neural plate and neural folds: implications for the genesis of cephalic human congenital anomalies.** *Dev Biol* 1987;120:198-214
6. Ikeda H, Suzuki J, Sasano N, Niizuma H. **The development and morphogenesis of the human pituitary gland.** *Anat Embryol* 1988;178:327-336
7. Li S, Crenshaw EB, Rawson EJ, Simmons DM, Swanson LW, Rosenfelds MG. **Dwarf locus mutants lacking three pituitary cell types result from mutations in the POU-domain gene pit-1.** *Nature* 1990;347:528-533
8. Braun FHT, Jones KL, Smith DW. **Breech presentation as an indicator of fetal abnormality.** *J Pediatr* 1975;86:419-421

Association of Posterior Fossa Dermoid Cyst and Klippel-Feil Syndrome

A 40-year-old woman presented to our unit with a 9-month history of occipital headache, exacerbated by coughing. Three weeks before presentation, right-sided facial numbness and paroxysmal weakness of both legs developed, causing her to fall repeatedly, but without loss of consciousness.

On examination, her gait was ataxic and there was upper-limb hyperreflexia. Right-sided sensory deficit of the C-2 and trigeminal dermatomes was shown. There was absence of the right corneal reflex and impairment of the right gag reflex.

Plain radiographs showed the typical Klippel-Feil fusion of cervical vertebrae (Fig 3A). T1-weighted coronal MR images showed a high-signal mass extending from the brain stem up to the tentorium cerebelli (Fig 3B). Sagittal T2-weighted images showed that the same mass had medium signal, with focal areas of low signal in keeping with calcification.

The classic triad of short neck, low posterior hairline, and limitation of neck movement is seen in approximately 52% of

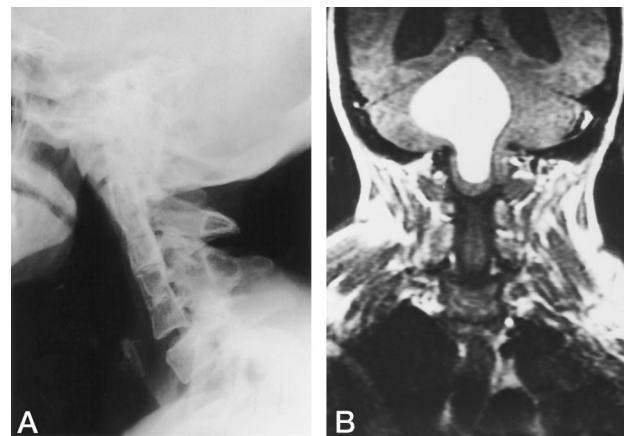


FIG 3. A, Lateral cervical spine radiograph shows the fusion of cervical vertebrae, pituitary fossa erosion secondary to chronically raised intracranial pressure, and calcification projected over the posterior fossa.

B, Coronal T1-weighted MR image (300/16 [repetition time/echo time]) shows the high-signal mass extending from brain stem to tentorium cerebelli, associated with dilatation of the lateral ventricles.

patients with the Klippel-Feil abnormality (1). The syndrome is associated with a range of abnormalities affecting other organ systems, including the central nervous system. Documented associations include diastematomyelia, syringomyelia, and agenesis of the corpus callosum (2), and we are aware of other reports (2-4) of associated posterior fossa dermoid cyst. One of these cases presented with meningism after rupture of the dermoid cyst (2).

Failure of formation and rearrangement of the segmental cervical sclerotomes leads to the Klippel-Feil abnormality. A related, adjacent failure of cleavage of epithelial ectoderm from neuroectoderm may explain an associated dermoid cyst. If a posterior fossa mass is seen on MR or computed tomography in patients with Klippel-Feil syndrome, dermoid cyst should be considered.

P. T. Kennedy
Department of Neuroradiology

D. J. McAuley
Department of Neurosurgery

Royal Victoria Hospital
Belfast, Northern Ireland

References

1. Hensinger RN, Lang JE, MacEwen GD. **Klippel-Feil syndrome: a constellation of associated anomalies.** *J Bone Joint Surg [Am]* 1974;56:1246-1253
2. Diekmann-Guiroy B, Huang PS. **Klippel-Feil syndrome in association with a craniocervical dermoid cyst presenting as aseptic meningitis in an adult: case report (review).** *Neurosurgery* 1989;25:652-655
3. Dickey W, Hawkins SA, Kirkpatrick DH, McKinstry CS, Gray WJ. **Posterior fossa dermoid cysts and the Klippel-Feil syndrome.** *J Neurol Neurosurg Psychiatry* 1991;54:1016-1017
4. Kuribayashi K, Nakasu S, Matsumura K, Matsuda M, Handa J. **Dermoid cyst in the fourth ventricle associated with Klippel-Feil syndrome (Japanese).** *No To Shinkei* 1993;45:747-751

Comment

In their letter, Drs Kennedy and McAuley describes a patient with the Klippel-Feil syndrome (KFS) and a posterior fossa dermoid. When they researched the literature, they found similar reports. Is it possible to explain the simultaneous occurrence of both anomalies from an embryologic basis? Are posterior fossa dermoids and KFS truly associated or are the cases reported purely coincidental?

The neural tube closes during the same time period when the somites (which will eventually form the vertebrae) are developing. The neural tube closure begins during the 22nd day of life and the anterior neuropore closes at approximately 28 days of life. Entrapment of dermal elements and their appendages within the closing neural tube may occur at this stage and has been traditionally thought responsible for the development of dermoids and epidermoids. The first somites are seen about the 20th day of life, and by 30 days of life, 28 somites are seen. The somites are paired units of paraspinal mesoderm whose ventral aspect differentiates into the sclerotomes, which will give origin to the vertebrae. Under influence from the notochord, the somites first form the cellular perichordal sheath. This perichordal sheath will become segmented into loose areas (which will form the vertebral bodies) and dense areas, which will serve as the anlagen for the disks.

In animal models, sclerotomes patterning, development of the cellular perichordal sheath, and the development of the intervertebral disks are controlled by specific encoding proteins, which are regulated by phylogenetically highly conserved DNA sequences in certain genes (1). These genes are termed "homeobox" (or *Hox* genes) and "paired box" (or *Pax* genes). Signals from the developing notochord regulate the expressivity of these genes. In the early phase of development, reduced expressivity of the *Pax* genes leads to segmental agenesis of the cellular perichordal sheath and to the absence of one or more vertebral bodies. If the reduced expressivity of the *Pax* genes occurs later during chondrification of the vertebral centra, segmentation does not transpire normally and vertebral body fusions arise. This phenomenon may explain the vertebral anomalies in patients with KFS. In other words, a coincidental association of fused vertebrae and intradural dermoids is possible.

How can one relate both anomalies from an embryologic viewpoint? An important aspect of neural tube dynamics is the formation of the cephalic and cervical brain flexures. The cervical flexure is first seen around the 28th day of life (2). At 35 days of life, the rhombencephalon begins to divide into the metencephalon and the myelencephalon. Between these two

structures, the fourth ventricle is formed. If there is a shortening of the cervical spine secondary to a reduction in the number of somites or from fusion of the somites, we speculate that altered tissue tension at the cervicomedullary junction could occur. This may result in entrapment of dermal elements and give origin to a posterior fossa dermoid with or without a communication that extends from the mass to the skin. This mechanical hypothesis may explain the presence of dermoids in the fourth ventricle or posterior to it in patients with KFS.

However, in several of the cases reported, the dermoids have been located anterior to the brain stem. In these cases, it is possible to invoke an anomaly of neural crest cell migration. In the cephalic portion of the embryo, most cranial tissues are of neural crest cell origin (3). In addition, the pia mater and arachnoid are also neural crest derived. The basisphenoid synchondrosis is a developmentally unstable site that separates the structures derived from neural crest cells (cephalad to this synchondrosis) and those derived from mesenchyme (caudad to this synchondrosis). It is also conceivable that abnormal neural crest cell migration at the level of the basisphenoid synchondrosis may cause these pluripotential cells to form intradural masses such as dermoids or epidermoids. This mechanism could explain the presence of these masses adjacent to the clivus.

In conclusion, several hypotheses can be used to explain the occurrence of posterior fossa dermoids in patients with KFS. The presence of a fatty-appearing mass within the posterior fossa on computed tomography or MR imaging in a patient with KFS should immediately suggest the possibility of a dermoid. Furthermore, patients with KFS who present with repetitive, chronic, or chemical meningitis should undergo imaging in search of a dermoid.

Mauricio Castillo

James H. Scatliff

University of North Carolina School of Medicine
Chapel Hill

References

1. Chalepakos G, Tremblay P, Gruss P. **Pax genes, mutants and molecular function.** *J Cell Sci Suppl* 1992;16:61-67
2. Arey LB. **Developmental Anatomy.** 7th ed. Philadelphia, Pa: WB Saunders; 1974:97-98
3. Sulik KK. **Craniofacial development.** In: Turvey TA, Vig KWL, Fonseca RJ, eds. *Facial Clefts and Craniosynostosis: Principles and Management.* Philadelphia, Pa: WB Saunders; 1996:3-28

Abstracts on the Web

American Journal of Psychiatry
www.appi.org/ajp/ajptoc.html

Annals of Internal Medicine
www.acponline.org/journals/annals/annaltoc.htm

Annals of Otolaryngology, Rhinology, and Laryngology
www.annals.com/

Journal of Neurosurgery
www.neurosurgery.org/journals/jneuro/summary.html

Laryngoscope
www.laryngoscope.com/

Neurosurgery
www.neurosurgery.org/journals/neurosurg/summary.html

Ophthalmology
www.eyenet.org/ophthalmology/

Otolaryngology—Head and Neck Surgery
www.mosby.com/Mosby/Periodicals/Medical/OHNS/hn.html

Psychiatry
www.priory.com/psych.htm

Stroke
www.at-home.com/get_doc/1819166/2116

Pediatrics
www.pediatrics.org/

Journal of Neuroscience
www.jneurosci.org/