

Generic Contrast Agents

Our portfolio is growing to serve you better. Now you have a *choice*.



[VIEW CATALOG](#)

AJNR

Association between size of the lateral ventricle and asymmetry of the fornix in patients with temporal lobe epilepsy.

A C Mamourian, C H Cho, A J Saykin and N L Poppito

AJNR Am J Neuroradiol 1998, 19 (1) 9-13

<http://www.ajnr.org/content/19/1/9>

This information is current as of May 27, 2025.

Association between Size of the Lateral Ventricle and Asymmetry of the Fornix in Patients with Temporal Lobe Epilepsy

Alexander C. Mamourian, Charles H. Cho, Andrew J. Saykin, and Natalie L. Poppito

PURPOSE: Our goal was to determine whether the size of the lateral ventricle influences asymmetry of the fornix in patients with mesial temporal sclerosis.

METHODS: The cross-sectional area of the lateral ventricle was measured along with the thickness of the fornix in 18 patients with pathologically proved mesial temporal sclerosis. Two additional patients with ventricular asymmetry and seizures but without mesial sclerosis were also studied.

RESULTS: Ten of 18 patients with mesial temporal sclerosis had equally sized ventricular areas or less than a 25% difference between the two sides. In seven of these 10, the left and right fornices were equal; in the other three patients, the fornix was thinner on the side of mesial sclerosis. Among the eight patients with ventricular area differences greater than 25%, the larger ventricle was on the side of mesial sclerosis in five cases. In all of these, the ipsilateral fornix was thinner. In three of eight cases, the contralateral ventricle was larger; in two, the left and right fornix were equal; and in one, the fornix contralateral to the side of mesial sclerosis was smaller. The greatest difference in fornix thickness was noted in patients with ventricular asymmetry greater than 40%, regardless of side or presence of mesial temporal sclerosis.

CONCLUSION: The size of the lateral ventricle may influence the apparent thickness of the fornix.

While the medial temporal lobe structures of patients with intractable epilepsy have been the subject of intense scrutiny, it is only recently that attention has turned to other limbic structures. Specifically, a smaller mamillary body and fornix have been reported ipsilateral to a diseased hippocampus in patients with mesial temporal sclerosis (1–3). The prevalence reported by Baldwin et al (1) (less than 90%) was surprising in light of the low prevalence of mamillary body asymmetry evident on imaging studies. We wondered whether the fornix may appear thinner for reasons other than atrophy. We found it was often difficult to compare the thickness of the left and right fornices because of marked variation in the morphology of the two sides, apparently as a result of ventricular asymmetry. We also noted that in all three illus-

trations in the article by Baldwin et al (1) the ventricle was larger on the side of the smaller fornix. We wondered if the fornix appears thinner whenever the adjacent ventricle is larger, and we therefore examined the magnetic resonance (MR) imaging studies of patients with documented mesial temporal sclerosis to test this hypothesis.

Methods

We examined the preoperative MR examinations of 18 patients with intractable epilepsy, all of whom went on to have surgical resection of the hippocampus for mesial temporal sclerosis. The patients were selected from a series of consecutive surgical cases and included only those for whom high-quality coronal images and pathologic confirmation of mesial temporal sclerosis were available.

The side of surgery was determined on the basis of clinical history, inpatient monitoring, MR findings, and scalp electroencephalography (EEG) in all 18 cases. In seven patients, depth electrodes and/or subdural grids were also used to localize the seizure focus. The preoperative MR examinations were interpreted as abnormal and consistent with mesial temporal sclerosis in 17 of the 18 patients. Angiography with Wada testing was performed in all patients preoperatively. Either an anterior temporal resection, including medial temporal structures, or en bloc amygdalo-hippocampectomy was performed at surgery. All resected tissue was sent for pathologic examination for gross and microscopic analysis.

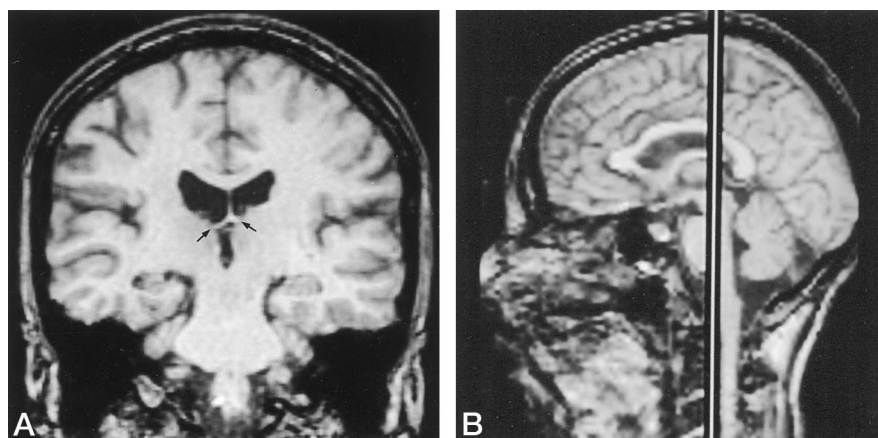
Received August 8, 1996; accepted after revision July 25, 1997.
Presented in part at the annual meeting of the American Society of Neuroradiology, Seattle, Wash, June 1996.

From the Departments of Radiology (A.C.M., C.H.C.), Psychiatry (A.J.S.), and Pathology (N.L.P.), Dartmouth-Hitchcock Medical Center, Lebanon, NH.

Address reprint requests to Alexander C. Mamourian, MD, Department of Radiology, Dartmouth-Hitchcock Medical Center, 1 Medical Center Dr, Lebanon, NH 03755.

FIG 1. A, Coronal 1.5-mm section from a spoiled gradient-echo sequence (38/11/1 [repetition time/echo time/echo excitations], flip angle, 45°) at the level of the rostral crura (arrows).

B, Sagittal image shows the location of the coronal section.



Measurements of ventricular area and fornix in 20 subjects

Case	Side of Mesial Temporal Sclerosis	Size of Ventricular Area		Thickness of Fornix		% Difference	
		R	L	R	L	Ventricle	Fornix
1*	...	190	340	5.0	2.2	44	127
2*	...	358	112	4.4	7.2	219	63
3	L	181	403	4.5	2.2	122	99
4	R	206	350	5.0	2.2	69	127
5	L	661	1023	6.4	3.1	54	106
6	R	145	191	3.6	3.6	31	...
7	R	462	302	3.6	5.0	52	38
8†	R	1037	818	4.2	5.6	26	33
9	R	365	481	2.2	2.2	31	...
10	L	168	233	5.0	2.8	38	78
11	R	793	792	3.6	4.2	...	17
12	R	155	144	2.8	3.6	7	28
13	L	115	129	3.6	3.6	12	...
14	L	416	468	5.0	5.0	12	...
15	L	300	302	7.2	5.6	...	28
16	L	187	230	2.8	2.8	22	...
17	R	609	679	5.0	5.0	11	...
18	L	343	364	2.8	2.8	6	...
19	R	85	106	2.2	2.2	24	...
20	L	97	119	2.2	2.2	22	...

* Patients with seizures but without mesial temporal sclerosis.

† This patient died during the course of the study.

Measurements were obtained from coronal T1- or T2-weighted thin-section images. Section thickness varied from 1.5 to 4 mm. The section selected for measurement was the image of the rostral crura immediately posterior to the body of the fornix (Fig 1). This was the same level used by Kim et al (3) in their study and similar to the site in the study by Balwin et al (1) except they used an angled coronal image. These coronal images were digitized and a cross-sectional area of the left and right ventricles was analyzed on a dedicated image analysis program (Alice, Hayden Image Processing Group, Boulder, Colo). This program uses an automated segmentation tool that draws the ventricular margin. Operator intervention was required only infrequently to optimally match the ventricular contour. The fornix was magnified electronically, and the thickness of each crura of the fornix was measured by using electronic calipers with the same program. During the course of this study, one of the subjects (case 8) died suddenly at home, 1 year after uneventful temporal lobe resection. An autopsy was obtained and the results are included, since they illustrate the significant features of limbic atrophy.

Measurements were obtained in two additional patients who did not have mesial temporal sclerosis but did have a focal lesion, seizures, and obvious ventricular asymmetry.

Results

The Table presents the measurements obtained in the 18 patients with mesial temporal sclerosis and in the two with ventricular asymmetry only. Among the 18 patients with mesial sclerosis in whom electronic measurements were obtained, 10 had equally sized ventricular areas or less than a 25% difference between the two sides (cases 11 through 20). The fornix was smaller on the side of mesial sclerosis in three of the 10. The ventricles were equal in area in two of these cases and showed a 7% difference in the other case (Fig 2). The difference in size of the fornix ranged from 17% to 28%.

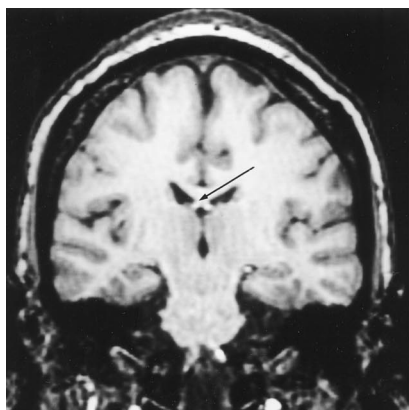


FIG 2. A coronal section from the spoiled gradient-echo volume revealed symmetric lateral ventricles and a thinner right fornix (arrow) in a patient with right-sided mesial temporal sclerosis.

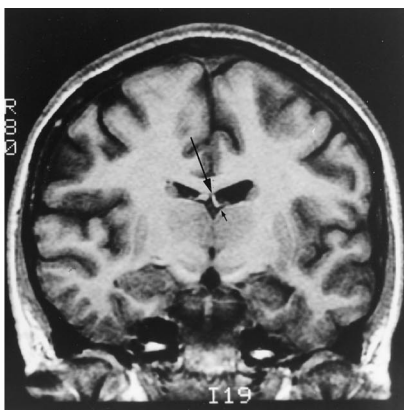


FIG 3. Coronal 3-mm section from a spoiled gradient-echo (25/5) (flip angle, 45°) examination shows marked asymmetry of the ventricle and fornix (arrows) in this patient with left-sided mesial temporal sclerosis.

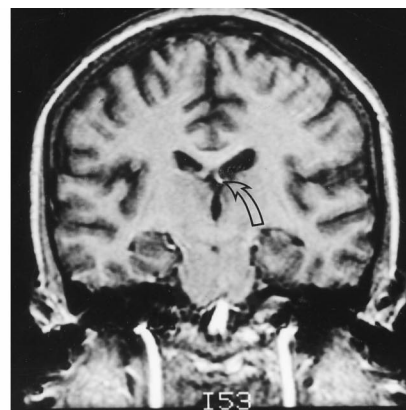


FIG 4. Coronal T1-weighted spoiled gradient-echo sequence (45/5/2) (flip angle, 45°) shows a larger left ventricle and thinner left fornix (arrow) in a patient with right-sided mesial temporal sclerosis.

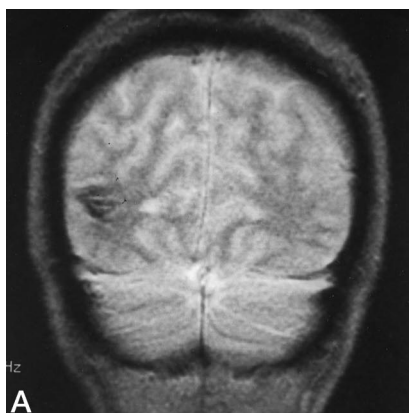
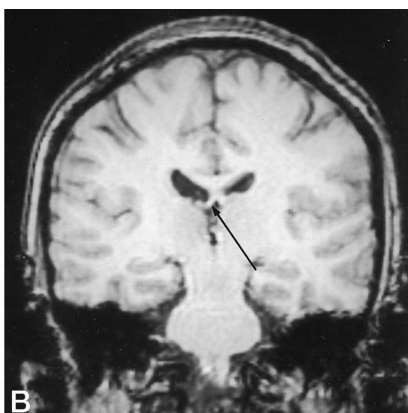


FIG 5. A, Coronal gradient-echo sequence (450/10/1) (flip angle, 10°) shows a susceptibility artifact in the right occipital region in this patient with a cavernous angioma and seizures.



B, Coronal spoiled gradient-echo sequence in same patient shows the larger right lateral ventricle and apparent thinning of the right fornix (arrow).

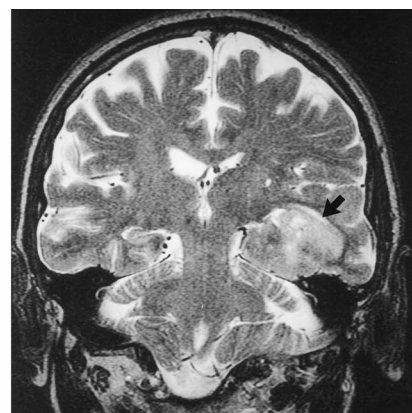


FIG 6. Coronal T2-weighted image (4000/105/1) shows a left-sided posterior temporal tumor (arrow). Also evident is the larger right lateral ventricle and apparent thinning of the right fornix, which are unrelated to the tumor.

Among the eight patients with a difference in ventricular size of 25% or greater, in five cases, the larger ventricle was on the side of mesial temporal sclerosis. In all these, the ipsilateral fornix was smaller. The difference in size of the fornices ranged from 33% in a patient with a 26% difference in ventricular size to 99% in a patient with a 122% difference in ventricular size (Fig 3). In three of eight, the contralateral ventricle was larger. In two of these, the left and right fornices were equal; in the third case, the fornix was thinner ipsilateral to the larger ventricle (Fig 4).

Of the two patients with seizures and asymmetric ventricles but without mesial temporal sclerosis, one had a posterior temporal cavernous angioma with an ipsilateral larger ventricle and smaller fornix (Fig 5), and the other had a temporal lobe glioma with a contralateral larger ventricle and smaller fornix (Fig 6). In both cases, the difference in thickness of the fornices was 60% or greater, with the thinner fornix ipsilateral to the larger ventricle.

Discussion

The advent of MR imaging has allowed the medial temporal structures to be depicted in the coronal plane with remarkable clarity. Abnormal signal and hippocampal atrophy are accepted as common features of mesial temporal sclerosis. Because of the intimate association between the hippocampus and other limbic structures, it is not surprising that other regions of the brain may also be affected in cases of mesial sclerosis. Efferents from the hippocampus and subiculum form the fornix, which courses anteriorly as the alveus, fimbria, crura, body, and then descending columns (4). These then divide into precommissural and postcommissural fibers at the level of the anterior commissure (5). The postcommissural fibers are directed almost exclusively to the mammillary bodies. In 1989, Lindboe et al (6) reported autopsy evidence of a small ipsilateral mammillary body in patients with mesial temporal sclerosis. The proposed explanation for this asymmetry was atrophy of the mammillary body

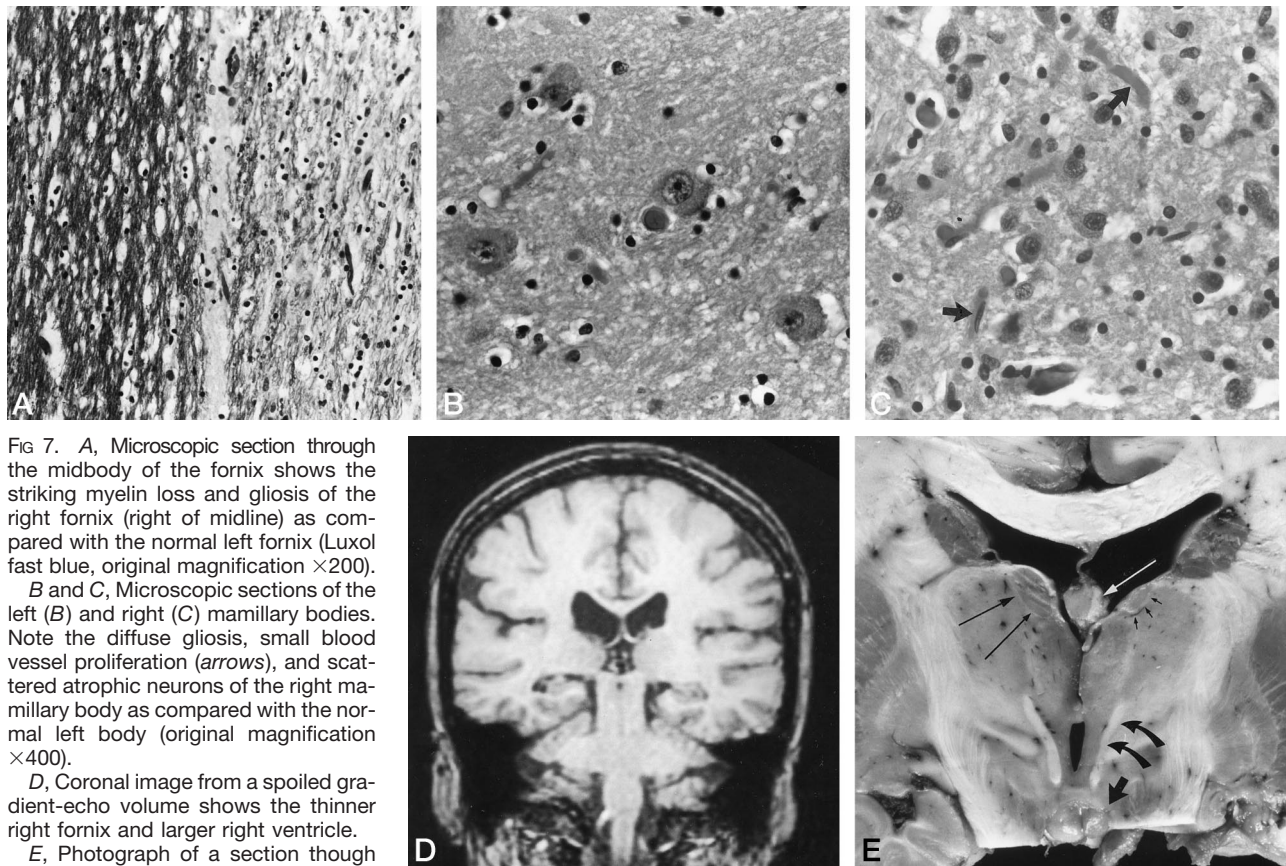


FIG 7. A, Microscopic section through the midbody of the fornix shows the striking myelin loss and gliosis of the right fornix (right of midline) as compared with the normal left fornix (Luxol fast blue, original magnification $\times 200$).

B and C, Microscopic sections of the left (B) and right (C) mamillary bodies. Note the diffuse gliosis, small blood vessel proliferation (arrows), and scattered atrophic neurons of the right mamillary body as compared with the normal left body (original magnification $\times 400$).

D, Coronal image from a spoiled gradient-echo volume shows the thinner right fornix and larger right ventricle.

E, Photograph of a section through the mamillary bodies reveals the smaller right mamillary body (short wide arrow), mamillothalamic tract (curved arrows), and anterior nucleus of the thalamus (small arrows). The normal left anterior thalamus is indicated by the long black arrows. Note atrophy of the right fornix (white arrow). (Right is on the viewer's right.)

caused by deafferentation related to injury of the medial temporal lobe. This effect is amplified after medial temporal surgery or stroke, since there is a complete loss of input (2, 3). Because the fibers that project to the mamillary body from the hippocampus course through the fornix, it is quite reasonable that asymmetry of the fornix may also be seen in some cases of mesial temporal sclerosis.

On the basis of our observation that ventricular asymmetry frequently accompanies asymmetry of the fornices, we looked at the MR studies in 18 patients with proved mesial temporal sclerosis. Ventricular asymmetry was common in this group of patients, with 15 revealing a 10% or greater difference in size between the ventricular cross-sectional areas. In three cases, in which the ventricles were equal or only slightly (7%) asymmetric, the fornix ipsilateral to the side of mesial sclerosis appeared thinner. In such circumstances it is reasonable to argue that this reflects true atrophy of the fornix.

In the one patient who died suddenly (case 8), the cut brain showed striking ipsilateral atrophy of the fornix (Fig 7A) and mamillary body (Fig 7B and C). The finding in this case must be considered with full awareness that the patient had had temporal lobe surgery 1 year earlier. Nevertheless, the imaging findings document that this change was present before surgery, since asymmetry of the fornix was evident on

the preoperative imaging examination (Fig 7D). In addition, the autopsy graphically demonstrated a finding in the thalamus that has not been appreciated at imaging, namely, atrophy of the mamillothalamic tract and anterior thalamus (Fig 7E). Thalamic findings on MR images have recently been reported in connection with middle cerebral artery infarction (7), and were considered to be a remote effect of the infarction, or so-called diaschisis. Animal experiments and positron emission tomographic (PET) studies have uncovered evidence of thalamic injury in epilepsy. In one experiment with rats, a topical convulsant was applied to the brain, causing seizures. At autopsy, spongiform changes were identified in the ipsilateral thalamus (8). Thalamic injury was reported in humans in the study by Margerison and Corsellis (9) based on autopsy material of patients with temporal lobe epilepsy, and PET studies have shown interictal abnormal thalamic cerebral glucose metabolism in children (10).

In our cases, thalamic atrophy was most likely due to deafferentation. The efferents from the mamillary bodies project to the anterior thalamus via the mamillothalamic tract, which was also atrophied. This, then, represents another distant limbic effect of medial temporal injury and provides an elegant demonstration of the connections of the circuit of Papez. Efferents from the thalamus are then directed to the

cingulate gyrus, the cingulate bundle, and back to the hippocampus.

Ventricular asymmetry is a common finding on MR images of the brain, and our own small series indicates that this is not a useful localizing sign, since the larger ventricle was frequently contralateral to the diseased hippocampus (four of 18 cases). Still, it is not unreasonable in some cases to suppose that ventricular enlargement may accompany mesial temporal sclerosis, since it would appear that substance loss of the adjacent thalamus is at least possible. An association between ventricular size and mesial temporal sclerosis might explain the high prevalence of thinning of the fornix noted by Baldwin et al (1). The difficulty would arise in differentiating such a case from the normally encountered ventricular asymmetry. Since we measure the fornix in cross section, a change in contour could affect the apparent width of the fornix. This problem was addressed in a study by Bilir et al, who measured the thickness of the fornix not on one cross section but rather by a volumetric technique on multiple sections (11). These authors added this measurement to that of the mamillary body volume, and the total volume of the two measurements was used to locate correctly the side of epileptogenic focus in 82% of cases.

In our two patients who did not have mesial temporal sclerosis, the fornix ipsilateral to the larger ventricle was thinner. In no case was the smaller fornix contralateral to the larger ventricle; in one, the smaller fornix was contralateral to the side of mesial sclerosis. The two patients with contralateral ventricular enlargement and equally sized fornices would seem to be exceptions to this rule. We propose that since the fornix may be small in association with mesial temporal sclerosis and also may appear smaller with ventricular enlargement, the net result in these two cases was that they appeared equal in size. In the patient with the thinner fornix contralateral to the side of mesial sclerosis, the changes were not typical: there was no signal abnormality, and although the left hippocampus appeared smaller on two sections, depth electrodes indicated a right temporal origin. The patient has been seizure free since undergoing right hippocampal resection, in which pathologic evaluation of the tissue confirmed right mesial temporal sclerosis. That patient's history was also atypical, in that her seizures began at age 30, when she suffered toxic shock syndrome accompanied by hypoxia and coma. The changes in the left hippocampus may have reflected selective vulnerability atrophy of the hippocampus related to that illness or bilateral mesial temporal sclerosis.

We did not identify asymmetry of the fornix in our patients with mesial temporal sclerosis at the same

rate of frequency as Baldwin et al did (1). These authors noted a small fornix in 12 (92%) of their cases, whereas in eight (44%) of our 18 cases the left and right fornix appeared symmetric. Perhaps their higher yield with this finding reflects higher resolution attained with the dedicated temporal phased-array coil they used, which might have allowed imaging of more subtle asymmetry of the fornix than we perceived. Our findings are more in line with the results obtained by Kim et al (3), who found an ipsilateral smaller fornix in 39% of their patients with mesial temporal sclerosis and in 6% of their control subjects; in one (3%) of their 33 patients, the smaller fornix was contralateral to the side of mesial temporal sclerosis.

Conclusions

Our experience supports the contention that atrophy of the fornix may accompany mesial temporal sclerosis. In patients with ventricular asymmetry, the thinner fornix may not, however, provide an accurate lateralizing sign for mesial temporal sclerosis, and in those cases a volumetric technique may be necessary.

References

1. Baldwin GN, Tsuruda JS, Maravilla KR, Hamill GS, Hayes CE. **The fornix in patients with seizures caused by unilateral hippocampal sclerosis: detection of unilateral volume loss on MR images.** *AJR Am J Roentgenol* 1994;162:1185-1189
2. Mamourian AC, Rodichok L, Javad T. **The asymmetric mamillary body: association with medial temporal lobe disease demonstrated with MR.** *AJNR Am J Neuroradiol* 1995;16:517-522
3. Kim JH, Tien RD, Felsberg GJ, Osumi AK, Lee N. **Clinical significance of asymmetry of the fornix and mamillary body on MR in hippocampal sclerosis.** *AJNR Am J Neuroradiol* 1995;16:509-515
4. Naidich TP, Daniels DL, Haughton VM, et al. **Hippocampal formation and related structures of the limbic lobe: anatomic-MR correlation, II: sagittal sections.** *Radiology* 1987;162:755-761
5. Mark LP, Daniels DL, Naidich TP, Hendrix LE. **Anatomic moment: limbic connections.** *AJNR Am J Neuroradiol* 1995;16:1303-1306
6. Lindboe CF, Erichsen AA, Strom EH. **Atrophy and sponginess of the mammillary bodies with neuronal sparing: not only inactive Wernicke's encephalopathy.** *Acta Pathol Microbiol Immunol Scand* 1989;97:667-670
7. Ogawa T, Yoshida Y, Okudera T, Noguchi K, Kado H, Uemura K. **Secondary thalamic degeneration after cerebral infarction in the middle cerebral artery distribution: evaluation with MR imaging.** *Radiology* 1997;204:255-262
8. Collins RC, Olney JW. **Focal cortical seizures cause distant thalamic lesions.** *Science* 1982;218:177-179
9. Margerison JH, Corsellis JAN. **Epilepsy and the temporal lobes.** *Brain* 1966;89:499-530
10. Chugani HT, Rintahaka PJ, Shewmon DA. **Ictal patterns of cerebral glucose utilization in children with epilepsy.** *Epilepsia* 1994;35:813-822
11. Bilir E, Hugg JW, Gilliam FG, Faught RE, Craven WJ, Kuzniecky RI. **Volumetry of limbic structures lateralizes temporal lobe epilepsy.** In: *Abstracts from the Annual Meeting of the International Society for Magnetic Resonance in Medicine*, New York, NY: 1996: 230