

Get Clarity On Generics

Cost-Effective CT & MRI Contrast Agents



FRESENIUS
KABI

WATCH VIDEO

AJNR

Coil embolization of a trigeminal-cavernous fistula.

K Bernstein, G P Teitelbaum, B Herman and S L Giannotta

AJNR Am J Neuroradiol 1998, 19 (10) 1953-1954

<http://www.ajnr.org/content/19/10/1953>

This information is current as
of August 15, 2025.

Coil Embolization of a Trigeminal-Cavernous Fistula

Keith Bernstein, George P. Teitelbaum, Brian Herman, and Steven L. Giannotta

Summary: A 53-year-old woman spontaneously incurred a right trigeminal artery–cavernous sinus fistula, manifested by an intracranial bruit and right sixth nerve palsy. This lesion was successfully managed by coil embolization via the transvenous and transarterial routes.

The trigeminal artery is a persistent, embryonic, vascular anastomotic connection between the cavernous internal carotid artery (ICA) and the basilar artery. Its rate of occurrence is between 0.1% and 0.3% (1, 2). Generally, flow within the trigeminal artery is from the ICA to the basilar artery. We describe a case of a spontaneous fistula from the trigeminal artery to the cavernous sinus.

Case Report

A previously healthy right-handed 53-year-old woman was gardening when she experienced the sudden onset of a pulsatile bruit in her right ear and double vision. Upon examination in an emergency department 10 days after the onset of symptoms, she was found to have a right orbital bruit and a right sixth nerve palsy. An arteriogram showed the presence of a Saltzman type 2 persistent trigeminal artery (3) associated with a right-sided trigeminal-cavernous fistula (Fig 1A) as well as a carotid-cavernous fistula (Fig 1B). No discrete aneurysm or cortical venous filling was seen. The direction of filling of the trigeminal artery was from the basilar artery to the right cavernous sinus.

One week after the initial angiogram, elective endovascular treatment of the lesion was undertaken. Via the right transfemoral approach, using systemic heparinization, and with the patient under general endotracheal anesthesia, a 6F guiding catheter was directed into the right ICA. Through this guiding catheter, a microcatheter distally mounted with an Interventional Therapeutics Corp. detachable silicone balloon was directed under digital roadmap imaging into the distal right ICA. The microcatheter with its detachable silicone balloon could not be flow-directed across the rent in the cavernous right ICA. Next, using the left transfemoral venous approach, a 7F Bernstein catheter was directed into the right internal jugular vein. A coaxial microcatheter was directed over a 0.016-inch guidewire through the right inferior petrosal sinus, into the right cavernous sinus, and finally into the right superior ophthalmic vein. Ninety fibered platinum microembolization coils were delivered through the microcatheter to occlude the posterior right superior ophthalmic vein and the right cavernous sinus. Repeat contrast injection within the right ICA showed almost complete obliteration of the fistula from the right anterior circulation (Fig 1C). However, contrast injection within the left vertebral artery showed residual flow through the tri-

geminal-cavernous fistula (Fig 1D). For this reason, a coaxial, two-tip marker microcatheter was directed over a steerable guidewire using digital roadmap imaging through the basilar artery and subsequently into the trigeminal artery. The catheter was advanced to the junction of the trigeminal artery and the fistula, where seven platinum microembolization coils were deposited. A repeat vertebral arteriogram showed complete occlusion of the fistula (Fig 1E). The patient was awakened from general endotracheal anesthesia and was noted to have sustained mild left hemiparesis and dysarthria, believed to be the result of a right hemispheric stroke. Immediately after the procedure, the patient noted that her intracranial bruit had resolved. The hemiparesis and dysarthria gradually resolved over the next several weeks with physical and speech therapy. The right sixth nerve palsy and diplopia resolved over the next 3 months. At 12 months after embolization, the patient had had no recurrence of intracranial bruit or diplopia.

Discussion

The blood supply to the developing hindbrain is derived from a series of channels connecting the developing carotid arteries and the longitudinal neural arteries. These connections include the posterior communicating, trigeminal, otic, hypoglossal, proatlantal, intersegmental, and persistent cervical intersegmental arteries. All of these normally regress, except for the posterior communicating artery (4, 5). The trigeminal artery is the most common persistent connection. It is associated with vascular steal, ocular palsies, aneurysmal formation, vascular rupture, subarachnoid hemorrhage, trigeminal neuralgia, and arteriovenous fistula (1, 2, 6–9). In our case, an aneurysm was not found, but the spontaneous development of a trigeminal-cavernous fistula suggests that one may have been present. There is a 14% chance of an intracranial aneurysm being found in association with a trigeminal artery, but aneurysms of the trigeminal artery itself have a significantly lower rate of occurrence of (10). An alternative explanation for the fistula in our patient is spontaneous vascular rupture. Some authors have suggested that structural abnormalities may exist in the wall of the trigeminal artery that predispose toward vascular rupture (11, 12).

The goal of therapy in repairing carotid-cavernous fistulas is to preserve vision, eliminate intracranial bruit, and avoid ischemic and hemorrhagic complications. Emergency treatment of these lesions is neces-

Received October 8, 1997; accepted after revision February 9, 1998.

From the Departments of Neuroradiology (K.B.) and Neurological Surgery (G.P.T., S.L.G.), USC School of Medicine, Los Angeles, CA; and the Department of Radiology, Harbor-UCLA Medical Center, Torrance, CA (B.H.).

Address reprint requests to George Teitelbaum, MD, USC University Hospital, 1500 San Pablo St, 2nd Floor, Los Angeles, CA 90033.

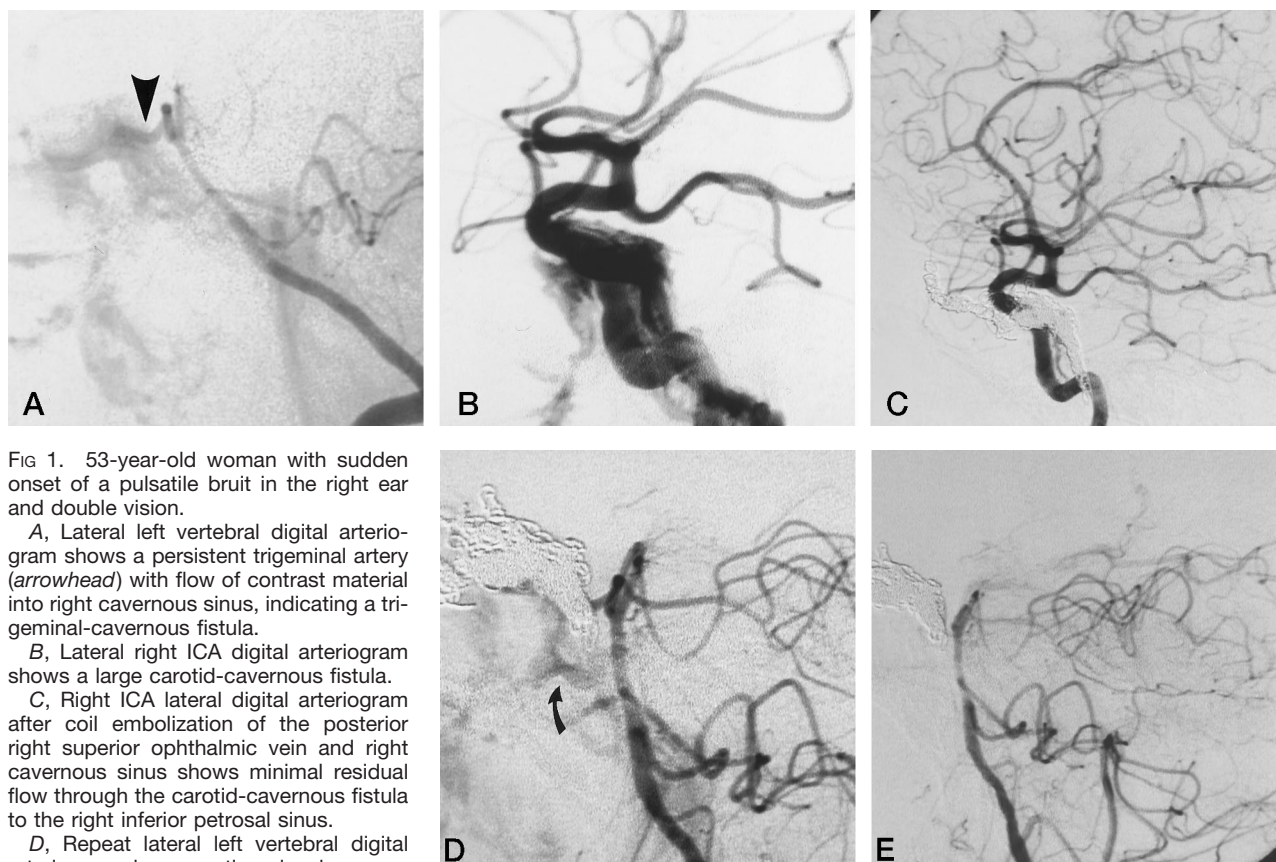


FIG 1. 53-year-old woman with sudden onset of a pulsatile bruit in the right ear and double vision.

A, Lateral left vertebral digital arteriogram shows a persistent trigeminal artery (arrowhead) with flow of contrast material into right cavernous sinus, indicating a trigeminal-cavernous fistula.

B, Lateral right ICA digital arteriogram shows a large carotid-cavernous fistula.

C, Right ICA lateral digital arteriogram after coil embolization of the posterior right superior ophthalmic vein and right cavernous sinus shows minimal residual flow through the carotid-cavernous fistula to the right inferior petrosal sinus.

D, Repeat lateral left vertebral digital arteriogram shows continued early venous opacification (arrow), the result of residual flow through the trigeminal-cavernous fistula.

E, Postembolization lateral left vertebral digital arteriogram shows no further filling of the trigeminal artery and obliteration of the trigeminal cavernous fistula.

sary when there is progressive vision loss and the development of cortical and/or deep cerebral venous drainage (13, 14). Treatment is generally by transarterial delivery of a detachable balloon within the affected cavernous sinus (2, 7, 8, 15, 16). Carotid-cavernous fistulas have also been treated by transvenous embolization using balloons, coils, and liquid adhesive agents (13, 17).

Conclusion

This is an unusual case of a trigeminal-cavernous fistula that was occluded by coil embolization of the cavernous sinus and the trigeminal artery via the transvenous and transarterial routes, respectively.

References

- Berger MS, Hsibuchi Y. Cavernous sinus fistula caused by intracavernous rupture of a persistent primitive trigeminal artery: case report. *J Neurosurg* 1984;61:391-395
- Guglielmi G, Viñuela F, Dion J, Duckwiler G, Cantore G, Delfini R. Persistent primitive trigeminal artery-cavernous sinus fistulas: report of two cases. *Neurosurgery* 1990;27:805-808
- McKenzie JD, Dean BL, Flom RA. Trigeminal-cavernous fistula: Saltzman anatomy revisited. *AJNR Am J Neuroradiol* 1996;17:280-282
- Diaz FG, Zinkle JF. Surgical management of vertebrobasilar ischemic disease. In: Carter LP, Spetzler RF, eds. *Neurovascular Surgery*. New York: McGraw-Hill; 1995:406
- Silver JM, Wilkins RH. Persistent embryonic intracranial and extracranial vessels. In: Wilkins RH, Rengachary SS, eds. *Neurosurgery*. New York: McGraw-Hill; 1996:2529-2539
- Cheng W-C, Wang AD. Carotid-cavernous sinus fistula associated with a primitive trigeminal artery. *Neurosurgery* 1990;27:802-805
- Debrun GM, Davis KR, Navta HJ, Heros RE, Ahn HS. Treatment of carotid cavernous fistulae or cavernous aneurysms associated with a persistent trigeminal artery: report of three cases. *AJNR Am J Neuroradiol* 1988;9:749-755
- Flandroy P, Lacour P, Marsault C, Stevenaert A, Collignon J. Intravascular treatment of a cavernous fistula caused by rupture of a traumatic carotid trigeminal aneurysm. *Neuroradiology* 1987;29:308-311
- Kempe LG, Smith DR. Trigeminal neuralgia, facial spasm, intermedius, and glossopharyngeal neuralgia with persistent carotid basilar anastomosis. *J Neurosurg* 1969;31:445-451
- George AE, Lin JP, Morantz RA. Intracranial aneurysm on a persistent trigeminal artery: case report. *J Neurosurg* 1971;35:601-604
- Lewis AI, Tomsick TA, Tew JM. Carotid cavernous fistulas and intracranial aneurysms. In: Wilkins RH, Rengachary SS, eds. *Neurosurgery*. New York: McGraw-Hill; 1996:2529-2539
- Lie TA. Variations in cerebrovascular anatomy. In: Fox J, ed. *Intracranial Aneurysms*. New York: Springer; 1983;1:432-489
- Debrun G. Management of traumatic carotid-cavernous fistulas. In: Viñuela F, Halbach VV, Dion JE, eds. *Interventional Neuroradiology: Endovascular Therapy of the Central Nervous System*. New York: Raven; 1992:107-112
- Halbach VV, Hieshima GB, Higashida RT, Reicher M. Carotid cavernous fistulae: indications for urgent treatment. *AJR Am J Roentgenol* 1987;149:587-593
- Kerber CW, Manke W. Trigeminal artery to cavernous sinus fistula treated by balloon occlusion: case report. *J Neurosurg* 1983;58:611-613
- Markham JW. Carotid-cavernous sinus fistula treated by intravascular occlusion with a balloon catheter. *J Neurosurg* 1974;40:535-538
- Halbach VV, Higashida RT, Hieshima GB, Hardin CW, Yang PJ. Transvenous embolization of direct carotid cavernous fistulas. *AJNR Am J Neuroradiol* 1988;9:741-747