



## Discover Generics

Cost-Effective CT & MRI Contrast Agents



WATCH VIDEO

# AJNR

### **Periantral soft-tissue infiltration and its relevance to the early detection of invasive fungal sinusitis: CT and MR findings.**

C S Silverman and A A Mancuso

*AJNR Am J Neuroradiol* 1998, 19 (2) 321-325

<http://www.ajnr.org/content/19/2/321>

This information is current as of June 5, 2025.

# Periantral Soft-Tissue Infiltration and Its Relevance to the Early Detection of Invasive Fungal Sinusitis: CT and MR Findings

Craig S. Silverman and Anthony A. Mancuso

**PURPOSE:** Our goal was to illustrate the relevance of periantral soft-tissue infiltration to the early diagnosis of invasive fungal sinusitis and to describe variations in the appearance of normal periantral soft tissues.

**METHODS:** We reviewed two cases of pathologically proved invasive maxillary fungal sinusitis in which the sole imaging finding suggestive of invasive disease was periantral soft-tissue infiltration. Variations in the CT appearance of normal periantral soft tissues were studied in 112 patients by assessing the appearance of the fat planes along the anterior and posterior bony antral walls and by noting the presence of infraorbital and distal internal maxillary artery branch vessels within the anterior and posterior periantral fat planes, respectively.

**RESULTS:** None of the 112 patients had findings that suggested, or that could mimic, soft-tissue infiltration in the anterior periantral soft tissues. In only one (1%) of the 112 patients was there a loss of visibility of the posterior periantral fat plane that was not clearly attributable to the otherwise normal-appearing posterior periantral soft tissues.

**CONCLUSION:** Infiltration of the periantral fat planes may represent the earliest imaging evidence of invasive fungal disease. When encountered as the sole radiologic finding, periantral soft-tissue infiltration should suggest the possibility of invasive fungal sinusitis in the appropriate clinical setting.

Invasive fungal sinusitis can be a rapidly progressive, fatal disease that requires aggressive treatment. Clinical conditions posing added risk are poorly controlled diabetes mellitus and diabetic ketoacidosis (1–6), leukemia and bone marrow transplant (7–10), end-stage renal disease (11), prolonged antibiotic and corticosteroid treatment (12, 13), and chronic immunosuppressive therapy (14); but invasive fungal sinusitis may also, albeit rarely, be seen in apparently healthy individuals (15, 16). Orbital and intracranial involvement are the most devastating of its potential consequences; therefore, early detection is crucial, and imaging has an essential role in this regard.

Imaging has classically been used to evaluate invasive fungal sinusitis in support of the clinical suspicion of invasive disease. Bone destruction has been a prime determinant of aggressive disease, and information about bone involvement as well as involve-

ment of contiguous structures such as the orbit and brain is useful in surgical planning. The purpose of this article is to illustrate how isolated periantral soft-tissue infiltration can lead to an early diagnosis of invasive fungal sinusitis. The appearance of periantral soft-tissue infiltration due to invasive fungal disease on computed tomography (CT) scans and magnetic resonance (MR) images is contrasted with the normal appearance of the periantral soft tissues.

## Methods

### Case 1

A 35-year-old woman with a history of poorly controlled insulin-dependent diabetes mellitus, chronic renal failure, and multiple previous admissions for diabetic ketoacidosis was admitted for diabetic ketoacidosis. She also reported pain over the left maxillary sinus and was noted to have periorbital erythema on physical examination. A CT scan showed mucosal thickening in the left maxillary sinus, left-sided preseptal cellulitis, and abnormal soft-tissue attenuation material infiltrating the periantral fat planes (Fig 1). No bone destruction was noted, and the nasal cavity, orbit, and intracranial structures were normal. A nasal specimen was negative for fungal stain and, despite the radiologic suggestion of invasive disease, the patient was discharged on antibiotics.

The culture of the nasal specimen eventually grew *Rhizopus* organisms and the patient was readmitted with the diagnosis of paranasal mucormycosis and started on intravenous amphoteric-

---

Received May 1, 1997; accepted after revision July 24.

Presented at the annual meeting of the American Society of Head and Neck Radiology, Toronto, Canada, May 1997.

From the Department of Radiology, University of Florida College of Medicine, 1600 SW Archer Rd, Box 100374 JHMHC, Gainesville, FL 32610. Address reprint requests to Craig S. Silverman, MD.

FIG 1. Case 1: Invasive mucormycosis. Axial contrast-enhanced CT scan shows soft-tissue infiltration of the left anterior periantral fat plane (arrowhead) and the left posterior periantral fat plane (arrow).

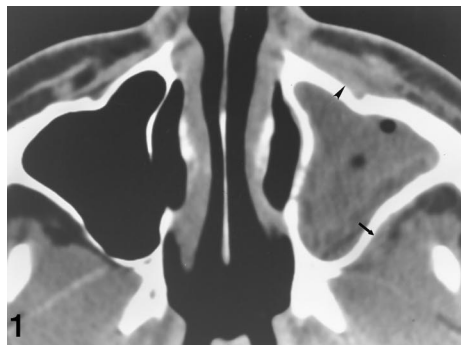
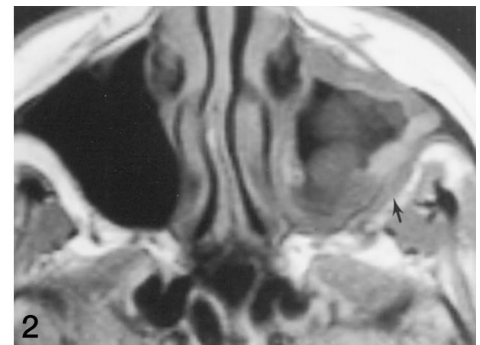


FIG 2. Case 2: Invasive aspergillosis. Axial T1-weighted MR image (600/15/2 [repetition time/echo time/excitations]) shows infiltration of the left posterior periantral fat plane (arrow).



icin B. She reported increasing headaches and pain involving the left side of the face. A CT scan showed a decrease in the preseptal cellulitis but otherwise persistent mucosal thickening in the left maxillary sinus and persistent abnormal periantral soft tissues. The nasal cavity, bones, orbit, and brain remained normal. At surgical exploration via a Caldwell-Luc approach, the maxillary sinus was filled with fungal elements as well as purulent material. The nasal cavity was normal. The fungus did not appear to invade the mucosa (no necrosis or black eschar-type tissue was noted) and the bony antrum was of normal integrity. The frozen section revealed fungal elements without invasive characteristics; however, permanent sections later showed invasive mucormycosis.

#### Case 2

A 43-year-old woman with acquired immunodeficiency syndrome (AIDS) had a 3-month history of headaches and left-sided facial pain around the eye and over the maxilla. During the course of these symptoms, a left antral punch had been performed with negative culture, and she was treated with antibiotics prophylactically. When the symptoms did not resolve, a CT scan was obtained, which showed mucosal thickening of the left maxillary sinus, a focal area of bone destruction involving the lateral aspect of the posterior bony antral wall, and abnormal soft-tissue attenuation material infiltrating the posterior periantral fat plane. Involvement of the orbit was also seen at this time. At surgical exploration, edematous mucosa with a necrotic appearance was noted. Biopsy specimens revealed *Aspergillus* organisms and cultures later grew *Aspergillus fumigatus*. The patient was treated with intravenous amphotericin B.

At the time of the CT examination, a review of a prior MR study of the head, performed approximately 1 month earlier for recurrent headaches, revealed a previously unrecognized abnormality in the posterior periantral soft tissues (Fig 2).

#### Analysis of Normal Periantral Soft Tissues

Variations in the CT appearance of normal periantral soft tissues were studied in 112 patients examined over a 9-month period. The records of these patients were obtained from computer-generated lists of previous maxillofacial CT examinations and from ongoing daily cases. The study group included 67 female and 47 male subjects, 2 to 88 years old (mean age, 37 years), with both normal maxillary sinuses ( $n = 75$ ) and noninvasive inflammatory disease of the maxillary sinuses ( $n = 37$ ). Of those with noninvasive inflammatory disease, 21 patients had total or near total opacification and 13 patients had increased attenuation within the secretions, consistent with drying and/or fungal colonization.

The CT studies included both noncontrast and contrast-enhanced scans obtained through the maxillary antrum and periantral soft tissues with 3-mm-thick axial sections at scan intervals of 3 to 5 mm. Exclusion criteria included scan thick-

ness other than 3 mm, scan intervals greater than 5 mm, poor filming technique, prior sinonasal surgery, and pathologic findings other than noninvasive inflammatory disease involving the maxillary sinus or periantral soft tissues discovered either in the clinical history or incidentally during review of the CT scan. The pathologic conditions resulting in exclusion were neoplasms of the maxillary sinus, orbit, masticator space, and infratemporal fossa; facial and orbital trauma; and infections of the orbit, preseptal soft tissues, and deep facial soft tissues.

Imaging features of the normal periantral soft tissues that were assessed included the appearance of the fat planes along the anterior and posterior bony antral walls and the presence of blood vessels within the two fat planes. The appearance of the anterior periantral fat plane was analyzed for the presence of a distinct plane of fat attenuation along the anterior bony antral wall between the muscles of facial expression and the bony antrum. The retroantral fat plane was analyzed for the presence of a distinct plane of fat attenuation along the posterior bony antral wall. Along its more cephalad component, the retroantral fat plane was defined as extending laterally from, but not including, the pterygopalatine fossa, while along its more inferior component, it was defined as extending laterally from the lateral pterygoid plate. When the CT scan was interpreted as "negative" for the presence of a distinct plane of fat attenuation, the presumed reasons for the nonvisible fat plane were identified; these included less periantral fat tissue and contact between the otherwise normal periantral soft tissues and the bony antral wall. The findings were recorded and distinguished from any finding that could mimic periantral soft-tissue infiltration, thereby raising the suggestion of invasive fungal sinusitis. The infraorbital and distal internal maxillary artery branch vessels were analyzed for their conspicuity as discrete foci of soft-tissue attenuation within the anterior periantral and retroantral fat planes, respectively.

All CT scans were reviewed independently by two radiologists with different levels of expertise. The first was a neuroradiologist with 20 years' experience in head and neck radiology, and the second was in subspecialty training in neuroradiology.

#### Results

Results are reported for the primary interpreter, as only minor differences existed between the two readers, and these were related only to normal variations in the appearance of the periantral soft tissues. The two interpreters agreed in all cases with respect to normality of scan findings and to any findings that could mimic periantral soft-tissue infiltration.

None of the 112 patients had findings in the anterior periantral soft tissues that suggested or mimicked soft-tissue infiltration. The anterior periantral fat plane was seen bilaterally as a distinct plane of fat attenuation along its entire cephalocaudal extent in

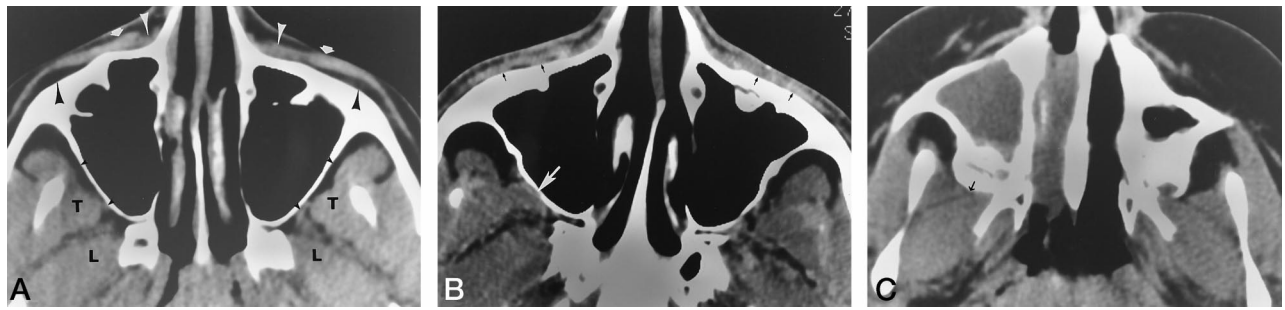


FIG 3. Normal variations in the CT appearance of the periantral soft tissues.

A, Noncontrast CT scan shows the normal anterior and posterior periantral soft tissues: anterior periantral fat planes (*large black arrowheads*), levator labii superioris alaeque nasi muscles (*white arrowheads*), and orbicularis oculi muscles (*white arrows*); retroantral fat planes (*small black arrowheads*), temporalis muscles (T), and lateral pterygoid muscles (L).

B, Contrast-enhanced CT scan shows nonpathologic loss of visibility of the more cephalic aspect of the anterior periantral fat planes bilaterally (*black arrows*) and the right retroantral fat plane (*white arrow*).

C, Noncontrast CT scan shows nonpathologic loss of visibility of the more caudal aspect of the right retroantral fat plane (*arrow*) in the presence of an unerupted third molar.

108 (96%) of 112 patients, whereas in four (4%) of the 112 patients the anterior periantral fat plane was not seen in its most cephalad aspect. The lack of visibility of the anterior periantral fat plane was clearly attributed to the otherwise normal-appearing anterior periantral soft tissues, with contact between the superficial soft tissues of the face and the anterior bony antral wall.

One hundred eleven (99%) of the 112 patients had no findings in the posterior periantral soft tissues that suggested or that mimicked soft-tissue infiltration. The retroantral fat plane was seen bilaterally as a distinct plane of fat attenuation along its entire cephalocaudal extent in 72 (64%) of the patients; the remaining 40 patients (36%) had variable loss of visualization of the retroantral fat plane along its cephalocaudal extent. In 39 of these 40 patients, loss of visibility of the retroantral fat plane was clearly attributed to the otherwise normal-appearing posterior periantral soft tissues, with contact between the temporalis and/or lateral pterygoid muscles and the posterior bony antral wall. In only one patient (1%) was loss of visibility of the retroantral fat plane not clearly attributable to otherwise normal-appearing posterior periantral soft tissues.

The infraorbital artery branch vessels were seen bilaterally as discrete foci of soft-tissue attenuation within the anterior periantral fat plane in 108 (96%) of 112 patients. These vessels were not seen on either side in two patients, and they were not seen on one side in two patients. The distal internal maxillary artery branch vessels were seen bilaterally as discrete foci of soft-tissue attenuation within the retroantral fat plane in all patients.

## Discussion

### Normal Periantral Soft Tissues

The majority of patients in our study had a distinct periantral fat plane both anteriorly and posteriorly (Fig 3A). However, variation in the appearance of the periantral soft tissues does occur, and loss of visibility

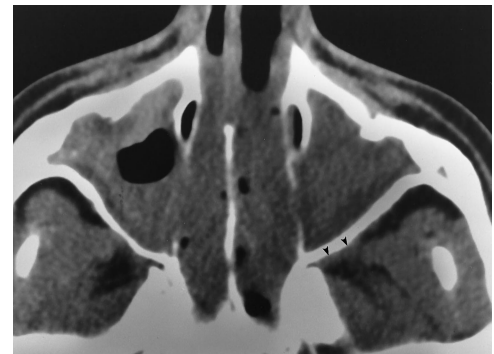


FIG 4. Noncontrast CT scan shows a single instance of soft-tissue attenuation material in the left retroantral fat plane (*arrowheads*) that could mimic soft-tissue infiltration.

of both the anterior periantral and retroantral fat planes may occur for nonpathologic reasons. Most commonly, this loss appeared to be related to variations in the amount of adipose tissue. Decreased amounts of adipose tissue caused the surrounding normal periantral soft tissues to appose the bony antral wall and obscure the periantral fat plane (Fig 3B). This tended to occur in the more cephalad aspects of both the anterior periantral and retroantral fat planes. Anteriorly, the adjacent orbicularis oculi muscle and superficial soft tissues of the face could then appose the anterior bony antral wall and obscure the anterior periantral fat plane. Posteriorly, the temporalis muscle and, less likely, the lateral pterygoid muscle could then appose the posterior bony antral wall and obscure the retroantral fat plane. Additionally, in some pediatric patients, unerupted third molars appeared to distort and decrease the size of the inferior aspect of the infratemporal fossa, also causing these muscles to obscure the retroantral fat plane (Fig 3C).

In only one of the 112 patients in the study was there any finding that suggested, or that could mimic, soft-tissue infiltration (Fig 4). Although this finding was seen in the retroantral soft tissues of a maxillary sinus that was nearly completely opacified and that



showed increased density, suggesting drying and/or fungal colonization, a review of the medical records did not reveal any information indicating that fungal or invasive sinus disease was ever diagnosed in this patient. The finding was most likely related to distal branch vessels of the internal maxillary artery, as it was in the appropriate location for these vessels, and the periantral soft tissues above and below the illustrated finding were normal, with the distal branch vessels of the internal maxillary artery appearing more discrete.

Perhaps equally as relevant is the lack of any findings in the periantral soft tissues of the remaining patients with totally or nearly totally opacified maxillary sinuses and of those in whom increased attenuation was seen. There were no findings that suggested or that mimicked soft-tissue infiltration in 20 (95%) of 21 patients with totally or nearly totally opacified maxillary sinuses or in the 12 (92%) of 13 patients with increased attenuation within the secretions. This helps exclude the possibility that periantral changes can occur with other noninvasive pathologic states, such as more severe noninvasive inflammatory disease, impaction and/or drying, and noninvasive fungal colonization.

### *Periantral Soft-Tissue Infiltration*

The radiologic characteristics of invasive fungal sinusitis have been described. Earlier reports, based on conventional radiography and tomography, focused primarily on multifocal bone destruction as an aid to the diagnosis of invasive fungal sinusitis and in the evaluation of the extent of advanced disease (3, 17). However, later reports have revealed that with the evolution in the recognition of invasive fungal sinusitis at conventional radiography, tomography, and CT, a corresponding change has occurred in the imaging features of this disease. A prominent imaging feature of the later reports is the presence of soft-tissue abnormalities outside the confines of the maxillary sinus, including advanced disease involving the orbit or brain prior to destructive bone changes (2, 6, 13, 18).

The finding of soft-tissue infiltration of the normal retroantral fat plane along the posterior wall of the maxillary sinus in the infratemporal fossa is illustrated in both our cases. This finding is supported by, and most consistent with, results obtained by Gamba et al (6). It also suggests extension of infection into the infratemporal fossa based on obliteration of the normal fat density that outlines the posterolateral wall of the maxillary sinus, implying that this can occur without bone destruction via perivascular channels. However, a review of their data reveals that all seven cases that suggested extension of infection into the infratemporal fossa, pterygopalatine fossa, or both by obliteration of fat density also had bone destruction, orbital involvement, or intracranial involvement. These investigators reported no case in which extension into the infratemporal fossa or pterygopalatine fossa was an isolated abnormality, and although they

did suggest that patients with involvement of deep paranasal tissues and orbit are at increased risk for intracranial involvement, they drew no conclusions regarding the course of invasive fungal disease or whether extension into these deep tissues precedes orbital or intracranial involvement.

The finding of soft-tissue infiltration of the normal anterior periantral fat plane along the anterior wall of the maxillary sinus is illustrated in case 1. Infiltration of the soft tissues of the face anterior to the maxillary sinus as a consequence of aggressive fungal infection was reported by Som and Curtin (18), but in conjunction with contiguous involvement of the nasal cavity. Case 1, however, exemplifies soft-tissue infiltration of the anterior periantral fat plane without involvement of the nasal cavity.

In noninvasive fungal sinusitis the fungal elements are limited to the lumen of the involved sinus, whereas invasive disease crosses the mucosa to variably involve blood vessels, bone, orbit, and intracranial structures. The fungi that cause both mucormycosis and aspergillosis of the paranasal sinuses are ubiquitous. They are species of the genera *Mucor*, *Rhizopus*, and *Absidia* and species of the genus *Aspergillus*, respectively. These fungi are normally saprophytic, but may become invasive in patients with the predisposing diseases described previously. Both invasive mucormycosis and aspergillosis have an affinity for invading blood vessels (19–23). In particular, invasive mucormycosis has a strong affinity for arteries. Histopathologic features include growth along the internal elastic lamina that results in dissection away from the media, as well as growth into the vessel lumen, producing endothelial damage and initiating thrombosis (23).

Possible theories, which are based on the affinity these fungi have for invading blood vessels, can be proposed to help explain early periantral soft-tissue infiltration prior to bone changes. The periantral soft-tissue infiltration may be a secondary finding. The propensity these fungi have to initiate thrombosis could result in vascular congestion, in which case, the periantral soft-tissue infiltration may be that of periantral “edema.” Alternatively, the periantral soft-tissue infiltration could represent the presence of fungal elements outside the maxillary sinus, which may be explained by the tendency these fungi have to spread along the vessels. Direct spread through the perivascular spaces into the periantral fat could account for the periantral soft-tissue infiltration beyond the confines of the maxilla.

Bone involvement has also been described with both invasive aspergillosis (15, 19, 21, 22) and invasive mucormycosis (20, 21). However, no pathogenesis or more chronologically ordered pathologic correlate has been described that could explain the early imaging finding of periantral soft-tissue infiltration. The CT scan in case 1 confirms that the abnormal periantral soft-tissue attenuation occurred before any demonstrable bone changes and preceded the more classic findings of bone destruction previously described in invasive fungal sinusitis.

At some institutions, MR imaging may be used in the initial evaluation of complicated sinusitis because of its ability to better depict advanced disease involving the orbit or brain, extraaxial space and meninges, and the cavernous sinuses. The MR image in case 2 illustrates abnormal periantral soft-tissue signal and enhancement without the more advanced disease, which MR imaging is often used to evaluate. Although the MR study in case 2 precludes definitive exclusion of the bone destruction subsequently seen on a CT scan, the abnormal periantral soft-tissue signal and enhancement, had it been recognized, would have prompted earlier intervention and appropriate treatment. Therefore, periantral soft-tissue infiltration represented the earliest imaging finding suggestive of invasive disease in both cases.

At our institution, CT is the primary imaging method used to evaluate the paranasal sinuses in patients undergoing bone marrow transplant, organ transplant, or immunosuppressive therapy. In these clinical settings, CT can serve as a baseline examination to determine a potential source for the fevers these patients often experience during treatment, as well as function as the initial examination when complicated sinusitis is suspected. Although the specific diagnosis of invasive fungal sinusitis requires histologic confirmation, imaging has particular utility in certain clinical situations, such as those in which the clinical signs and symptoms that suggest the possibility of invasive fungal sinusitis are not that profound and those in which the clinical indication is that of uncomplicated sinusitis and the imaging findings suggestive of invasive disease are unsuspected. It is in these difficult to manage and unsuspected cases that imaging, with its ability to detect subtle evidence of invasive sinus disease, has a crucial role in patient treatment.

### Conclusions

Our cases demonstrate the usefulness of imaging in the evaluation of invasive fungal sinusitis, in which periantral soft-tissue infiltration of the fat planes normally surrounding the maxillary sinus is illustrated. This potentially subtle finding beyond the confines of the maxillary sinus, before the more apparent evidence of bone destruction or contiguous involvement of the orbit or intracranial structures, may represent the earliest imaging manifestation of an aggressive process. In the appropriate clinical setting, a low threshold of suspicion is necessary to make the diagnosis of invasive fungal sinusitis, both radiologically and clinically. When seen as the sole imaging finding suggestive of invasive disease, periantral soft-tissue infiltration should raise the possibility of invasive fun-

gal sinusitis, a hypothesis that may impact patient care, leading to surgical exploration and biopsy, and perhaps resulting in an earlier diagnosis of invasive fungal sinusitis.

### References

1. Pillsbury HC, Fischer ND. **Rhinocerebral mucormycosis.** *Arch Otolaryngol* 1977;103:600-604
2. Centeno RS, Bentson JR, Mancuso AA. **CT scanning in rhinocerebral mucormycosis and aspergillosis.** *Radiology* 1981;140:383-389
3. Addlestone RB, Baylin GJ. **Rhinocerebral mucormycosis.** *Radiology* 1975;115:113-117
4. Terk MR, Underwood DJ, Zee C-S, Colletti PM. **MR imaging in rhinocerebral and intracranial mucormycosis with CT and pathologic correlation.** *Magn Reson Imaging* 1992;10:81-87
5. Yousem DM, Galetta SL, Gusnard DA, Goldberg HI. **MR findings in rhinocerebral mucormycosis.** *J Comput Assist Tomogr* 1989;13:878-882
6. Gamba JL, Woodruff WW, Djang WT, Yeates AE. **Craniofacial mucormycosis: assessment with CT.** *Radiology* 1986;160:207-212
7. Kavanagh KT, Hughes WT, Parham DM, Chanin LR. **Fungal sinusitis in immunocompromised children with neoplasms.** *Ann Otol Rhinol Laryngol* 1991;100:331-336
8. Berkow RL, Weisman SJ, Provisor AJ, Weetman RM, Baehner RL. **Invasive aspergillosis of paranasal tissues in children with malignancies.** *J Pediatr* 1983;103:49-53
9. Choi SS, Milmoe GJ, Dinndorf PA, Quinones RR. **Invasive aspergillus sinusitis in pediatric bone marrow transplant patients.** *Arch Otolaryngol Head Neck Surg* 1995;121:1188-1192
10. Berlinger NT. **Sinusitis in immunodeficient and immunosuppressed patients.** *Laryngoscope* 1985;95:29-33
11. Johnson EV, Kline LB, Julian BA, Garcia JH. **Bilateral cavernous sinus thrombosis due to mucormycosis.** *Arch Ophthalmol* 1988;106:1089-1092
12. Blodi FC, Hannah FT, Wadsworth JAC. **Lethal orbito-cerebral phycomycosis in otherwise healthy children.** *Am J Ophthalmol* 1969;67:698-705
13. Greenberg MR, Lippman SM, Grinnell VS, Colman MF, Edwards JE. **Computed tomographic findings in orbital mucor.** *West J Med* 1985;143:102-103
14. Lazo A, Wilner HI, Metes JJ. **Craniofacial mucormycosis: computed tomographic and angiographic findings in two cases.** *Radiology* 1981;139:623-626
15. Washburn RG, Kennedy DW, Begley MG, Henderson DK, Bennett JE. **Chronic fungal sinusitis in apparently normal hosts.** *Medicine* 1988;67:231-247
16. Lowe J, Bradley J. **Cerebral and orbital aspergillus infection due to invasive aspergillosis of ethmoid sinus.** *J Clin Pathol* 1986;39:774-778
17. Green WH, Goldberg HL, Wohl GT. **Mucormycosis infection of the craniofacial structures.** *AJR Am J Roentgenol* 1967;101:802-806
18. Som PM, Curtin HD. **Chronic inflammatory sinonasal diseases including fungal infections: the role of imaging.** *Radiol Clin North Am* 1993;31:33-44
19. Barnes L, Peel RL. **Head and Neck Pathology: A Text/Atlas of Differential Diagnosis.** New York, NY: Igaku-Shoin; 1990:170
20. Michaels L. **Ear, Nose, and Throat Histopathology.** New York, NY: Springer-Verlag; 1987:146-148
21. Johnson JT. **Infections.** In: Cummings CW, Krause CJ, eds. *Otolaryngology: Head and Neck Surgery.* 2nd ed. St Louis, MO: Mosby-Year Book; 1993:2:931-933
22. Myerowitz RL, Guggenheimer J, Barnes L. **Infectious diseases of the head and neck.** In: Barnes L, ed. *Surgical Pathology of the Head and Neck.* New York, NY: Marcel Dekker; 1985:1784-1786
23. Straatsma BR, Zimmerman LE, Gass JDM. **Phycomycosis: a clinicopathologic study of fifty-one cases.** *Lab Invest* 1962;11:963-985