



Discover Generics

Cost-Effective CT & MRI Contrast Agents



WATCH VIDEO

AJNR

The role of ^{99m}Tc HMPAO SPECT in the diagnosis of Creutzfeldt-Jacob disease.

D A Miller, R A Vitti and M M Maslack

AJNR Am J Neuroradiol 1998, 19 (3) 454-455

<http://www.ajnr.org/content/19/3/454>

This information is current as of June 2, 2025.

The Role of ^{99m}Tc HMPAO SPECT in the Diagnosis of Creutzfeldt-Jacob Disease

David A. Miller, Richard A. Vitti, and Mark M. Maslack

Summary: A patient with acute dementia underwent imaging of the brain with technetium-99m hexamethylpropyleneamine oxime single-photon emission computed tomography. Regional perfusion abnormalities were identified in multiple locations, particularly in the left frontal lobe. This information was used to direct an open brain biopsy, which led to a diagnosis of Creutzfeldt-Jacob disease.

Creutzfeldt-Jacob disease (CJD) is an uncommon cause of dementia (incidence, about one per 1 million people annually), that remains difficult to diagnose owing to an often atypical presentation and to a lack of definitive imaging or laboratory findings. Computed tomography (CT) and magnetic resonance (MR) studies are often normal in the early stages of the disease or show only cortical atrophy (1). Characteristic EEG findings are features of the later stages of the disease, and are not always present (2). Diagnosis can only be made by open biopsy of the cerebral cortex or by postmortem examination.

Technetium-99m hexamethylpropyleneamine oxime single-photon emission computed tomography (^{99m}Tc-HMPAO SPECT) of the brain has been used in the investigation of a number of brain disorders (3). It has been applied in the evaluation of degenerative dementias, such as Alzheimer disease and Pick disease, and several reports have described its use in patients with CJD (4-8). We present a case of CJD in which initial diagnostic tests were negative except for abnormalities on the ^{99m}Tc-HMPAO SPECT study. Using the SPECT findings as a guide, a biopsy was performed and a diagnostic sample was obtained.

Case Report

A 55-year-old woman was admitted for a rapidly progressive dementia. She had developed vertigo and slight memory difficulty, which progressed to confusion, disorientation, occasional tremors, and mutism. Physical examination revealed an alert woman with a flat affect, oriented to name only, who had difficulty following simple commands. She was unable to recognize or name her children. She had a masked face, intact cranial nerves, and positive glabella and snout frontal release signs. Motor strength, deep tendon reflexes, and gait were normal. Laboratory data included normal serum B₁₂, folate, erythrocyte sedimentation rate, and white blood cell count. Routine blood cultures and an HIV screen were negative, and CSF examination was normal. A noncontrast CT study was normal, as was an MR image of the brain. EEG showed only diffuse slowing bilaterally. An arteriogram revealed a small

aneurysm of the anterior communicating artery, but no evidence of hemorrhage, vasospasm, or vasculitis.

A ^{99m}Tc-SPECT study of the brain revealed a large region of absent perfusion in the anterior left frontal lobe, with diminished perfusion in the posterior right frontal lobe, the left basal ganglia, the left cerebellar hemisphere, and the parietal and occipital lobes bilaterally (Fig 1). Perfusion was relatively normal in most of the right frontal lobe, in the right cerebellum, and in the brain stem. Given the striking abnormalities in the left frontal lobe on the SPECT scans, a decision was made to perform the biopsy there. The specimen revealed spongiform changes with vacuoles, confirming the diagnosis of subacute spongiform encephalitis.

Discussion

The clinical triad of subacute spongiform encephalitis, or CJD, includes dementia, akinetic mutism, and myoclonus (2). The pathogenesis of the disease appears to be a prion or slow virus. It has been shown to be transmissible, usually with a very long latency period. The symptoms are progressive and, at present, there is no effective treatment (2). Classically, the most reliable diagnostic finding is a characteristic, periodic spike-and-wave discharge pattern on EEG (2). It is generally a feature of the middle or late stages, and is not always seen. Although CJD was previously thought of as a global disorder, recent studies using fluorodeoxyglucose F 18 positron emission tomography and SPECT have shown marked regional differences in cerebral blood flow and metabolism, suggesting a heterogeneous pattern of brain involvement (4, 9, 10). Despite the observations of Kovanen et al (1) and Rother et al (11), CT and MR studies are often normal, even in advanced stages of the disease. If abnormal, they may show only cortical atrophy, and are generally most helpful in eliminating focal lesions and hydrocephalus from the differential diagnosis. The diagnosis of CJD continues to depend on findings at brain biopsy.

Investigators have used SPECT with a variety of radionuclides to examine patients with CJD and other CNS disorders (3-7). ^{99m}Tc-HMPAO, a technetium-99m-labeled lipophilic amine analogue, has become widely used for brain imaging. This compound dis-

Received February 12, 1996; accepted after revision March 18, 1997.

From the Department of Radiology, Pennsylvania Hospital, Philadelphia.

Address reprint requests to David A. Miller, MD, Department of Radiology, Emory University Hospital, 1364 Clifton Rd NE, Atlanta, GA 30307.

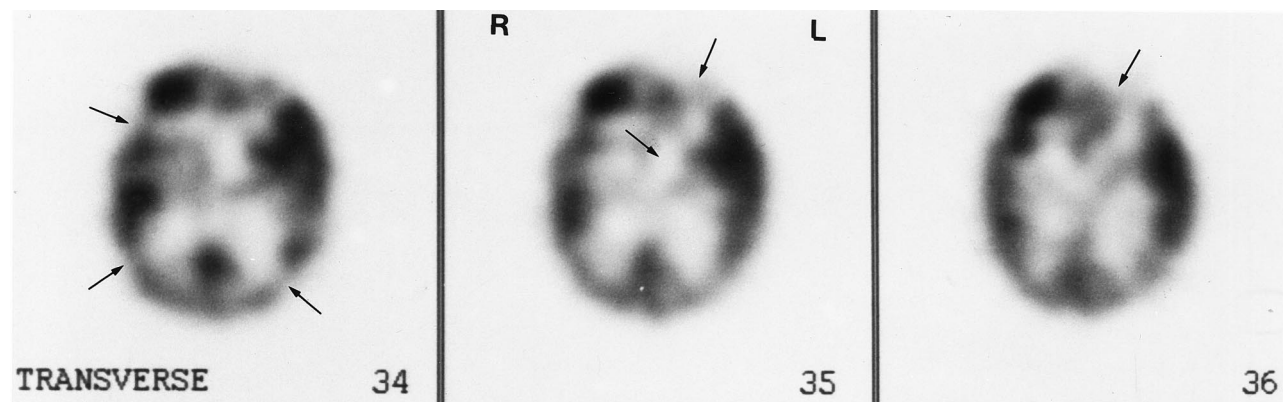


FIG 1. 55-year-old woman with rapidly progressive dementia. Axial views from SPECT brain scan after intravenous administration of 25 mCi (925 MBq) ^{99m}Tc -HMPAO show a region of absent perfusion in the anterior left frontal lobe, with diminished perfusion in the posterior right frontal lobe, the left basal ganglia, and the parietal and occipital lobes bilaterally (arrows). Perfusion is relatively normal in most of the right frontal lobe.

tributes in the brain in proportion to cerebral blood flow. It has several advantages, including a high first-pass extraction fraction, the ability to maintain a regional distribution for several hours, and low cost (6). Focal decreases in the localization of ^{99m}Tc -HMPAO reflect a decrease in regional blood flow, which may indicate focal metabolic dysfunction in the tissues. Some investigators have found ^{99m}Tc -HMPAO SPECT abnormalities in CJD that complement other laboratory findings and that, in some instances, were present when other techniques produced normal findings (5, 6, 12). In fact, as in this case, abnormalities on the SPECT study often occur before changes are seen with CT, MR imaging, or EEG. This suggests that there is a period of altered metabolic activity that precedes neuronal loss, and perhaps even precedes significant alteration in the electrical activity over the cortex. During this period, the blood-brain barrier is apparently intact.

Biopsies to evaluate dementia have traditionally been performed in the nondominant (usually right) frontal lobe, as processes such as CJD have been thought to be generalized and this region has a large area of silent cortex. In fact, CJD can show significant regional variation in SPECT activity and in pathologic changes. Kirk and Ang (10) described a patient with such regional variation in whom abnormalities on SPECT scans correlated with areas of spongiform change and neuronal loss. Intervening areas showed minimal or no spongiform change. This is strong evidence that the heterogeneous pattern of ^{99m}Tc -HMPAO uptake reflects the pattern of brain involvement in this disorder.

Conclusion

Our case illustrates the usefulness of ^{99m}Tc -HMPAO SPECT in the prebiopsy evaluation of CJD. Localized cortical involvement may be identified, and may direct the neurosurgical biopsy.

References

1. Kovanen J, Erkinjuntti T, Iivanainen M, et al. **Cerebral MR and CT imaging in Creutzfeldt-Jakob disease.** *J Comput Assist Tomogr* 1985;9:125-128
2. Adams RD, Victor M. *Principles of Neurology.* 2nd ed. New York, NY: McGraw-Hill; 1981
3. Gemmell HG, Sharp PF, Besson JA, et al. **Differential diagnosis in dementia using the cerebral blood flow agent ^{99m}Tc -HMPAO: a SPECT study.** *J Comput Assist Tomogr* 1985;11:398-402
4. Bonte FJ, Tinter R, Weiner M, Bigio EH, White CL. **Brain blood flow in the dementias: SPECT with histopathologic correlation.** *Radiology* 1993;186:351-365
5. Aharon-Peretz J, Peretz A, Hemli JA, Honigman S, Israel O. **SPECT diagnosis of Creutzfeldt-Jacob disease.** *J Nucl Med* 1986; 27:171-177
6. Cohen D, Krauz Y, Lossos A, Ben-David E, Atlan H. **Brain SPECT imaging with Tc^{99m} HMPAO in Creutzfeldt-Jacob disease.** *J Nucl Med* 1995;36:616-617
7. Kao C, Wang S, Liao S, Yeh S. **Tc^{99m} HMPAO brain SPECT findings in Creutzfeldt-Jacob disease.** *Clin Nucl Med* 1993;18:234-236
8. Goldman S, Laird A, Flament-Durant J, et al. **Positron emission tomography and histopathology in Creutzfeldt-Jacob disease.** *Neurology* 1993;43:1828-1830
9. Graham GD, Petroff OAC, Blamire AM, et al. **Proton magnetic resonance spectroscopy in Creutzfeldt-Jacob disease.** *Neurology* 1993;43:2065-2068
10. Kirk A, Ang LC. **Unilateral Creutzfeldt-Jacob disease presenting as rapidly progressive aphasia.** *Can J Neurol Sci* 1994;21:350-352
11. Rother J, Schwartz A, Harle M, et al. **Magnetic resonance imaging follow up in Creutzfeldt-Jacob disease.** *J Neurol* 1992;239:404-406
12. Hunter R, Gordon A, McLuskie R, et al. **Gross regional hypofunction with normal CT scan in Creutzfeldt-Jacob disease.** *Lancet* 1989;28:214-215