



Discover Generics

Cost-Effective CT & MRI Contrast Agents



WATCH VIDEO

AJNR

Endovascular therapy of idiopathic cavernous aneurysms over 11 years.

G Bavinzski, M Killer, H Ferraz-Leite, A Gruber, C E Gross and B Richling

AJNR Am J Neuroradiol 1998, 19 (3) 559-565

<http://www.ajnr.org/content/19/3/559>

This information is current as of June 5, 2025.

Endovascular Therapy of Idiopathic Cavernous Aneurysms over 11 Years

G. Bavinzski, M. Killer, H. Ferraz-Leite, A. Gruber, C. E. Gross, and B. Richling

PURPOSE: We report our experience with 42 patients with 48 cavernous carotid aneurysms, of whom 32 were treated with endovascular techniques and 10 were managed conservatively.

METHODS: The 48 aneurysms were divided into two subgroups by location: 23 were at the C-3 portion of the carotid artery (small, saccular aneurysms with an epidural, partly intracavernous location) and 25 originated at the C4–5 segment (large or giant often fusiform aneurysms with a true intracavernous location). Morphologic features in both groups correlated well with differences in clinical presentation and also influenced therapy. Sixteen of the 25 C4–5 aneurysms (all large or giant) were treated by balloon occlusion of the parent artery, four (with narrow necks) were treated with Guglielmi detachable coils (GDCs), and five were not treated (asymptomatic or minimally symptomatic). Twelve of 13 C-3 aneurysms were treated with GDCs. Ten C-3 aneurysms were not treated.

RESULTS: Ophthalmoplegia resolved or improved in nine of 12 patients treated with parent artery occlusion. All aneurysms treated by carotid occlusion thrombosed. Twelve of the 17 aneurysms treated with GDCs were 100% filled by the coils, four were 80% to 95% filled, and one was only 40% filled. Seven of the 100% filled aneurysms remained completely occluded, two showed slight coil compaction, and in three, follow-up angiography was not available. Among the incompletely filled aneurysms, two remained unchanged, one showed progressive thrombosis, a fourth revealed coil compaction, and in one, follow-up angiography was not available. One thromboembolic stroke and three transient ischemic attacks occurred perioperatively, for a permanent morbidity of 3.5% and a transient morbidity of 9%. There was no mortality. Mean clinical follow-up was 33 months; mean angiographic follow-up of patients treated with GDCs was 11 months.

CONCLUSION: Surgically difficult cavernous aneurysms can be obliterated by embolization with excellent clinical results. Detachable coils have become an important endovascular tool, especially for narrow-necked cavernous aneurysms of the C-3 segment, which can be protected against rupture in the subarachnoid space in most cases.

Cavernous aneurysms represent 4% of all intracranial aneurysms (1–3). Usually they produce mass effect, presenting with headache or cranial nerve palsy. Large to giant lesions are not uncommon, with a reported prevalence of 60% for all cavernous aneurysms (4–7). They are seldom the underlying cause of subarachnoid hemorrhage, carotid cavernous fistula (CCF), epistaxis, or cerebral embolism (2). Cavernous aneurysms have been associated with trauma,

local radiation treatment, and infections, in addition to iatrogenic and idiopathic causes (1–3, 8).

Ligation of the internal carotid artery (ICA) has long been the therapy of choice for cavernous aneurysms, because direct access was limited by the surrounding cranial nerves and the cavernous sinus (2, 7, 9, 10). In the years since Parkinson and later Dolenc described a direct approach to cavernous aneurysms and CCFs, several authors have reported successful microsurgical treatment of these lesions (1, 5, 7, 10, 11). Concurrently, endovascular techniques evolved so that these lesions could be treated by means of microcatheters and detachable balloons. Selective aneurysmal occlusion or parent artery occlusion with detachable balloons has proved effective in treating some unclippable aneurysms (12–14).

During an 11-year period, we treated 32 patients with cavernous aneurysms by endovascular techniques and managed 10 other patients conservatively.

Received June 18, 1997; accepted after revision October 21.

From the Department of Neurosurgery, University of Vienna (Austria) Medical School (G.B., M.K., H.F.-L., A.G., B.R.) and the Department of Neurosurgery, University of Burlington, Vermont (C.E.G.).

Address reprint requests to G. Bavinzski, MD, Department of Neurosurgery, University of Vienna, Waehringer Guertel 18–20, 1090 Vienna, Austria.

TABLE 1: Summary of 42 patients with 48 cavernous aneurysms

Clinical Presentation	Aneurysmal Location	Treatment
Symptomatic Patients (n = 25)		22 Patients
Ophthalmoplegia (n = 12)	C-4 (n = 12)*	ICCA balloon occlusion (n = 10)*
		GDC (2)
SAH (n = 6)	C-3 (n = 3)	GDC (3)
	C-4 (n = 3)†	ICCA balloon occlusion (n = 3)
CCF (n = 2)	C-4 (n = 2)	ICCA balloon occlusion (n = 2)
TIA (n = 2)	C-4 (n = 2)	ICCA balloon occlusion (n = 1)
		GDC (n = 1)
Headache (n = 3)	C-3 (n = 1)	No treatment (n = 1)
	C-4 (n = 2)	No treatment (n = 2)
Asymptomatic Patients (n = 17)		10 Patients
Coincidental (n = 15)	C-3 (n = 14)*	GDC (n = 8)‡
		No treatment (n = 6)‡
	C-4 (n = 1)	GDC (n = 1)
Incidental (n = 2)	C-3 (n = 1)	GDC (n = 1)
	C-3 (n = 1)‡	No treatment (n = 1)‡

Note: SAH indicates subarachnoid hemorrhage; CCF, carotid-cavernous fistula; TIA, transient ischemic attack; ICCA, intracavernous carotid artery; and GDC, treatment with detachable coils.

* Two patients had bilateral cavernous aneurysms.

† All aneurysms were large or giant and involved the C-3 segment.

‡ One patient had bilateral cavernous aneurysms.

Our earlier management of cavernous aneurysms frequently required sacrificing the carotid artery. Since February 1992, we have used Guglielmi electrolytically detachable coils (GDCs) (Target Therapeutics, Fremont, Calif) at our institution to obliterate 17 cavernous aneurysms, thus allowing preservation of the parent artery (15, 16).

Methods

Between 1985 and 1996, 50 patients with 58 cavernous aneurysms were managed at our institution. All aneurysms were clearly visible at carotid angiography. Preoperative magnetic resonance (MR) images were available in 11 cases. Aneurysms considered to be within the cavernous sinus arose proximal to the ophthalmic artery. Aneurysms that arose distally and extended into the cavernous sinus were excluded, as were four traumatic and six iatrogenic aneurysms (2, 7). An intraaneurysmal thrombus was seen in four of 12 giant cavernous aneurysms. Of the remaining 42 patients with 48 idiopathic lesions, 10 were not treated, as they were either asymptomatic (n = 1), had minimal symptoms (n = 3), or refused therapy (n = 6) (Table 1).

Anatomic and Clinical Considerations

Classically, the C3–5 segment has been defined as the cavernous part of the ICA (Fig 1). However, the classical angiographic definition has to be modified according to the findings of recent anatomic skull-base microdissections (17). The C-3 portion, which is located between two fibrous rings, lies epidurally. Its distal part is usually free of surrounding cavernous veins, especially in the anterior aspect of the carotid siphon knee; sometimes the venous compartments may extend for a variable distance over the C-3 segment (17, 18). Aneurysms arising from C-3 are usually of the small, saccular type, with a greater tendency to rupture in a subarachnoid location than those rising in the C4–5 portion (17–19). The latter are typically large to giant in size, often fusiform, and associated with cranial nerve deficits due to mass effect. This subgroup of C4–5 aneurysms is rarely associated with life-threatening hemorrhage (19). However, patients in both groups may require

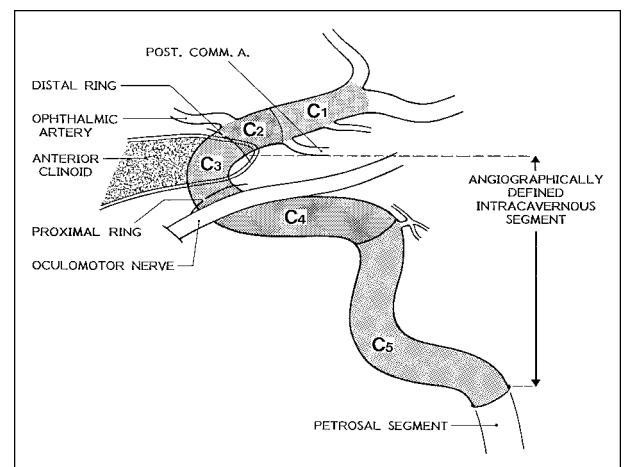


Fig 1. Diagram shows the five intracranial portions of the carotid artery. On the right side the classic angiographic definition of the cavernous carotid segment (C3–5) is delineated. Anatomically, only C4–5 lies intracavernously. The C-3 segment (carotid siphon knee) is located in the epidural space. Its anterior aspect is free of surrounding cavernous veins, whereas at the hollow of C-3, large compartments of the cavernous venous plexus are commonly present (17).

neurosurgical management, which can cause considerable technical problems (17, 18).

Clinical Presentation and Morphologic Features

Twelve patients had deficits involving cranial nerves III to VI, causing ophthalmoplegia, retroorbital pain, and/or facial dysesthesia (Table 1). Six patients had subarachnoid hemorrhage, two had symptomatic CCFs (following rupture of previously demonstrated cavernous aneurysms), two had transient ischemic attacks (TIAs), probably from an embolus arising from the aneurysmal sac, and three patients had headaches without demonstrable hemorrhage or deficits. In 15 patients, the cavernous aneurysm was discovered incidentally during workup for subarachnoid hemorrhage. One patient was found

TABLE 2: Summary of 16 patients with 17 cavernous aneurysms treated with selective GDC embolization

Case	Sex/ Age, y	Presentation	Location	Size/Shape	Complications	Angiographic Result	Clinical Follow-up, mo	Angiographic Follow-up since Last GDC Embolization, mo	Outcome
1	F/60	SAH	L C-3	Giant/saccular	None	85% occlusion	52	Refused	Good, headache
2	F/65	L VI and V CN deficit, decreased visual acuity	L C3-4	Giant/saccular	L TIA	40% occlusion	23	6: 60%	Fair, unchanged
3	F/43	L TIA, amaurosis fugax	L C-4	Small/saccular	None	100% occlusion	16	Lost	Excellent, no symptoms
4	M/42	L VI CN deficit	L C4-5	Large/saccular	None	95% occlusion	29	9: 95%	Good, improved VI CN deficit
5	F/57	Coincidental	B: R+L C-3	B: small/ saccular	None	B: 100% occlusion	30	10: 100%	Excellent, no symptoms
6	M/36	SAH	L C-3	Small/saccular	None	100% occlusion	29	6: 100%	Excellent, no symptoms
7	F/42	Coincidental	L C-3	Small/saccular	None	100% occlusion	15	6: 100%	Good, temporary visual disturbances
8	F/57	Coincidental	L C-3	Small/saccular	None	80% occlusion	27	24: 70%	Excellent, no symptoms
9	F/51	Coincidental	R C-3	Small/saccular	None	100% occlusion	34	16: 100%	Excellent, no symptoms
10	F/48	Coincidental	R C-3	Giant/saccular	None	100% occlusion	36	36: 95%	Good, headache
11	F/35	Coincidental	L C-4	Small/saccular	None	100% occlusion	10	6: 95%	Excellent, no symptoms
12	F/40	Incidental	L C-3	Small/saccular	None	100% occlusion	8	6: 100%	Excellent, no symptoms
13	F/43	Coincidental	R C-3	Small/saccular	None	90% occlusion	4	3: 90%	Excellent, no symptoms
14	F/44	Coincidental	L C-3	Small/saccular	None	100% occlusion	0	Not done	Died of vasospasm
15	F/50	Coincidental	L C-3	Small/saccular	None	100% occlusion	3	3: 100%	Excellent, no symptoms
16	F/48	SAH	L C-3	Small/saccular	None	100% occlusion	0	Not done	Excellent, no symptoms

Note.—SAH indicates subarachnoid hemorrhage; CN, cranial nerve; TIA, transient ischemic attack; GDC, Guglielmi detachable coils; and B, bilateral.

to have bilateral cavernous aneurysms during workup for cervical ICA stenosis, and another was discovered to have an incidental cavernous aneurysm, which was detected on MR images before intracranial surgery.

Patients' ages ranged from 22 to 72 years (mean, 50 years) with a predominance of women (n = 38) over men (n = 4). The time interval between onset of cranial nerve deficit and treatment ranged from 2 weeks to 2 years (mean, 4 months). Owing to special referral patterns, all patients who bled were treated 4 to 6 weeks after the ictus, except one, in whom both the ruptured and the coincidental cavernous aneurysms were treated during the same endovascular procedure. Twelve cavernous aneurysms were giant (>25 mm), seven were large (15 to 25 mm), and 29 were small (<15 mm). Forty-one of the aneurysms were saccular and seven were fusiform in shape. Twenty-three were located at C-3 and 25 at C4–5. Eight of the latter group involved also C-3. Giant cavernous aneurysms tended to involve two or sometimes three carotid artery segments. Twenty-seven aneurysms were on the left side, nine were on the right, and six patients had bilateral lesions. This is consistent with the general rate of occurrence of mirror-image intracranial aneurysms.

Indications for Treatment

Only those patients with progressive cranial nerve deficits, visual symptoms, intractable retroorbital pain, a CCF, recent

subarachnoid hemorrhage, or recurrent TIAs were treated. With the availability of GDCs, patients with small saccular aneurysms found coincidentally or incidentally were offered the endovascular option.

Endovascular Therapy

Sixteen patients underwent carotid artery balloon occlusion at the level of the lesion; three of them needed an additional extracranial (EC-IC) bypass. All aneurysms that required sacrificing of the carotid artery arose from C4–5. One patient required surgical trapping after a failed attempt at balloon occlusion of a high-flow CCF. One patient with a giant cavernous aneurysm had had a previous attempt at transcavernous aneurysmorrhaphy; she was subsequently treated with cavernous carotid artery balloon occlusion, because of refilling of the aneurysm after surgery. Sixteen patients (one with bilateral lesions) were treated with the GDCs, preserving the carotid artery (see Table 2).

Internal Carotid Balloon Occlusion.—In 13 patients the involved ICA was catheterized via a transfemoral route under local anesthesia with a 7.3F angiography catheter (4, 8). A 2F microcatheter armed with a detachable balloon (ITC, South San Francisco, Calif; Ingenor, Paris, France) was then advanced through a guide catheter to the intracavernous carotid artery, which was occluded by balloon inflation. In three patients the ICA was punctured under local anesthesia with a

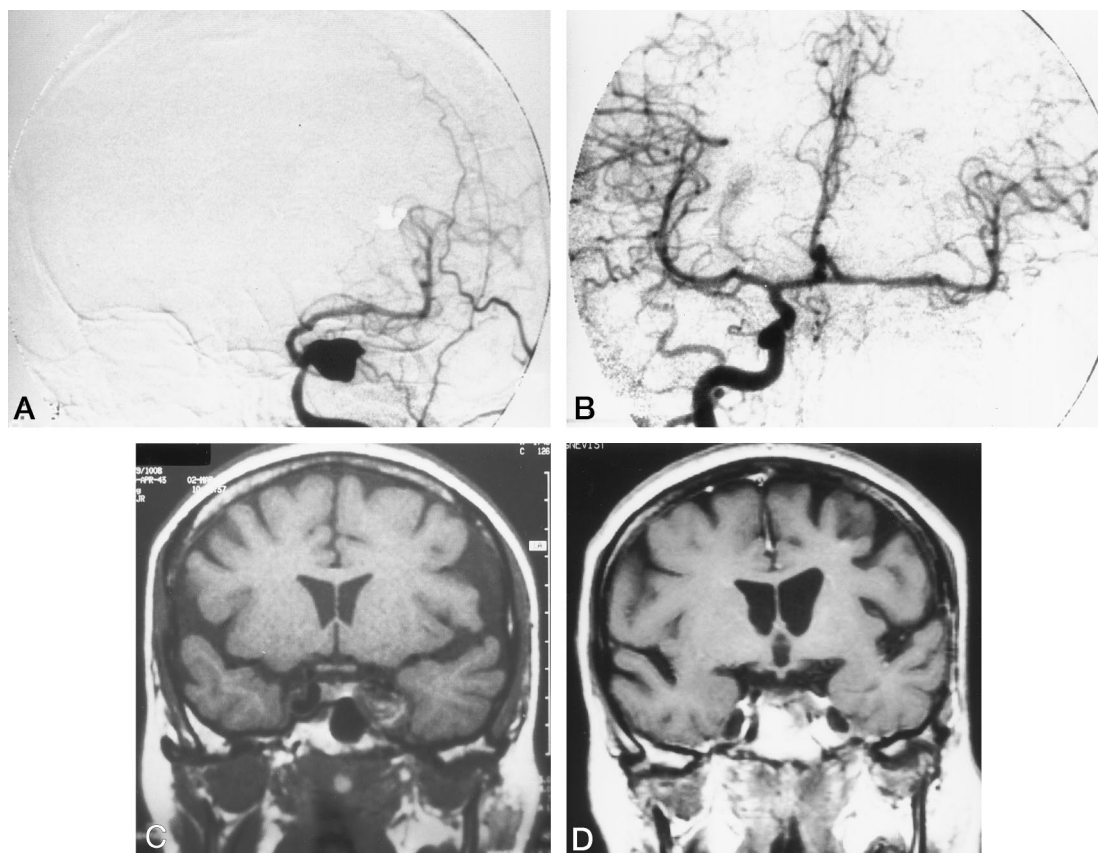


FIG 2. Left-sided cavernous aneurysm without a clearly definable neck presenting with palsy of cranial nerves III to VI. A, Left ICA angiogram, anteroposterior view. B, Right common carotid artery injection shows sufficient cross flow to the left hemisphere after ICA balloon occlusion. C, MR image shows extent of the lesion before treatment. D, MR image shows complete thrombosis of the aneurysm 1 year after ICA occlusion, with resolution of symptoms.

12-gauge cathlon needle (Critikon®, Chatenay-Malabry, France) through which the balloon was navigated to the aneurysm (3, 4, 6, 12–14, 20).

During test occlusion, a bolus of 5000 IU of heparin was injected into the occluded ICA stump. During 40-minute ICA balloon test occlusion, serial neurologic examinations were performed on the awake patient and cerebrovascular reserve capacity was challenged by lowering the mean arterial pressure 20 mm Hg below the patient's normal range (3, 4, 13). If no neurologic deficit developed, the balloon was deflated and refilled with fibrin glue. After hardening of the fibrin, the balloon was detached (21). Intraoperative heparin was not reversed postoperatively. Angiographic cross-flow studies were performed via a 5F catheter positioned in the contralateral common carotid artery or dominant vertebral artery (Fig 2).

In addition to angiographic cross-flow studies, collateral circulation was defined as sufficient if symmetric filling of both hemispheres occurred in arterial, parenchymatous, and venous phases (3, 4, 6, 13).

Selective GDC Embolization.—Since February 1992 we have used GDCs at our institution for endosaccular occlusion of cavernous aneurysms. All aneurysms were embolized via a modified microcatheter (Tracker 10 or 18, Target Therapeutics) transfemorally. The current technique has been reported previously in detail; for further information about coil mechanics and the biophysical details, we refer the reader to these other reports (15, 16). Briefly, GDCs are coils made of finely wound platinum, soldered to a stainless steel wire, and introduced through a microcatheter. They are designed to have a conformational memory and can be detached from the delivery wire by applying 1 to 3 mA of direct electric current (15, 16).

During the procedure, a bolus of 5000 IU of heparin was administered in addition to an IV infusion (starting with 10 IU/kg per hour and titrating to a doubling of the partial thromboplastin time). Control angiography was done immediately after coil placement and at 3- to 6-month intervals thereafter for 2 years. One procedure was sufficient in 14 patients and two procedures were necessary in two patients. Perioperative heparinization was maintained for 4 days.

Results

Cranial nerve deficits resolved or improved in eight of 10 patients after ICA occlusion. In two patients, an ophthalmoplegia persisted despite proved ICA and aneurysmal thrombosis on MR studies (one patient had had a previous attempt at transcavernous repair and in the other we assume damage to the vasa nervorum was caused by an expanding intraaneurysmal thrombus).

Of those treated with GDCs, one patient had marked improvement of a palsy in the abducens nerve after 90% occlusion of a large cavernous aneurysm with GDCs. In another patient, in whom 40% obliteration of the aneurysm was achieved, no change was seen in a palsy of cranial nerve VI. In this case, ICA balloon occlusion was not possible, because endovascular access was too difficult (see Table 2). Follow-up time ranged from 3 months to 10 years (mean, 33

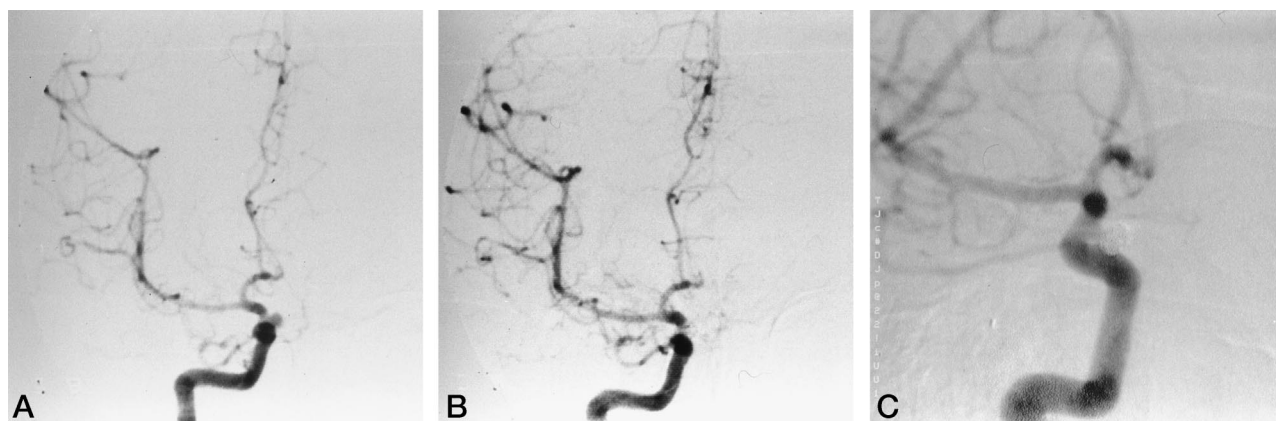


FIG 3. Small C-3 cavernous aneurysm on the right side, which ruptured into the subarachnoid space.

A, Right ICA angiogram, anteroposterior view, before treatment.

B, Right ICA angiogram after treatment with GDCs.

C, Right ICA angiogram, oblique view, 16 months after treatment.

months). Angiographic follow-up of patients who were treated with GDCs ranged from 3 to 36 months (mean, 11 months).

No early or late rehemorrhage was observed after treatment. In two patients, a CCF was completely resolved and in two other patients no further TIAs occurred. One patient died of myocardial infarction 2 years after treatment. Those patients managed conservatively remained clinically unchanged on follow-up examinations. In one patient, enlargement of a cavernous aneurysm was noted on a follow-up study, but he refused further treatment.

All 16 cavernous aneurysms treated by balloon occlusion showed complete thrombosis on follow-up MR studies. Complete aneurysmal occlusion with GDCs was achieved in 12 of 17 coiled aneurysms (Fig 2). In four aneurysms, an 80% to 95% obliteration was achieved, and in one patient only 40% of the aneurysm was obliterated with the coils (Table 2). Seven of 12 aneurysms that were completely filled with coils remained so on follow-up; however, two showed coil compaction and were classified as 95% occluded. Follow-up studies were not available in three patients (one was lost to follow-up, another died of vasospasm after rupture of a coincidental aneurysm, and the third was treated too recently to have follow-up angiography available). In the group of patients in whom aneurysms were incompletely coiled, two remained unchanged, one showed coil compaction, and a fourth refused follow-up angiography. In the patient in whom a 40% occlusion was achieved, a 60% obliteration of the aneurysmal lumen was seen on a follow-up angiogram.

Complications occurred in four patients. One patient suffered a thromboembolic stroke after balloon occlusion and surgical trapping of a large CCF, which was caused by rupture of a known cavernous aneurysm (Fig 3). This complication resulted in permanent, moderate hemiparesis (permanent morbidity of 3.5%). Postoperative TIAs were seen in two patients after ICA balloon occlusion and in another after GDC treatment (transient morbidity of 9%). In all

three patients, symptoms reversed after induction of hypervolemic hemodilution and full anticoagulation.

Discussion

Cavernous aneurysms still represent a challenge for most neurovascular surgeons (1, 5, 7, 9, 12, 22–24). Owing to its intimate relationship with four cranial nerves inside the cavernous sinus, the intracavernous carotid artery has not been amenable to direct surgical intervention in most hands. ICA ligation in the neck, with or without trapping, sometimes in combination with an EC-IC bypass, has been the treatment method of choice for most surgeons (1, 9, 22, 24, 25). Dolenc et al (1) applied modern microsurgical techniques to cavernous aneurysms. Recent series in which the direct surgical approach was used have shown combined morbidity/mortality rates of 14% to 25% (1, 5, 10, 11). Over the same time frame, neurovascular interventional techniques were being developed. After Serbinenko's pioneering work, the number of successful reports on intravascular treatment of cerebral aneurysms steadily increased; for the most part, detachable microballoons were used to occlude parent arteries (3, 6, 12, 14, 20, 26). Large series of cavernous aneurysms treated with balloon occlusion reported mortality rates of 0% to 1.7%. Permanent morbidity ranged from 2.7% to 6.6%, which is significantly less than that reported for open surgical treatment of these lesions (3, 6, 9, 13, 14).

Our therapeutic strategy for cavernous aneurysms has similarly been modified during an 11-year period. For ruptured and unruptured C-3 aneurysms with clippable necks, surgery was usually attempted, followed by carotid balloon occlusion if clipping was not possible (11). Small asymptomatic C-4 aneurysms without subarachnoid extension were managed conservatively, as their natural course can be quite benign (2, 18, 19). Large asymptomatic lesions arising from C-4 with subarachnoid extension and symptomatic C-4 aneurysms were treated by parent artery balloon occlusion. In accordance with other authors' experi-

ence, we generally saw better results with ICA balloon occlusion than with endosaccular therapy (3, 6, 9, 14). In the literature, complications have been reported predominantly in those cases in which preservation of the carotid was attempted. These complications were caused mostly by emboli that were dislodged by the balloon entering the aneurysm (3, 12, 14, 20). In our experience, endosaccular balloon occlusion of aneurysms is feasible only in a minority of large cavernous C-4 aneurysms, specifically those with narrow necks. Most large to giant cavernous aneurysms have separate inflow and outflow tracts without a definable neck, or they are too broad-based for endosaccular occlusion (1, 3, 6, 9, 12, 14, 20).

On the other hand, about 80% of patients tolerate abrupt ICA ligation without incurring neurologic symptoms (3, 4, 9, 14, 22, 24, 27). To detect those patients whose ICA cannot be sacrificed, we rely on a clinical balloon test occlusion, during which neurologic function is assessed directly in the awake patient (3, 4, 8, 9, 12, 14, 20). During the test, it is important to challenge the cerebrovascular reserve capacity by lowering the mean blood pressure 20 mm Hg below the normal range (4, 8, 14). In one of our cases, we were not able to lower the blood pressure and the patient suffered a TIA after permanent parent artery occlusion, but this resolved rapidly upon induction of a hyperdynamic state. Currently, we are combining the balloon test occlusion with stable xenon blood flow measurements for quantitative CBF assessment (27). Patients in whom the balloon test occlusion fails initially should be retested after undergoing an EC-IC bypass (8, 22, 23, 25). In our series, all those in whom the test occlusion failed initially tolerated ICA occlusion after the revascularization procedure (22, 25). Although not encountered in this series, a few patients will show neurologic signs during the balloon test occlusion despite a functioning bypass (8, 23, 25, 28). Here, a high-flow vein conduit is indicated (5, 23, 28). However, this procedure needs about 90 minutes of temporary ICA occlusion, although intraoperative hyperdynamics and barbiturate brain protection have been reported to lower the risk of intraoperative ischemic injury (23, 28). In accordance with Drake et al (9), we believe that the risk of an intracavernous bypass is rarely indicated in light of the effectiveness of simple carotid occlusion in the majority of cases (3, 4, 9, 13, 14, 20).

The major arguments against carotid ligation are the theoretically increased risk of ischemic cerebral events on the occluded side and/or the development of de novo aneurysms in the remaining vessels, both of which have been reported (23). The results of our recent hemodynamic studies using single-photon emission computed tomography argue against the initial concern. There has been no marked decrease in cerebrovascular reserve capacity in patients who had therapeutic ICA occlusion 2 or 3 decades ago (unpublished data). Furthermore, new aneurysmal formation in the remaining vessels was not seen after ICA occlusion in our series (unpublished data).

The availability of GDCs since February 1992 has

had a major influence on our management of cavernous aneurysms. Advantages of the coils over detachable balloons in the selective treatment of aneurysms include easy applicability, maneuverability, and retrievability. Additionally, the coils conform to the aneurysmal shape and exert less trauma on vascular walls (15, 16, 29). The electrical detachment strategy is easier and less risky, since there is little associated mechanical stress. A drawback of GDCs in the treatment of cerebral aneurysms is the tendency of the coils to compact, resulting in reperfusion of the aneurysmal base, especially in wide-necked lesions (15, 29). This is less a problem in narrow-necked variants. On the other hand, the dome, from which the aneurysm ruptures in 98% of cases, can be occluded almost every time (15, 29). Furthermore, many of those cavernous aneurysms that are most likely to rupture into the subarachnoid space are located at the C-3 segment. They are usually small, enlargement being contained by the sphenoid bone medially in addition to strong surrounding connective tissue strands. The surrounding structures also provide a certain degree of protection to the aneurysmal neck (1, 11). Thirteen of 17 coiled cavernous aneurysms were located at the C-3 portion of the cavernous carotid artery. A 100% occlusion could be achieved in 10 of the 13 and an 80% to 90% occlusion in the other three. Because the narrow neck holds the balloon or coil in the desired position, the C-3 cavernous aneurysms showed the most angiographically stable result on follow-up studies (15). In this series, only one of the completely coiled C-3 aneurysms showed coil compaction on follow-up angiograms; the rest showed a stable angiographic result. In contrast, there were only two aneurysms located at the C-4 portion that had the narrow-neck profile necessary to achieve optimal positioning of a balloon or coils (1, 4, 7). Despite the fact that one of our patients with a C-4 aneurysm treated with GDCs had marked improvement in his abducens palsy, we are not convinced that coiling should be the first choice for large cavernous aneurysms, especially if one suspects that the neurologic symptoms are due to mass effect (16, 30). Halbach et al (30), on the other hand, reported a 90% rate of symptomatic improvement when endosaccular balloon or coil embolization was performed. The report by Litovsky et al (16) of progressive visual loss after GDC treatment of a giant supraclinoid ICA aneurysm gives us pause in this situation.

Conclusion

Small, narrow-necked cavernous aneurysms of the C-3 segment, which are difficult to reach surgically, can be obliterated by GDCs in many cases; for this subgroup of aneurysms, a stable angiographic result can be expected (15). In contrast, those located at C4-5 are mostly large to giant in size and involve adjacent cavernous ICA segments. They often have separate inflow and outflow tracts without a definable neck or are too broad-based for selective occlusion. They can be obliterated by ICA balloon occlusion at

or just proximal to the lesion. Eighty percent of patients will tolerate this without incurring a neurologic deficit (3, 4, 8, 9, 12, 14, 20, 27). The other 20% are handled with an EC-IC bypass. Only rarely a high-flow saphenous vein graft conduit or a short skull-base bypass is indicated (8, 9, 23, 25, 27, 28). A small percentage of cavernous aneurysms located at C-4 or C-5 have small necks at the time of presentation. They can be treated with GDCs; but despite good preliminary clinical results, the long-term efficacy of endosaccular occlusion with space-occupying coils has yet to be established. Extended angiographic follow-up studies, which are not available at this time, are necessary if we are to assess the long-term stability of the coils (15, 29).

References

- Dolenc V, Clerk M, Sustersic J, Pregelj R, Skrap M. **Treatment of intracavernous aneurysms of the ICA and CCFs by direct approach.** In: Dolenc VV, ed. *The Cavernous Sinus: A Multidisciplinary Approach to Vascular and Tumorous Lesions*. New York, NY: Springer; 1987:297-310
- Linskey M, Shekhar L, Hirsch W, Yonas H, Horton J. **Aneurysms of the intracavernous carotid artery: natural history and indications for treatment.** *Neurosurgery* 1990;26:933-938
- Picard L, Moret J, Bracard Z, et al. **Diagnostic neuroradiologique des malformations vasculaires crânio-encéphaliques.** *Encyc Médico-Chir (Paris)* 1989;16-17
- Anon V, Aymard A, Gobin Y, et al. **Balloon occlusion of the internal carotid artery in 40 cases of giant intracavernous aneurysm: technical aspects, cerebral monitoring, and results.** *Neuroradiology* 1992;34:245-251
- Diaz F, Ohaegbulam S, Dujovny M, Ausmann J. **Surgical management of aneurysms in the cavernous sinus.** *Acta Neurochir* 1988;91:25-28
- Higashida R, Halbach V, Dowd C, et al. **Endovascular detachable balloon embolization therapy of cavernous carotid artery aneurysms: results in 87 cases.** *J Neurosurg* 1990;72:857-863
- Linskey M, Shekhar L, Horton J, Hirsch W, Yonas H. **Aneurysms of the intracavernous carotid artery: a multidisciplinary approach to treatment.** *J Neurosurg* 1991;75:525-534
- Bavinzski G, Killer M, Knosp E, Ferraz-Leite H, Gruber A, Richling B. **False aneurysms of the intracavernous carotid artery.** *Acta Neurochir* 1997;139:37-43
- Drake C, Peerless S, Ferguson G. **Hunterian proximal arterial occlusion for giant aneurysms of the carotid circulation.** *J Neurosurg* 1994;81:656-665
- Fukushima T, Day J, Tung H. **Intracavernous carotid aneurysms.** In: Apuzzo M, ed. *Brain Surgery: Complication Avoidance and Management*. New York, NY: Churchill Livingstone; 1993:925-944
- Pernecky A, Knosp E, Vorkapic P, Czech T. **Direct surgical approach to infraclinoidal aneurysms.** *Acta Neurochir* 1985;76:36-44
- Debrun G, Fox A, Drake C, Peerless S, Girvin J, Ferguson G. **Giant unclippable aneurysms: treatment with detachable balloons.** *AJNR Am J Neuroradiol* 1981;2:167-173
- Niimi Y, Berenstein A, Setton A, Kupersmith MJ. **Occlusion of the internal carotid artery based on a simple tolerance test.** *Intervent Neuroradiol* 1996;2:289-296
- Fox AJ, Vinuela F, Pelz D, et al. **Use of detachable balloons for proximal artery occlusion in the treatment of unclippable cerebral aneurysms.** *J Neurosurg* 1987;66:40-46
- Richling B, Gruber A, Bavinzski G, Killer M. **GDC-system embolization for brain aneurysms: location and follow up.** *Acta Neurochir* 1995;134:177-183
- Litofsky NS, Vinuela F, Giannotta SL. **Progressive visual loss after electrothrombosis treatment of giant intracranial aneurysm: case report.** *Neurosurgery* 1994;34:548-551
- Knosp E, Müller G, Perneczky A. **The paraclinoid carotid artery: anatomical aspects of a microneurosurgical approach.** *Neurosurgery* 1988;22:896-901
- Linskey ME, Sekhar LN. **Which cavernous aneurysms should be treated?** *J Neurosurg* 1993;78:1008-1009
- Kupersmith MH, Hurst R, Berenstein A, Choi IS, Jafar J, Ransohoff J. **The benign course of cavernous carotid artery aneurysms.** *J Neurosurg* 1992;77:690-693
- Berenstein A, Ransohoff J, Kupersmith M, Flamm E, Graeb D. **Transvascular treatment of giant aneurysms of the cavernous carotid and vertebral arteries.** *Surg Neurol* 1984;21:3-12
- Richling B. **Homologous controlled viscosity fibrin for endovascular embolization: I, experimental development of the medium.** *Acta Neurochir* 1984;64:109-124
- Gelber B, Sundt TM. **Treatment of intracavernous and giant carotid aneurysms by combined internal carotid ligation and extra-intracranial bypass.** *J Neurosurg* 1980;52:1-10
- Lawton M, Hamilton M, Morcos J, Spetzler R. **Revascularization and aneurysm surgery: current techniques, indications and outcome.** *Neurosurgery* 1996;38:83-93
- Little JR, Rosenfeld J, Awad I. **Internal carotid artery occlusion for cavernous segment aneurysm.** *Neurosurgery* 1989;25:3:398-404
- Spetzler RF, Schuster H, Roski R. **Elective extracranial-intracranial arterial bypass in the treatment of inoperable giant aneurysms of the internal carotid artery.** *J Neurosurg* 1980;53:22-27
- Serbinenko FA. **Balloon catheterization and occlusion of major cerebral vessels.** *J Neurosurg* 1974;41:125-145
- Erba S, Horton J, Latchaw R, et al. **Balloon test occlusion of the internal carotid artery with stable xenon-CT cerebral blood flow imaging.** *AJNR Am J Neuroradiol* 1988;9:533-538
- Sen C, Shekar L. **Direct vein graft reconstruction of the cavernous, petrous, and upper cervical internal carotid artery: lessons learned from 30 cases.** *Neurosurgery* 1992;30:732-743
- Zubillaga AF, Guglielmi G, Vinuela F, Duckwiler GR. **Endovascular occlusion of intracranial aneurysms with electrolytically detachable coils: correlation of aneurysm neck size and treatment results.** *AJNR Am J Neuroradiol* 1994;15:815-820
- Halbach V, Higashida R, Dowd C, et al. **The efficacy of endosaccular aneurysm occlusion in alleviating neurological deficits produced by mass effect.** *J Neurosurg* 1994;80:659-666