



Discover Generics

Cost-Effective CT & MRI Contrast Agents



WATCH VIDEO

AJNR

Predicting hemodynamic ischemia by transcranial Doppler monitoring during therapeutic balloon occlusion of the internal carotid artery.

B Eckert, A Thie, M Carvajal, C Groden and H Zeumer

This information is current as of June 5, 2025.

AJNR Am J Neuroradiol 1998, 19 (3) 577-582

<http://www.ajnr.org/content/19/3/577>

Predicting Hemodynamic Ischemia by Transcranial Doppler Monitoring during Therapeutic Balloon Occlusion of the Internal Carotid Artery

B. Eckert, A. Thie, M. Carvajal, C. Groden, and H. Zeumer

PURPOSE: Our objective was to evaluate the sensitivity of transcranial Doppler (TCD) sonographic monitoring during permanent balloon occlusion of the internal carotid artery (ICA) in predicting hemodynamic ischemia.

METHODS: Thirty-two consecutive patients underwent controlled therapeutic balloon occlusion of the ICA. Selection criteria included assessment of the circle of Willis by compression angiography, clinical tolerance during a 20-minute test occlusion, and TCD monitoring of the ipsilateral middle cerebral artery. The mean blood flow velocity (MBFV) ($n = 32$) and pulsatility index (PI) ($n = 28$) were recorded. In 25 patients, MBFV changes upon motor stimulation were recorded before and after ICA occlusion.

RESULTS: Twenty-eight (88%) of the patients had no complications. Three patients suffered delayed symptoms 30 minutes to 20 hours after balloon detachment. Two of these patients recovered spontaneously within 1 day, the other improved after extracranial/intracranial (EC/IC) bypass surgery. One patient, who did not tolerate the test occlusion, suffered a hemodynamic stroke despite EC/IC bypass before permanent balloon occlusion. No embolic complications occurred. The mean MBFV reduction was 20% (range, 0% to 55%); the mean PI reduction was 20% (range, 0% to 56%). No complications occurred in patients who had mild MBFV and PI reduction (30% or less, $n = 21$). All three patients with severe MBFV or PI reduction ($> 50\%$) had neurologic symptoms. Among those with moderate MBFV or PI reduction (30% to 50%, $n = 8$), symptoms developed in only one patient who had moderate reduction of both MBFV (33%) and PI (38%). Motor vasoreactivity showed wide variation and was markedly reduced in two symptomatic patients.

CONCLUSION: TCD monitoring reflects changes in cerebral hemodynamics after therapeutic balloon occlusion of the ICA. MBFV and PI reductions under 30% are highly predictive of clinical tolerance. A reduction of more than 50% may be a critical threshold for the occurrence of symptoms; in such cases, EC/IC bypass should be considered before proceeding with permanent balloon occlusion.

Balloon occlusion of the internal carotid artery (ICA) has become an accepted therapeutic method for treatment of inoperable giant aneurysms of the ICA and as a last-resort treatment of extensive carotid cavernous fistulas (1–4). Preoperative balloon occlusion is also performed in some patients with extensive skull-base tumors. ICA occlusion, however, may lead

to hemodynamic ischemia, symptoms of which can occur within hours or up to several days after the procedure, even if a temporary (test) balloon occlusion has been clinically tolerated. In this prospective study, we evaluated the practicality and applicability of using transcranial Doppler sonographic (TCD) monitoring of blood flow velocity in predicting hemodynamic intolerance after permanent balloon occlusion of the ICA.

Methods

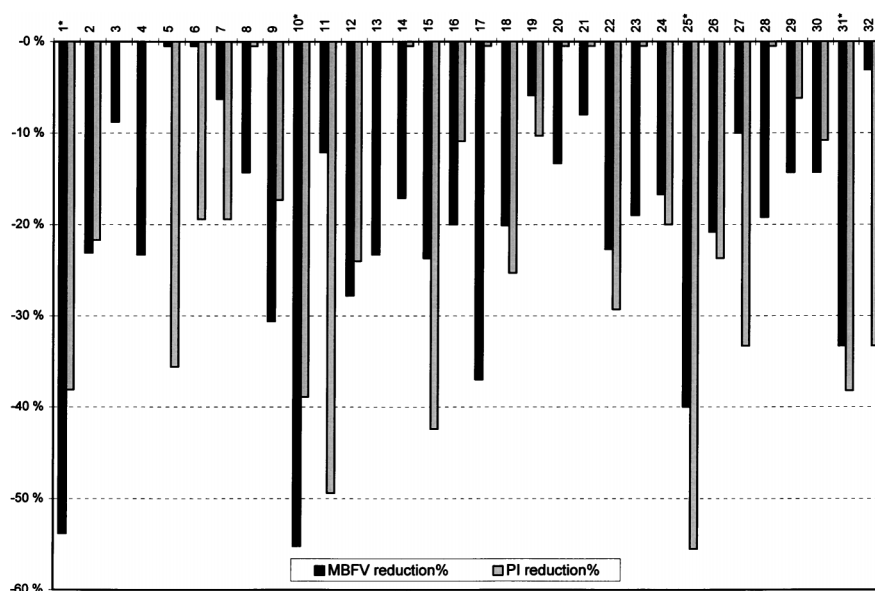
Patients

Thirty-two consecutive patients (19 female, 13 male; mean age, 45 years; range, 10 to 70 years) underwent therapeutic balloon occlusion. The decision to attempt permanent balloon

Received February 21, 1997; accepted after revision August 18.
From the Departments of Neuroradiology (B.E., C.G., H.Z.) and Neurology (A.T., M.C.), University Hospital of Hamburg (Germany).

Address reprint requests to Dr Bernd Eckert, Universitätskrankenhaus Hamburg-Eppendorf, Abteilung für Neuroradiologie, Martinistr 52, D-20246 Hamburg, Germany.

FIG 1. MBFV and PI reduction in the ipsilateral middle cerebral artery after therapeutic balloon occlusion of the ICA. Patients marked with an asterisk (cases 1, 10, 25, and 31) did not tolerate the procedure (see Table).



occlusion was based on clinical and angiographic findings only; TCD results did not influence the determination. Indications for therapeutic balloon occlusion of the ICA included skull base tumors ($n = 17$), giant aneurysms of the ICA ($n = 13$), and carotid cavernous fistulas ($n = 2$). The right ICA was occluded in 11 patients, the left in 21 patients.

Technique

In three children (ages 10 to 15 years), balloon occlusion was performed under general anesthesia. In all other patients the procedure was performed under local anesthesia. The intervention was effected via femoral approach and was preceded by four-vessel angiography, including a common carotid artery (CCA) compression test to determine patency of the anterior and posterior communicating artery. A 7F introducer catheter was placed through the femoral artery sheath into the origin of the ICA. The catheter system was flushed with heparinized isotonic sodium chloride solution (2500 U heparin in 500 mL sodium chloride) at 200 mL/h throughout the procedure, and a bolus of 5000 U heparin was administered before the balloon was inserted.

Under fluoroscopic control, a detachable silicone balloon (maximum volume, 0.5 mL; Interventional Therapeutics Corp, South San Francisco, Calif) on an extended Tracker 18 infusion microcatheter (Target Therapeutics, Fremont, Calif) was navigated through the introducer catheter into the ICA at a level just below the origin of the ophthalmic artery. The balloon was then inflated with contrast material to effect occlusion. Once the balloon was inflated, neurologic status was assessed by a neurologist every 5 minutes during the 20-minute test occlusion. TCD parameters and motor vasoreactivity were measured twice during this period. If the test occlusion was not clinically tolerated, the balloon was deflated and removed. If no complications occurred, the balloon was detached and a second latex balloon (maximum volume, 0.8 mL; Nycomed, Paris, France) attached to a minitorquer catheter with a Teflon tip (Nycomed) was placed just below it. (Both silicone and latex balloons are approved for use in Europe.) This combination was chosen because of the desired thrombogenic effect of the latex balloon and the safety of the silicone balloon. The silicone balloon was used as the primary occluding balloon. At the end of the procedure, control angiography in the ipsilateral CCA was performed to document complete ICA blockage. In some cases of difficult ICA aneurysms, control angiography included catheterization of the posterior circulation and the contralateral

ICA to detect possible filling of the aneurysm via the circle of Willis.

Following removal of the catheter system, the patient was kept supine for 1 day. Gradual ambulation was begun thereafter for 3 days, during which blood pressure was closely monitored. Mean arterial pressure was kept above 100 mm Hg, and low-dose heparin was administered throughout this period.

TCD Monitoring

TCD monitoring was performed with an EME TC 2/64 (Eden Medical Electronics, Überlingen, Germany), which is a range-gated pulsed-wave Doppler device with a 2-MHz transducer. After angiographic assessment and prior to the balloon catheter procedure, the TCD probe was positioned with a custom-made headband that assured the same position throughout the procedure. The ipsilateral middle cerebral artery was insonated at a depth of 45 to 55 mm. Correct position of the Doppler probe was also verified by detection of the typical signals produced by a shower of micro air bubbles during injection of radiographic contrast material into the ipsilateral CCA (5). It was also important to find a Doppler probe position that did not impede fluoroscopic control during the procedure, especially of the carotid siphon.

The mean blood flow velocity (MBFV; time-averaged peak frequencies of the envelope curve of Doppler spectra) and the pulsatility index (PI; systolic minus diastolic velocity divided by MBFV) (6), calculated online every 7 seconds, were recorded. In addition, changes in MBFV due to contralateral motor activation, called motor vasoreactivity, were recorded. The percentage of maximal MBFV increase relative to baseline values through intermittent fist clenching and sequential finger movements before and after ICA occlusion was calculated (7, 8). MBFV, PI, and motor vasoreactivity tests lasting 1 minute were performed just before and 10 minutes after balloon inflation under steady-state conditions during the test occlusion period. Statistical analysis of MBFV, PI, and motor vasoreactivity values were by means of the exact Cochran-Armitage test.

Results

TCD Results

MBFV decreased from a mean of 58 cm/s (range, 20 to 94 cm/s) to 47 cm/s (range, 18 to 78 cm/s), a general reduction of 20% ($n = 32$; range, 0% to 55%)

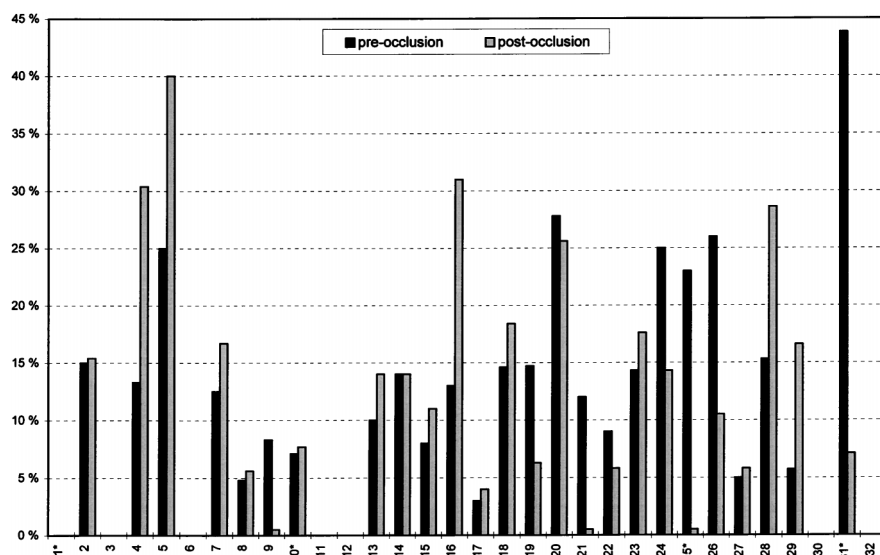


Fig 2. Motor vasoreactivity upon intermittent fist clenching and sequential finger movements before and after ICA occlusion. Percentage of maximal increase of MBFV relative to baseline values was calculated in 25 patients. Patients marked with an *asterisk* (cases 1, 10, 25, and 31) did not tolerate the procedure (see Table). Motor vasoreactivity varied considerably; in two symptomatic patients (25 and 31) it was markedly reduced after balloon occlusion.

(Fig 1). PI decreased from a mean of 0.82 (range, 0.58 to 1.10) before the procedure to 0.67 (range, 0.39 to 1.30) after the procedure, a mean reduction of 20% ($n = 28$; range, 0% to 56%) (Fig 1).

Mean values for motor vasoreactivity did not change significantly. Prior to balloon occlusion, the mean MBFV increased 15% after motor stimulation (range, 3% to 44%); after balloon occlusion, MBFV increased 14% (range, 0% to 40%). The difference between pre- and postocclusion vasoreactivity showed considerable interpersonal variation (Fig 2). In 15 patients, motor vasoreactivity improved after ICA occlusion. It did not change in one patient and was mildly decreased in seven patients. A marked reduction was seen in two patients (cases 25 and 31; Fig 2).

Some patients had delayed adaptation of the blood flow velocity parameters (Fig 3). A continuous MBFV and PI increase could be observed over a period of several minutes. Only MBFV and PI measured in a steady-state situation were evaluated, since the initial MBFV and PI drop could have led to an overestimation of the decrease.

Complications

The clinical complications after balloon occlusion are summarized in the Table. One patient (case 25) suffered a subtle motor dysphasia and mild right hemiparesis immediately after balloon inflation. MBFV and PI reduction were 40% and 56%, respectively. Motor vasoreactivity was reduced from 23% before balloon occlusion to 0% after. Delayed adaptation over the 10-minute observation period did not occur. After balloon deflation, the patient recovered completely within 1 minute. The balloon was removed, and the next week an EC/IC bypass was performed followed by a balloon test occlusion within an hour. Despite angiographic evidence of bypass function, TCD values did not change. The patient exhibited the same symptoms as before the bypass procedure. The urgency of the ICA sacrifice before surgery

for an extensive skull base tumor and the relatively mild neurologic symptoms supported the decision to detach the balloon. But even after several days, flow velocity did not improve, and the patient did not recover. A computed tomography (CT) scan revealed hemodynamic infarction in the subcortical white matter and in the dorsal border zone region. Surgery was then postponed to await neurologic improvement.

Three patients suffered delayed neurologic symptoms, 30 minutes, 90 minutes, and 20 hours, respectively, after balloon detachment. Two of these (cases 1 and 10) recovered within 1 hour after volume expansion and induced hypertension, suggesting a hemodynamic cause of the symptoms. A control CT scan did not show any structural deficit. The third patient (case 31) developed a mild contralateral hemiparesis and sensorimotor dysphasia, starting 20 hours after balloon detachment. Despite volume expansion and induced hypertension, symptoms did not improve over the next 3 days, so an EC/IC bypass was performed, after which the patient recovered completely, including restoration of motor vasoreactivity, which had been markedly reduced after balloon occlusion (44% before and 7% after the procedure). No thromboembolic complications were observed.

Data Analysis

MBFV and PI decreases were classified as mild (group 1, MBFV and PI reduction of 30% or less, $n = 21$); moderate (group 2, MBFV or PI reduction between 30% and 50%, $n = 8$); or severe (group 3, MBFV or PI reduction of more than 50%, $n = 3$).

No patient in group 1 had complications. All patients in group 3 developed neurologic symptoms. Explorative data analysis using the exact Cochran-Armitage test revealed a significant increase of risk for the occurrence of symptoms in group 3 ($P < .005$). Patients in group 1 showed a significantly reduced risk of symptom occurrence ($P < .005$). Among the eight patients in group 2, seven showed either an

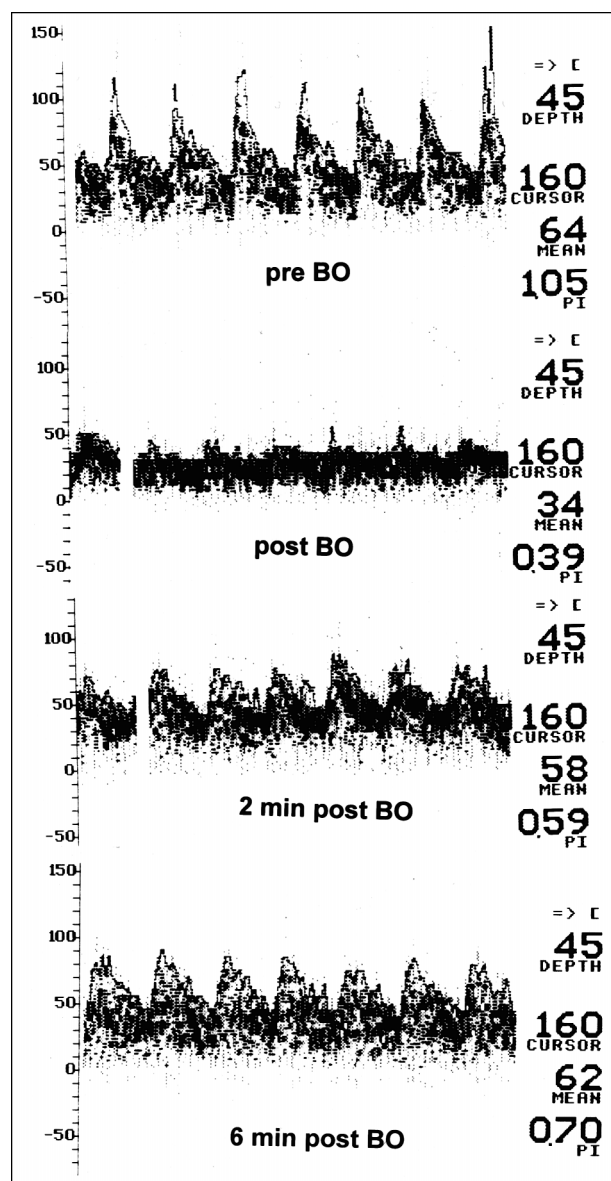


FIG 3. Delayed adaptation of MBFV and PI after therapeutic balloon occlusion (BO) of the ICA in one patient. TCD values are reduced by 47% (MBFV) and 63% (PI) immediately after the procedure. Six minutes after balloon occlusion, MBFV is nearly back to the preocclusion level. PI is finally reduced by only 33%. The patient tolerated the procedure well.

MBFV or PI reduction of between 30% and 50%. All were asymptomatic. In the eighth patient (case 31), a reduction of 30% to 50% of both MBFV and PI were seen. This patient became symptomatic 20 hours after balloon detachment. Subanalysis of the small number of patients in group 2 showed no statistical significance.

Motor vasoreactivity was analyzed for the absolute differences between MBFV stimulation before and after balloon occlusion in 25 patients (Fig 2). Both patients who had a marked decrease in response (cases 25 and 31) became symptomatic. All patients who showed improvement ($n = 17$), no change ($n = 1$), or a mild decrease ($n = 7$) remained asymptomatic, except for patient 10. Although this was found to be

significant ($P < .05$), the major variations in motor vasoreactivity among all patients weaken the result. MBFV and PI should be regarded as major TCD parameters; changes in motor vasoreactivity might prove to be an additional parameter in critical situations.

Discussion

Permanent therapeutic balloon occlusion of the ICA has become a well-established treatment option for giant aneurysms of the ICA that are not amenable to surgery (1–3) and as a last-resort treatment for extensive carotid cavernous fistulas (4). In some extensive skull base tumors, sacrifice of the ICA cannot be avoided. Although preoperative balloon occlusion under controlled conditions has proved to be less dangerous than intraoperative ligation of the ICA (9), thromboembolic complications and hemodynamic ischemia remain major risks.

To avoid thromboembolism, the procedure is performed under anticoagulation with full-dose heparin, and the detachable balloon is placed just below the origin of the ophthalmic artery. Thromboembolic complications usually occur during catheter manipulation and cause immediate neurologic symptoms. In procedures performed under general anesthesia, thromboembolic events can be detected by TCD (10). But thromboembolic stroke may also occur after balloon occlusion (1, 2). Hemodynamically induced symptoms can occur after balloon detachment even in patients who have tolerated the temporary test occlusion. These symptoms usually start within a day after balloon occlusion but may occur as much as 2 weeks later (1) and may lead to severe hemispheric infarction (3).

To avoid delayed hemodynamic infarction, supplementary techniques, such as stump pressure measurements (11) and EEG monitoring (12), have been used to predict hemodynamic intolerance. During angiography, the collateral supply via the communicating arteries of the circle of Willis can be observed, as can asymmetry in the parenchymatous and venous phase (2). These qualitative angiographic findings, however, may not serve well as quantitative thresholds for decision making in critical situations.

During the hypotension provocation test, the mean arterial pressure is lowered to half the control (pre-occlusion) level, while the patient is repeatedly examined for the appearance of any new neurologic symptoms. This hypotension provocation test alone may lead to false-negative (and positive) responses (3). In a study of 12 consecutive patients with permanent balloon occlusion, the hypotension provocation test led to false-negative results in two cases (3).

Cerebral blood flow (CBF) measurements, such as hexamethylpropyleneamine oxime single-photon emission computed tomography (SPECT) (13, 14), positron emission tomography (15), and stable xenon-enhanced CT (16–18), have been used to define absolute thresholds of hemodynamic intolerance. In stable xenon-enhanced CT, the threshold for clinical

Clinical complications after balloon occlusion

Patient	Diagnosis	MBFV Reduction, %	PI Reduction, %	Vasoreactivity before BO, %	Vasoreactivity after BO, %	Clinical Findings
1	L ICA aneurysm	54	38			Transient (2 h) R hemiparesis 90 min after BO.
10	L Skull base tumor	55	39	7	8	Transient (1 h) paresis and paraesthesia R hand, 30 min after BO.
25	L Skull base tumor	40	56	23	0	Clinical intolerance during test occlusion; BO after EC/IC bypass; hemodynamic infarction with persistent mild R hemiparesis and dysphasia after BO.
31	L ICA aneurysm	33	39	44	7	R hemiparesis and dysphasia 20 h after BO persistent over 3 days; complete recovery after EC/IC bypass, no structural deficit on CT scan; restoration of vasoreactivity after EC/IC.

Note.—BO indicates balloon occlusion; ICA, internal carotid artery.

intolerance has been defined as less than 30 mL/100 g per minute, or a drop of more than 30% in case of low baseline value. But this method led to three false-negative results among 31 patients in a recent study by Linskey et al (16) and provides low sensitivity in deep white matter or border zone regions. Expensive and time-consuming CBF measurements can only be performed as a separate measure and also demand access to the ICA twice to perform permanent balloon occlusion, leading to an increased risk of catheter complications.

TCD is a simple noninvasive method that provides permanent online monitoring of cerebral hemodynamics during the catheter procedure and the clinical tests in the angiography suite (19). This monitoring is very important in patients who are under general anesthesia (10), as TCD is also capable of registering dynamic processes, such as delayed adaptation to ICA occlusion, which occurred in some patients in the present study during the test occlusion period. If clinical angiographic and TCD results indicate that the occlusion has been tolerated, the balloon only needs to be detached to complete the procedure.

A recent study demonstrated that TCD changes in blood flow velocity generally reflect changes in CBF in stable xenon-enhanced CT during balloon test occlusion of the ICA (20). Because of the great interpersonal variability and multifactorial influences, absolute values of blood flow velocities cannot be used to define critical thresholds (21). In our study, we analyzed the percentage of MBFV and PI reduction after balloon inflation as compared with the preocclusion level. Most recent studies have focused on the reduction of MBFV. Añon et al (2) defined the critical threshold as a reduction of more than 30%. All five of their patients with a reduction of less than 30% remained asymptomatic. Five others had a reduction of more than 30%, three of whom tolerated a permanent occlusion after the application of an EC/IC bypass; the other two suffered postoperative stroke.

In a multitechnique study in which carotid test occlusion was monitored by EEG, SPECT, and TCD in 24 patients, and in which the critical threshold was

defined as an MBFV reduction of more than 40% relative to baseline values, all six patients with permanent therapeutic balloon occlusion had a reduction of less than this 40% value and none developed hemodynamic infarctions, although two suffered thromboembolic complications (14). In three patients, permanent balloon occlusion was not performed, because MBFV reduction of more than 40% correlated well with clinical, EEG, or SPECT findings during test occlusion.

In another study (22), TCD monitoring of brief occlusion during percutaneous transluminal angioplasty of the ICA revealed that an MBFV decrease of more than 50% relative to baseline values was a critical threshold for the occurrence of symptoms. With MBFV reduction of 50% or less ($n = 10$), no complications occurred. With MBFV reduction of more than 50% ($n = 12$), six patients developed neurologic symptoms (transient ischemic attacks in five, minor stroke in the other).

Other investigators (23), in a comparison of TCD monitoring during manual CCA compression with clinical tolerance to balloon test occlusion, found that 14 of 15 patients with an MBFV reduction of no more than 65% clinically tolerated the balloon occlusion test. Of the seven patients showing an MBFV decrease of more than 65%, six incurred a transient focal deficit during the occlusion. The higher threshold in manual CCA compression as compared with TCD monitoring during balloon occlusion in the carotid syphon might be explained by the lack of a collateral pathway of the ophthalmic artery. Furthermore, during short manual compression (3 to 5 seconds), delayed adaptation of flow velocity parameters such as we observed in some patients may not be detected. TCD monitoring during manual CCA compression can be performed at bedside before angiographic evaluation and may help to identify patients at risk, but it cannot replace balloon test occlusion.

Our patients with MBFV and PI reductions of 30% or less ($n = 21$) had no complications. Conversely, all patients with MBFV or PI reductions of more than 50% ($n = 3$) developed neurologic symptoms. In

patients with MBFV or PI reductions between 30% and 50% (n = 8), only one patient became symptomatic. In this patient, both parameters were reduced between 30% and 50%. In addition, motor vasoreactivity was markedly reduced after ICA occlusion.

Motor vasoreactivity varied considerably in all patients, but was significantly reduced in two symptomatic patients. So the result of the motor stimulation test may be used as an additional parameter in critical situations.

Our data correspond well with a report of a giant aneurysm in which TCD monitoring was used as a guide to graded therapeutic occlusion of the ICA by a Crutchfield clamp (24). Repeated tightening of the clamp was only tolerated if the reduction of MBFV and PI was less than 50%. If the reduction of TCD values is identified as critical, balloon occlusion cannot be achieved. EC/IC bypass might be performed before permanent ICA occlusion; however, the EC/IC bypass procedure cannot guarantee clinical tolerance. In our study, EC/IC bypass resolved clinical symptoms in one such patient after balloon occlusion but could not prevent hemodynamic infarction in the other. Fox et al (1) also reported persistent clinical intolerance in four of eight patients after EC/IC bypass. Two of these patients, however, subsequently tolerated test occlusion and permanent occlusion up to 8 months later. The two other patients could not be treated by balloon occlusion.

Conclusion

TCD monitoring offers an appropriate noninvasive method for reliably detecting changes in cerebral hemodynamics during therapeutic balloon occlusion of the ICA. In cases of mild MBFV and PI reduction (such as in our group 1), suggesting no risk of delayed ischemic intolerance, the decision in favor of detaching the balloon is sound. Severe reduction of MBFV or PI (group 3) indicates a critical threshold for the occurrence of ischemic symptoms. EC/IC bypass should be considered before permanent occlusion in such patients. In cases of moderate MBFV or PI decrease (group 2) the decision is more difficult. Vasoreactivity to motor stimulation before and after balloon occlusion can be used as an additional parameter. If either MBFV or PI is reduced between 30% and 50% and the other parameter is reduced less than 30%, there seems to be low risk, especially if appreciable motor vasoreactivity persists after balloon occlusion. However, if both the MBFV and PI values decrease between 30% and 50% and the motor vasoreactivity shows a significant drop after balloon occlusion, the risk of delayed clinical intolerance seems to be increased. In such cases, EC/IC bypass prior to definite balloon occlusion might be advisable, even though more experience is needed to substantiate such a decision.

Acknowledgment

We thank J. Knispel, Hamburg, for his language advice.

References

1. Fox JA, Vinuela F, Pelz DM et al. Use of detachable balloons for proximal artery occlusion in the treatment of unclippable cerebral aneurysms. *J Neurosurg* 1987;66:40-46
2. Añon VV, Aymard A, Gobin YP et al. Balloon occlusion of the internal carotid artery in 40 cases of giant intracavernous aneurysm: technical aspects, cerebral monitoring, and results. *Neuroradiology* 1992;34:245-251
3. Awad IA, Masaryk T, Magdinec M. Pathogenesis of subcortical hyperintense lesions on magnetic resonance imaging of the brain; observations in patients undergoing controlled therapeutic internal carotid artery occlusion. *Stroke* 1993;24:1339-1346
4. Freitag HJ, Zeumer H, Nahser HC, Kühne D. Intracranial dural fistulae. *Cerebrovasc Dis* 1992;2:145-151
5. Staudacher T, Prey N, Sonntag W, Stoeter P. Zur Grundlage der Ultraschallphänomene während der Injektion von Röntgenkontrastmittel. *Radiologe* 1990;30:124-129
6. Gosling RG, King DH. Arterial assessment by Doppler-shift ultrasound. *Proc R Soc Med* 1974;67:447-449
7. Olesen J. Contralateral focal increase of cerebral blood flow in man during arm work. *Brain* 1971;94:635-646
8. Thie A, Carvajal-Lizano M, Schlichting U, Spitzer K, Kunze K. Multimodal test of cerebrovascular reactivity in migraine: a transcranial Doppler study. *J Neurol* 1992;239:338-342
9. Gonzalez CF, Moret J. Balloon occlusion of the carotid artery prior to surgery for neck tumors. *AJNR Am J Neuroradiol* 1990;11:649-652
10. Valdueza JM, Eckert B, Zanella FE. Detection of MCA embolization during transcranial Doppler monitoring. *Neurol Res* 1994;16:137-140
11. Barker DW, Jungreis CA, Horton JA, Pentheny S, Lemley T. Balloon test occlusion of the internal carotid artery: change in stump pressure over 15 minutes and its correlation with xenon CT cerebral blood flow. *AJNR Am J Neuroradiol* 1993;14:587-590
12. Cloughesy TF, Nuwer MR, Hoch D, Vinuela F, Duckwiler G, Martin N. Monitoring carotid test occlusion with continuous EEG and clinical examination. *J Clin Neurophysiol* 1993;10:363-369
13. Petermann SB, Taylor A Jr, Hoffmann JC Jr. Improved detection of cerebral hypoperfusion with internal carotid balloon test occlusion and ^{99m}Tc-HMPAO cerebral perfusion SPECT imaging. *AJNR Am J Neuroradiol* 1991;12:1035-1041
14. Keller E, Ries F, Grünwald F et al. Multimodaler Karotisokklusionstest zur Bestimmung des Infarktrisikos vor therapeutischem Karotis-Interna-Verschluß. *Laryngorhinootologie* 1995;74:307-311
15. Brunberg JA, Frey KA, Horton JA et al. [¹⁵O]H₂O positron emission tomography determination of cerebral blood flow during balloon test occlusion of the internal carotid artery. *AJNR Am J Neuroradiol* 1994;15:725-732
16. Linskey ME, Jungreis CA, Yonas H, et al. Stroke risk after abrupt carotid artery sacrifice: accuracy of preoperative assessment with balloon test occlusion and stable xenon-enhanced CT. *AJNR Am J Neuroradiol* 1994;15:829-843
17. Witt JP, Yonas H, Jungreis C. Cerebral blood flow response pattern during balloon test occlusion of the internal carotid artery. *AJNR Am J Neuroradiol* 1994;15:847-857
18. Eskridge JM. Xenon-enhanced CT: past and present. *AJNR Am J Neuroradiol* 1994;15:845-846
19. Newell DW, Aaslid R. Transcranial Doppler: clinical and experimental uses. *Cerebrovasc Brain Metab Rev* 1992;4:122-143
20. Kofke WA, Brauer P, Policare R, Pentheny S, Barker D, Horton J. Middle cerebral artery blood flow velocity and stable xenon-enhanced computed tomographic blood flow during balloon test occlusion of the internal carotid artery. *Stroke* 1995;26:1603-1606
21. Lindegaard KF, Lundar T, Wiberg J, Sjöberg D, Aaslid R, Nornes H. Variations in the middle cerebral artery blood flow investigated with noninvasive transcranial blood velocity measurements. *Stroke* 1987;18:1025-1030
22. Eckert B, Thie A, Valdueza J, Zanella FE, Zeumer H. Transcranial Doppler monitoring during percutaneous transluminal angioplasty of the internal carotid artery. *Neuroradiology* 1997;39:229-234
23. Giller CA, Mathews D, Walker B, Purdy P, Roseland AM. Prediction of tolerance to carotid artery occlusion using transcranial Doppler ultrasound. *J Neurosurg* 1994;81:15-19
24. Giller CA, Steig P, Batjer HH, Samson D, Purdy P. Transcranial Doppler ultrasound as a guide to graded therapeutic occlusion of the carotid artery. *Neurosurgery* 1990;26:307-311