



## Discover Generics

Cost-Effective CT & MRI Contrast Agents

 FRESENIUS  
KABI

[WATCH VIDEO](#)

# AJNR

## **Telangiectatic osteosarcoma of the skull base.**

R E Whitehead, E R Melhem, J Kasznica and S Eustace

*AJNR Am J Neuroradiol* 1998, 19 (4) 754-757

<http://www.ajnr.org/content/19/4/754>

This information is current as  
of June 5, 2025.

# Telangiectatic Osteosarcoma of the Skull Base

Richard E. Whitehead, Elias R. Melhem, John Kasznica, and Stephen Eustace

**Summary:** We present a patient with a distinctive lesion of the skull base, which, at imaging, showed expansile destruction of the sphenoid bone, hemorrhage with fluid-fluid levels, and contrast enhancement of a solid portion. These features ordinarily suggest either giant cell tumor or aneurysmal bone cyst; however, pathologic examination confirmed instead a rare variant of osteosarcoma of the telangiectatic type. Although imaging findings can indicate any of these possibilities, biopsy is an essential step in arriving at the diagnosis.

Osteosarcoma of the extracranial (outside the jaws) craniofacial bones is exceedingly rare (1). Most arise *de novo*. In one series of 19 such cases from the Mayo Clinic, only six (32%) arose in the setting of prior radiotherapy or underlying Paget disease of bone (1). Telangiectatic osteosarcoma is a rare morphologic variant, constituting about 2% of all osteosarcomas (2). Typically occurring in the extremities, telangiectatic osteosarcoma of the craniofacial bones is extremely scarce in the literature. We present a case of a telangiectatic osteosarcoma arising from the sphenoid and in so doing review clinical, imaging, and pathologic features of this unusual tumor.

## Case Report

A 48-year-old man presented with a 4-week history of right temporal pain and swelling and insidious onset of blurred vision. Physical examination showed mild right proptosis and a hard nontender right temporal mass. Visual acuity on the right was diminished to 20/40.

Coronal and axial CT scans revealed a predominantly lytic, expansile lesion of the right sphenoid greater wing with a "blown-out" appearance, growing into the posterolateral orbit, compressing the optic nerve, invading the pterygoid fossa, and extending into the middle cranial fossa without definite signs of intradural spread. Small fragments of bone were visible within and around the tumor. The foramen rotundum and the lateral wall of the vidian canal were destroyed (Fig 1A–C).

MR images showed a well-circumscribed, multicystic lesion with a prominent hemorrhagic component and several fluid-fluid levels in smaller loculi posteriorly. After administration of contrast material, heterogeneous enhancement was seen within a solid portion of the tumor (Fig 1D–F).

Internal and external carotid angiography revealed an ovoid, patchily hypervascular lesion centered in the right sphenoid, deriving blood supply from branches of the middle meningeal artery, with contributions from anterior and mid-deep tempo-

ral arteries and distal internal maxillary branches. These were embolized prior to frontotemporal craniotomy and excision of the extradural intracranial portion of the mass. The pterygoid aspect of the tumor was resected via a maxillary "swing" approach.

The specimen fragments appeared grossly as tan-brown to hemorrhagic appearing soft tissue. Most of the specimen examined revealed spindle-cell proliferation with hemorrhagic areas, suggestive of a reactive fibrosis. A small, deep portion of the tissue revealed a high-grade sarcoma with large, highly pleomorphic, partly polygonal cells arranged in a pattern suggestive of septa formation with blood-filled spaces. Some of the malignant cells showed atypical mitoses. A focus of bone-forming (osteoid) matrix was also identified. These findings prompted a diagnosis of telangiectatic osteosarcoma. Immunoperoxidase studies supported the diagnosis of osteosarcoma, while studies for angiosarcoma (endothelial markers factor VIII and CD34), another differential possibility under consideration, were negative.

A bone scan 3 weeks postoperatively showed no other areas of significantly increased uptake besides the right skull base. The patient has undergone three cycles of cisplatin/doxorubicin hydrochloride chemotherapy and is to receive a course of external-beam radiation therapy. Follow-up studies showed stable disease locally 4 months after surgery.

## Discussion

Telangiectatic osteosarcoma is an unusual variant that accounts for less than 5% of osteosarcomas (2, 3). It presents with several distinctive features. Over 85% arise at or near the end of a long bone and are characterized by poorly defined destruction, a wide zone of transition, and internal fluid-fluid levels on imaging (4). Telangiectatic osteosarcoma is rapidly expansile and behaves aggressively. In the largest published series (124 cases collected between 1921 and 1979 at Memorial Sloan-Kettering), a diagnosis of telangiectatic osteosarcoma required the presence of a predominantly lytic, (greater than 90%) destructive lesion of bone with only minimal lesional sclerosis on radiographs; a soft, cystic, cavitylike tumor on gross examination; and histologically single or multiple aneurysmally dilated spaces containing blood or degenerated tumor cells lined or traversed by septa containing anaplastic sarcoma cells and numerous mitoses (4). Interestingly, in the Mayo Clinic series, presence of bone sclerosis was grounds for eliminating telangiectatic osteosarcoma from diagnostic consideration (5, 6).

Received March 12, 1997; accepted after revision June 12.

From the Department of Radiology, Boston University Medical Center, 88 E Newton St, Atrium 2, Boston, MA 02118. Address reprint requests to Richard E. Whitehead, MD, CM.

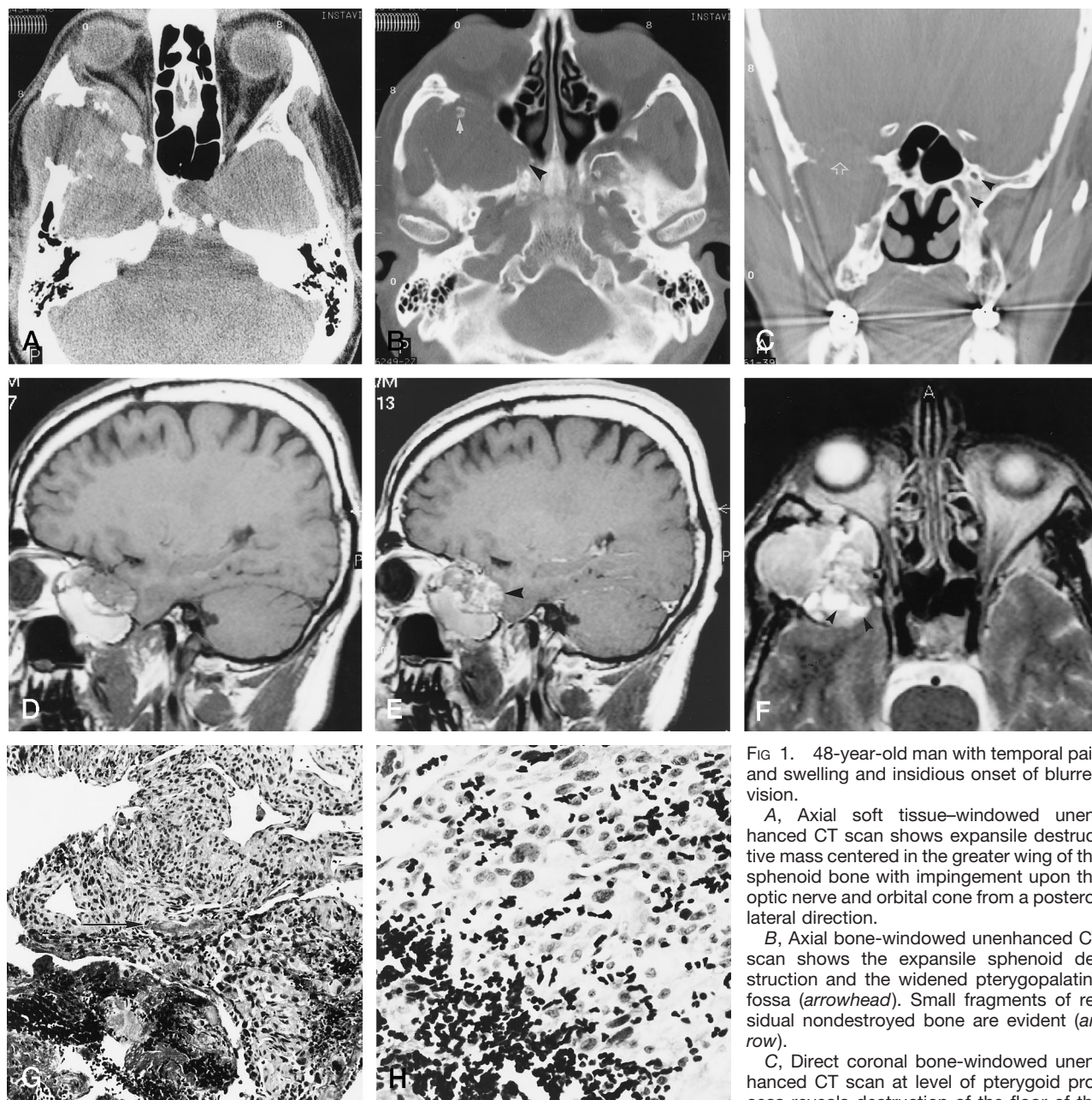


FIG 1. 48-year-old man with temporal pain and swelling and insidious onset of blurred vision.

A, Axial soft tissue-windowed unenhanced CT scan shows expansile destructive mass centered in the greater wing of the sphenoid bone with impingement upon the optic nerve and orbital cone from a posterolateral direction.

B, Axial bone-windowed unenhanced CT scan shows the expansile sphenoid destruction and the widened pterygopalatine fossa (arrowhead). Small fragments of residual nondestroyed bone are evident (arrow).

C, Direct coronal bone-windowed unenhanced CT scan at level of pterygoid process reveals destruction of the floor of the middle cranial fossa (arrow), including foramen rotundum and lateral vidian canal wall (arrowheads on normal side).

D, Sagittal T1-weighted spin-echo MR image (450/20/2) shows a circumscribed, multilocular soft-tissue mass with heterogeneous signal intensity, a solid component posterosuperiorly, and a loculus containing subacute blood inferiorly. Note the intracranial but extradural extent into the middle cranial fossa and the downward growth into the masticator space.

E, Sagittal T1-weighted contrast-enhanced spin-echo MR image (450/20/2) shows heterogeneous enhancement of the solid portion of the lesion (arrowhead).

F, Axial T2-weighted turbo spin-echo MR image (3000/90/2) shows a heterogeneous signal mass with smaller loculi posteriorly containing fluid-fluid levels (arrowheads).

G, Mid-power view of the tumor shows prominent blood spaces and septa, similar to an aneurysmal bone cyst. The highly pleomorphic neoplastic cells constituted only a very small proportion of the hemorrhagic tissue specimen, making the search for tumor especially difficult. A single focus of malignant osteoid formation is identifiable in this photomicrograph (arrow). Hematoxylin-eosin; original magnification  $\times 100$ .

H, Detail of the highly pleomorphic cells of telangiectatic osteosarcoma. Hematoxylin-eosin; original magnification  $\times 250$ .



In our case, CT scans (Fig 1A–C) documented aggressive destruction of the greater wing of the sphenoid bone. MR imaging (Fig 1D–F) was pivotal in depicting a complex lesion containing a solid, enhancing portion and several high T1-signal cystic spaces containing blood breakdown products along with small posterior loculi demonstrating fluid-fluid levels. Histologic examination of the tumor revealed highly pleomorphic cells and foci of bone matrix formation between blood-filled cystlike spaces, confirming the diagnosis of telangiectatic osteosarcoma (Fig 1G and H). Imaging features alone would also be compatible with aneurysmal bone cyst or giant cell tumor. The patient's age and the aggressive pattern of bone destruction were against the former (HP1) possibility. The histologic picture enabled confident exclusion of both. A total of six cases of aneurysmal bone cyst in the skull have been reported in the literature (7), whereas 31 giant cell tumors in the skull have been reported (8). Fluid-fluid levels have also been reported in fibrous dysplasia, simple bone cyst, and recurrent malignant fibrous histiocytoma (9), although our patient's imaging and clinical findings made these entities unlikely.

Craniofacial osteosarcoma constitutes a minority of all osteosarcomas, accounting for 8.6% of the Mayo Clinic's series of 1274 osteosarcomas (10). In the series reported by Defries et al (11), osteosarcomas accounted for less than 0.5% of all head and neck tumors. The majority of osteosarcomas about the head and neck, between 88% (12) and 75% (13), arise in the mandible and maxilla. These gnathic osteosarcomas have a clinical picture distinct from their long-bone counterparts, with low aggressiveness associated with excellent outcome if completely resected (14). At least two documented cases of telangiectatic osteosarcoma of the mandible have been reported (4, 15).

Osteosarcoma of the sphenoid bone accounts for two of a series of 19 skull osteosarcomas collected over 36 years at "La Sapienza" in Rome (16), and three of 19 Mayo Clinic cases collected over a 46-year span (17). Of the 124 cases in the Memorial Sloan-Kettering series of telangiectatic osteosarcomas, two occurred in the skull (location not further specified) (4). In no case were MR imaging features described.

Osteosarcoma is the second most common malignant primary tumor arising from bone, after myeloma (18–20). Its greatest predilection is for the metaphysis of long bones, most often the distal femur or proximal tibia. Osteosarcoma of the skull is considerably less common. Secondary osteosarcoma occurs in the setting of prior radiation therapy or of benign bone disorders, such as Paget disease, fibrous dysplasia, multiple osteochondromatosis, osteomyelitis, myositis ossificans, and trauma (21). The slightly more common primary osteosarcoma of the skull arises *de novo*. In 1993, Shinoda et al (22) reviewed 99 cases of primary osteosarcoma since the first reported case in 1945 (23). Seventeen of their cases involved both inner and outer tables without intracranial invasion. In 14 cases, intracranial invasion had occurred, two of which had subdural or intracerebral organized

chronic granulomatous hematomas and abrupt intracerebral bleeding. Treatment included a combination of chemotherapy and radiation therapy. Prognosis was variable but generally unfavorable. Parosteal osteosarcoma limited to the outer table constituted a minority of the cases but bore a favorable prognosis; its biology elsewhere in the body was of similarly low-grade malignancy (24). For the remainder, prognosis was inversely related to the degree of intracranial involvement. Local recurrence in primary osteosarcoma is a major cause of death, whereas pulmonary metastasis is more common in osteosarcoma of the long bones (22). Local control of disease in the appendicular skeleton is more often successful, whereas radical excision or amputation cannot be applied as readily in the skull.

The sphenoid bone is far more commonly affected by metastatic tumor, either by direct invasion or from an extracranial hematogenous source, than by primary tumor. Less frequent causes of destruction or abnormal radiolucency of the sphenoid bone include fibrous dysplasia, osteomyelitis, fungal or granulomatous sinusitis, aggressive pituitary adenoma, lymphoma, myeloma, and chondrosarcoma (25). The presence of fluid-fluid levels accompanying a destructive lesion altered the differential diagnosis in our case. Aneurysmal bone cyst can be indistinguishable from telangiectatic osteosarcoma, although the sphenoid is an unusual location for this tumor and it usually occurs before the age of 20 (26). Fluid-fluid levels have also been identified in giant cell tumor, often superimposed on Paget disease, although giant cell tumors of the sphenoid bone are extremely rare. A total of 31 giant cell tumors of the sphenoid bone have been reported in the literature up to 1983 (8).

## Conclusion

Telangiectatic osteosarcoma is an unusual tumor that may rarely occur in the sphenoid bone. Although imaging features are not entirely specific, telangiectatic osteosarcoma should be considered as a diagnostic possibility when either CT or MR studies show a lytic sphenoid wing lesion with internal fluid-fluid levels. Biopsy is always required to differentiate it from an atypical aneurysmal bone cyst, a giant cell tumor, or other aggressive lytic lesions.

## Acknowledgment

We thank Andrew Rosenberg and Eli Okon.

## References

1. Nora FC, Unni KK, Pritchard DJ, Dahlin DC. **Osteosarcoma of extragnathic craniofacial bones.** *Mayo Clin Proc* 1983;58:268–272
2. Klein, MJ, Kenan S, Lewis MM. **Osteosarcoma: clinical and pathological considerations.** *Orthop Clin North Am* 1989;20:327–345
3. Farr GH, Huvo AG, Marcove RC, Higinbotham NL, Foote FW Jr. **Telangiectatic osteogenic sarcoma.** *Cancer* 1974;34:1150–1158
4. Huvo AG, Rosen G, Bretsky SS, Butler A. **Telangiectatic osteogenic sarcoma.** *Cancer* 1982;49:1679–1689

5. Matsuno T, Unni KK, McLeod RA, Dahlin DC. **Telangiectatic osteogenic sarcoma.** *Cancer* 1976;38:2538-2547
6. Mervak TR, Unni KK, Pritchard DJ, McLeod RA. **Telangiectatic osteosarcoma.** *Clin Orthop* 1991;270:135-139
7. O'Brien DP, Rashad EM, Toland JA, Farrell MA, Phillips J. **Aneurysmal cyst of the frontal bone: case report and review of the literature.** *Br J Neurosurg* 1994;8:105-108
8. Bertoni F, Unni KK, Beabout JW, Ebersold MJ. **Giant cell tumor of the skull.** *Cancer* 1992;70:1124-1132
9. Davies AM, Cassar-Pullicino VN, Grimer RJ. **The incidence and significance of fluid-fluid levels on computed tomography of osseous lesions.** *Br J Radiol* 1992;65:193-198
10. Dahlin DC, Unni KK. **Bone Tumors.** 4th ed. Springfield, IL: Thomas; 1986:281-285
11. Defries CHO, Perlin CE, Liebel SA. **Treatment of osteogenic sarcoma of the mandible.** *Arch Otolaryngol Head Neck Surg* 1979;105:538-559
12. Vege DS, Borges AM, Aggrawal K, Balasubramaniam G, Parikh DM, Bhaser B. **Osteosarcoma of the craniofacial bones.** *J Craniomaxillofac Surg* 1991;19:90-93
13. Lee Y-Y, Van Tassel P, Nauert C, Raymond AK, Edeiken J. **Craniofacial osteosarcomas: plain film, CT, and MR findings in 46 cases.** *AJR Am J Roentgenol* 1988;150:1397-1402
14. Regezi JA, Zarbo RJ, McClatchey KD, Courtney RM, Crissman JD. **Osteosarcomas and chondrosarcomas of the jaws: immunohistochemical correlations.** *Oral Surg Oral Med Oral Pathol Oral Radiol Endod* 1987;64:302-307
15. Chan CW, Kung TM, Ma L. **Telangiectatic osteosarcoma of the mandible.** *Cancer* 1986;58:2110-2116
16. Salvati M, Ciappetta P, Raco A. **Osteosarcomas of the skull.** *Cancer* 1993;71:2210-2216
17. Mirra JM, Fain JS, Ward WG. **Extraskelatal telangiectatic osteosarcoma.** *Cancer* 1993;71:3014-3019
18. Edeiken J. **Roentgen Diagnosis of Disease of Bone.** 3rd ed. Baltimore, Md: Williams & Wilkins; 1981:181-223
19. Wilner D. **Radiology of Bone Tumors and Allied Disorders.** Philadelphia, Pa: Saunders; 1982:1897-2169
20. Sweet DE, Madewell JE, Ragdsdale BD. **Radiologic and pathologic analysis of solitary bone lesions, III: matrix patterns.** *Radiol Clin North Am* 1981;19:785-814
21. Salvati M, Ciappetta P, Capone R, Santoro A, Raguso M, Raco A. **Osteosarcoma of the skull in a child: case report and review of the literature.** *Childs Nerv Syst* 1993;9:437-439
22. Shinoda J, Kimura T, Funakoshi T, et al. **Primary osteosarcoma of the skull.** *J Neurooncol* 1993;17:81-88
23. Garland LH. **Osteogenic sarcoma of the skull.** *Radiology* 1945;45:45-48
24. Dahlin DC. **Pathology of osteosarcoma.** *Clin Orthop* 1975;111:23-32
25. Osborn AG. **Diagnostic Neuroradiology.** St Louis, Mo: Mosby; 1994:494-497
26. Kransdorf MJ, Sweet DE. **Aneurysmal bone cyst: concept, controversy, clinical presentation and imaging.** *AJR Am J Roentgenol* 1995;164:573-580 .