

Get Clarity On Generics

Cost-Effective CT & MRI Contrast Agents



FRESENIUS
KABI

WATCH VIDEO

AJNR

Myelopathy caused by nitrous oxide toxicity.

P J Pema, H A Horak and R H Wyatt

AJNR Am J Neuroradiol 1998, 19 (5) 894-896

<http://www.ajnr.org/content/19/5/894>

This information is current as
of August 18, 2025.

Myelopathy Caused by Nitrous Oxide Toxicity

Peter J Pema, Holli A Horak, and Robert H. Wyatt

Summary: We describe a case of myeloneuropathy resulting from nitrous oxide abuse. MR imaging of the spine revealed symmetric abnormal signal in the posterior columns of the cervical cord. Myeloneuropathy is caused by inactivation of vitamin B₁₂ by nitrous oxide. This syndrome can also be seen in patients with borderline vitamin B₁₂ deficiency who have recently been anesthetized with nitrous oxide.

Nitrous oxide is an inhaled anesthetic commonly used in dentistry; it is also used as a propellant in the food industry (eg, in whipped cream dispensers). Several reports have described the neurotoxicity of nitrous oxide after abuse by health care professionals and in others after occupational exposure (1–5). Nitrous oxide causes its harmful effects by irreversibly oxidizing the cobalt ion of cobalamin (vitamin B₁₂) from the (+) 1 to the (+) 3 valence state. In the normal state after gastrointestinal absorption, the transcobalamin-cobalamin complex is degraded and cobalamin II is released for conversion into the active forms of vitamin B₁₂, methylcobalamin, and adenosylcobalamin. Oxidation of the cobalt ion by nitrous oxide prevents methylcobalamin from acting as a coenzyme in the production of methionine and subsequently S-adenosylmethionine, which is necessary for methylation of myelin sheath phospholipids. The result is decreased myelin formation (6–8). In addition, the conversion of methylmalonyl to succinyl coenzyme A is inhibited as a result of cobalamin oxidation. Accumulation of methylmalonate and propionate may provide abnormal substrates for fatty acid synthesis, and subsequently these abnormal fatty acids may be incorporated into the myelin sheath. We describe a case of myeloneuropathy in a young man resulting from long-term nitrous oxide abuse.

Case Report

A 31-year-old man presented with a several-month history of imbalance, limb weakness, and numbness and tingling from the toes to the waist and in the hands and forearms. He sought medical attention after awakening with complete numbness from the nipples to the toes. He had been a heavy drinker for 10 years but had been abstinent for 2 years and currently was on diazepam for anxiety. The patient had abused nitrous oxide

since age 15, once per month on average. However, over the last 2 years, he had inhaled approximately 500 to 750 cartridges of nitrous oxide-filled balloons during 5- to 6-hour sessions, which had occurred two to three times per week.

Physical examination showed decreased pinprick and light touch from the waist to the toes, distal greater than proximal, as well as in the hands. Vibration sensation was diminished in the feet and ankles. Mild finger-to-nose and heel-to-shin dysmetria was found bilaterally as was mild foot drop. He exhibited ataxia, Lhermitte sign, and an equivocal Romberg sign. Motor examination was normal except for slightly decreased strength in foot dorsiflexion bilaterally. The following laboratory tests were abnormal: hemoglobin, 12.8 g/dL; hematocrit, 37%; mean corpuscular volume, 97 fL (normal, 80 to 94 fL); serum B₁₂, 127 pg/nL (normal, 200 to 900 pg/nL).

An initial MR examination (Fig 1A–E) of the cervical spine revealed increased signal within the posterior columns bilaterally with no abnormality on the pre- or postcontrast T1-weighted images. MR images of the thoracic and lumbar spine revealed no abnormality and a subsequent brain MR examination was negative. The patient was treated with B₁₂ injections and underwent counseling.

After 7 months of abstinence and a marked reduction in his symptoms, the patient again began to abuse nitrous oxide to the same extent as before. This abuse lasted 7 months, until the gas became unavailable to him. Fifteen months after the original MR examination and 2 months after the last episode of nitrous oxide abuse, MR images of the cervical spine returned to normal (Fig 1F and G).

Discussion

The end result of nitrous oxide toxicity appears to be subacute combined degeneration of the spinal cord, as described in classic vitamin B₁₂ deficiency (8–14). The posterior columns are involved (8) with loss of position and vibration senses, ataxia, broad-based gait, and, occasionally, Lhermitte sign. The corticospinal tracts may also be involved (8), leading to weakness, spasticity, urinary and fecal incontinence, hyperreflexia, clonus, and extensor plantar response. Peripheral neuropathy as evidenced by axonal degeneration with or without demyelination in peripheral nerves is also seen. In many of the cases of neurotoxicity described, the patients exhibited measurable vitamin B₁₂ deficiency (3–5, 15–17). It appears that borderline vitamin B₁₂ deficiency can be made clinically overt by the action of nitrous oxide in further limiting the amount of active vitamin B₁₂ available. Conversely, supporting the belief that co-

Received May 9, 1997; accepted after revision December 18.

From the Departments of Radiology (P.J.P.) and Neurology (H.A.H., R.H.W.), Ohio State University Medical Center, Columbus.

Address reprint requests to Peter J. Pema, MD, Department of Radiology Grant/Riverside Methodist Hospitals, 3535 Olentangy River Rd, Columbus, OH 43014.

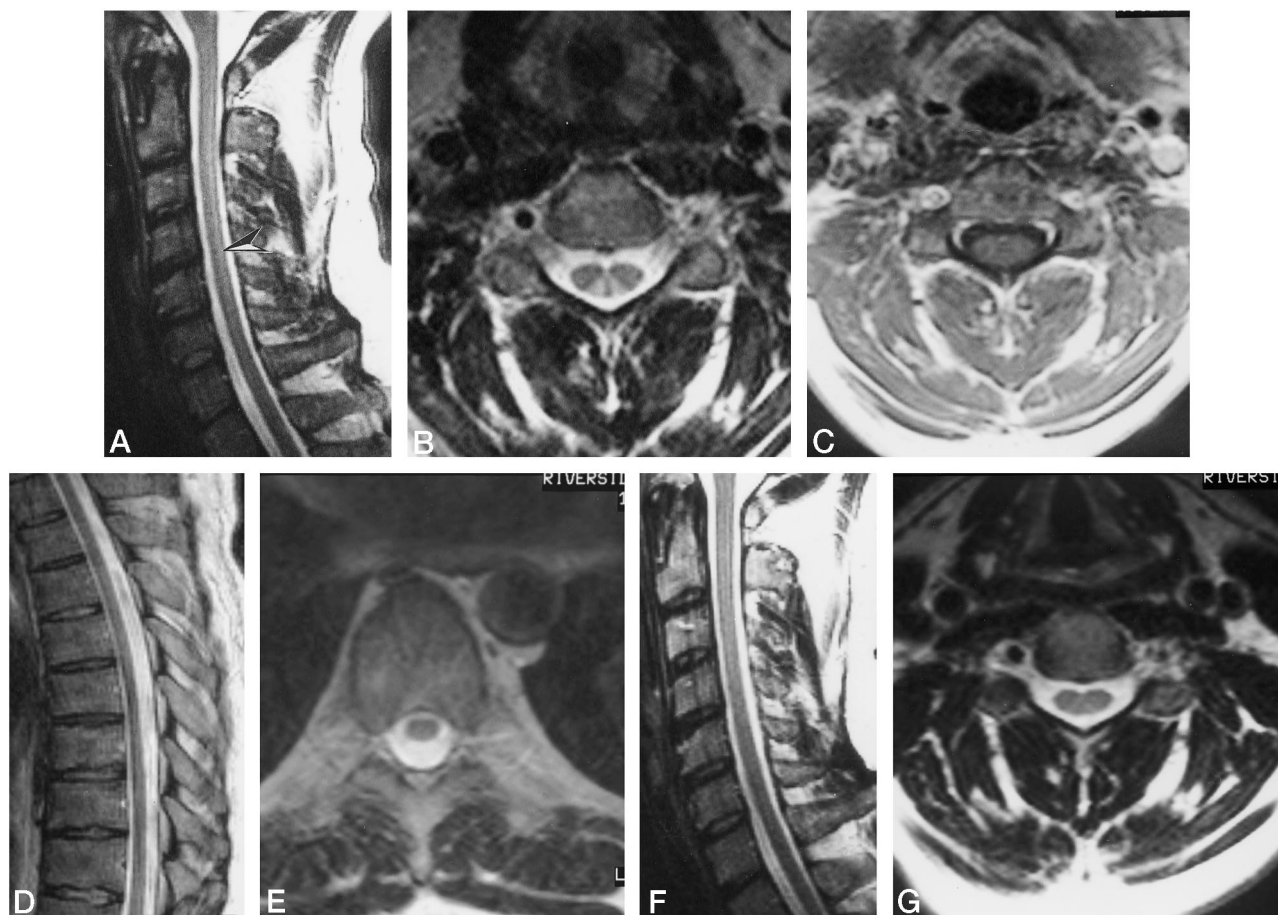


FIG 1. MR findings in a 31-year-old man with a history of nitrous oxide abuse since age 15 who presented with numbness from the nipples to the toes, imbalance, and limb weakness.

A, T2-weighted (4000/120) sagittal image shows increased signal intensity (arrowhead) in the cervical spinal cord.

B, T2-weighted (4000/120) axial image shows that the abnormal signal involves only the posterior columns. The small portion of unaffected cord in the midline posteriorly may represent the normal fasciculus cuneatus, which would explain a paucity of upper extremity findings.

C, T1-weighted (500/18) contrast-enhanced axial image is normal.

T2-weighted (4000/120) sagittal (D) and axial (E) images of the thoracic spinal cord also are normal.

F and G, MR examination 15 months later (2 months after the last episode of nitrous oxide abuse).

T2-weighted (4000/120) sagittal image (F) shows no abnormality, and the appearance of the cervical cord on the axial image (G) has returned to normal. (G is at the same axial level as B, which is approximately C4–5.)

balamin inactivation alone (despite normal levels) can lead to subacute combined degeneration, are the several reports of neurotoxicity resulting from recreational abuse of nitrous oxide in patients with normal cobalamin levels (3, 4).

Pathologically, subacute combined degeneration usually begins in the thoracic cord (11, 17) and later involves the entire cord. Several authors have reported abnormalities on MR images in the thoracic and cervical portions of the cord (10, 11, 13, 17), in the thoracic portion of the cord alone (9) (although no cervical MR examination was noted), and in the cervical region without thoracic abnormality (12, 14). It is not clear why in our case, as well as in those reported by Duprez et al (12) and Larner et al (14), the thoracic cord was normal while the cervical cord was abnormal, since, as mentioned, the process of subacute combined degeneration is thought to begin in the thoracic region. Also not explainable to date is why only the posterior columns have been reported

abnormal on MR studies, since, pathologically, the corticospinal tracts can be involved as well (8, 17).

Several investigators have reported the development of myelopathy 2 to 6 weeks after nitrous oxide anesthesia induced for a variety of surgical procedures (13, 15–18). All these patients were found to have underlying cobalamin deficiency that was unknown at the time of the procedure. Since approximately 14% of the population may have a cobalamin deficiency (8), awareness of this process is critical. In patients with postsurgical myelopathy, the physician must consider the possibility that nitrous oxide toxicity has caused an unknown underlying B₁₂ deficiency to become clinically overt. MR imaging may be helpful in suggesting the diagnosis.

Treatment for cobalamin deficiency and nitrous oxide toxicity is cobalamin and possibly methionine supplementation (6, 7). Since most symptoms improve but do not resolve completely, early diagnosis and treatment are important. Several early reports of

myelopathy resulting from nitrous oxide toxicity did not explore the associated cobalamin deficiency (1–4), and treatment was simply abstinence from nitrous oxide. However, most patients improved despite the lack of vitamin B₁₂ supplementation.

Conclusion

The patient described in this report presented with signs and symptoms of myeloneuropathy characteristic of vitamin B₁₂ or cobalamin deficiency, including sensory changes, weakness, and the Lhermitte sign. No pathogenesis for low cobalamin was found. The MR findings of abnormally increased signal intensity confined to the posterior columns of the spinal cord could be mimicked by other causes of cobalamin deficiency, spinal cord infarction in the posterior spinal artery distribution bilaterally, as well as by demyelination.

Acknowledgment

We extend our sincere thanks to Grant Arthur for his assistance in preparing the manuscript.

References

1. Sahenk Z, Mendell JR, Gouri D, Nachtman J. **Polyneuropathy from inhalation of N₂O cartridges through a whipped cream dispenser.** *Neurology* 1978;28:485–487
2. Layzer RB, Fishman RA, Schafer JA. **Neuropathy following abuse of nitrous oxide.** *Neurology* 1978;28:504–506
3. Layzer RB. **Myeloneuropathy after prolonged exposure to nitrous oxide.** *Lancet* 1978;9:1227–1230
4. Vishnubhakat SM, Beresford HR. **Reversible myeloneuropathy of nitrous oxide abuse: serial electrophysiological studies.** *Muscle Nerve* 1991;14:22–26
5. Brett A. **Myeloneuropathy from whipped cream bulbs presenting as conversion disorder.** *Aust N Z J Psychiatry* 1997;31:131–132
6. Yagiela JA. **Health hazards and nitrous oxide: a time for reappraisal.** *Anesth Prog* 1991;38:1–11
7. Louis-Ferdinand RT. **Myelotoxic, neurotoxic and reproductive adverse effects of nitrous oxide.** *Adverse Drug React Toxicol Rev* 1994;13:193–206
8. Green R, Kinsella LJ. **Current concepts in the diagnosis of cobalamin deficiency.** *Neurology* 1995;45:1435–1440
9. Murata S, Naritomi H, Sawada T. **MRI in subacute combined degeneration.** *Neuroradiology* 1994;36:408–409
10. Tajima Y, Mito Y, Owada Y, Moriwaka F, Tashiro. **MR appearance of subacute combined degeneration of the spinal cord.** *Jpn J Psychiatry Neurol* 1994;48:611–614
11. Wolansky LJ, Goldstein G, Gozo A, Lee HJ, Sills I, Chatkupt S. **Subacute combined degeneration of the spinal cord: MRI detection of preferential involvement of the posterior columns in a child.** *Pediatr Radiol* 1995;25:140–141
12. Duprez TP, Gille M, Vande Berg BC, et al. **MRI of the spine in cobalamin deficiency: the value of examining both spinal cord and bone marrow.** *Neuroradiology* 1996;38:511–516
13. Rosener M, Dichgans J. **Severe combined degeneration of the spinal cord after nitrous oxide anesthesia in a vegetarian (letter).** *J Neurol Neurosurg Psychiatry* 1996;60:354
14. Larner AJ, Zeman AZ, Allen CM, Antoun NM. **MRI appearances in subacute combined degeneration of the spinal cord due to vitamin B₁₂ deficiency (letter).** *J Neurol Neurosurg Psychiatry* 1997;62:99–100
15. Schilling RF. **Is nitrous oxide a dangerous anesthetic for vitamin B₁₂-deficient subjects?** *JAMA* 1986;255:1605–1606
16. Flippo TS, Holder WD Jr. **Neurologic degeneration associated with nitrous oxide anesthesia in patients with vitamin B₁₂ deficiency.** *Arch Surg* 1993;128:1391–1395
17. Timms SR, Cure JK, Kurent JE. **Subacute combined degeneration of the spinal cord: MR findings.** *AJNR Am J Neuroradiol* 1993;14:1224–1227

Please see the Editorial on page 994 in this issue.