



Get Clarity On Generics

Cost-Effective CT & MRI Contrast Agents



FRESENIUS
KABI

WATCH VIDEO

AJNR

Endovascular treatment of pseudoaneurysms with electrolytically detachable coils.

T E Lempert, V V Halbach, R T Higashida, C F Dowd, R W Urwin, P A Balousek and G B Hieshima

AJNR Am J Neuroradiol 1998, 19 (5) 907-911

<http://www.ajnr.org/content/19/5/907>

This information is current as
of August 17, 2025.

Endovascular Treatment of Pseudoaneurysms with Electrolytically Detachable Coils

Todd E. Lempert, Van V. Halbach, Randall T. Higashida, Christopher F. Dowd, Ross W. Urwin, Peter A. Balousek, and Grant B. Hieshima

PURPOSE: We describe the clinical presentation, angiographic findings, and clinical outcome in a group of patients with pseudoaneurysms treated by a new endovascular technique using Guglielmi electrolytically detachable platinum coils (GDCs).

METHODS: We retrospectively reviewed the angiographic and clinical findings in a series of 11 patients with pseudoaneurysms occurring in a variety of locations: seven in the cavernous carotid artery, one in the petrous carotid artery, two in the anterior cerebral artery, and one in the cervical vertebral artery.

RESULTS: All aneurysms were cured with GDC embolization. The only complication was a branch occlusion, which resolved with heparinization and produced no clinical sequelae.

CONCLUSION: Pseudoaneurysms can be safely and effectively treated by embolization with GDCs. Consideration needs to be given to the anatomic location of the pseudoaneurysm and the acuity of onset. Treatment efficacy may be improved if there are bony confines around the aneurysm or if therapy takes place in the subacute period, when the wall of the pseudoaneurysm has matured and stabilized.

Pseudoaneurysms of intracranial and neck vessels are a well-described entity. They can carry a high rate of morbidity and mortality and, depending on their location, be extremely difficult to treat by surgical means without sacrificing the parent artery. With the advent of Guglielmi electrolytically detachable coils (GDCs; Target Therapeutics, Fremont, Calif), some of these pseudoaneurysms have become amenable to treatment via an endovascular approach. We report the safety and efficacy of this technique in 11 patients with pseudoaneurysms treated with GDC embolization over the past 3 years.

Methods

Between 1994 and 1996, 11 consecutive patients with signs and symptoms of a pseudoaneurysm were referred to the neurointerventional service for diagnostic angiography and endovascular surgery. Patients' files and all angiographic studies were reviewed retrospectively.

Initial angiography was performed via a transfemoral route. Standard neuroangiographic techniques were used to acquire digital subtraction angiograms. After diagnostic angiography, patients received heparin systemically via a 5000-U bolus, and activated clotting time was measured. Additional heparin was given to achieve an activated clotting time of more than 200

seconds. Maintenance heparin was given as half the initial dose every hour. A 6F or 7F guidecatheter was positioned to permit digital roadmapping. A Tracker (Target Therapeutics) or Rapid Transit (Cordis Corp, Miami, Fla) microcatheter was navigated into the aneurysm using a 0.014-inch platinum tip microguidewire. With the tip of the microcatheter in the aneurysm, we administered a small injection of contrast material intraaneurysmally and obtained a digital subtraction angiogram to confirm the position of the microcatheter. Washers positioned on both sides of the head allowed for accurate sizing of the coils, correcting for geometric magnification.

Therapeutic occlusion of the pseudoaneurysms was achieved with GDCs. The largest coil that matched the measured size of the aneurysmal lumen was placed first. After advancing the first coil under real-time fluoroscopic and digital roadmapping guidance, we obtained a repeat angiogram via the guidecatheter to confirm proper position of the coils then electrolytically detached them. Coils of decreasing radial size were subsequently placed within the aneurysm, which was packed with as dense a coil mass as possible. After the microcatheter and guidecatheter were removed, a diagnostic catheter was repositioned and a low-magnification angiogram was obtained to exclude a branch occlusion. Additional high-magnification views were obtained in multiple planes to evaluate the post-coiling appearance of the aneurysm. Following angiography, heparin was reversed with protamine.

Illustrative Cases

Occlusion of a 6-mm Cavernous Carotid Aneurysm.—A 74-year-old man (case 5, see Table) underwent transsphenoidal surgery for a pituitary macroadenoma. During the surgery, profuse bleeding was encountered from the left carotid artery. The sella was packed with gauze and a Foley balloon was inflated in the sphenoidal sinus. An initial angiogram showed no pseudoaneurysm, but a follow-up angiogram, obtained 3

Received April 30, 1997; accepted after revision October 21.

From the Department of Radiology, Neurointerventional Section, University of California at San Francisco Medical Center, 505 Parnassus Ave, L352, San Francisco, CA 94143. Address reprint requests to Van V. Halbach, MD.

Clinical and angiographic findings in 11 patients treated for pseudoaneurysm

Case	Age/Sex	Duration of Symptoms	Clinical Findings	Treatment	Angiographic Findings	Complications	Outcome	Follow-up Results
1	57/F	1 mo	Traumatic CCF	1 GDCs 3 × 6	4-mm R cavernous ICA	None	Excellent	Angiography 5 mo, cured
2	39/M	2 w	Penetrating trauma	2 GDCs 3 × 10	3-mm branch of ACA	None	Excellent	Clinical, good
3	37/M	1 d	Traumatic CCF	3 GDCs	8-mm cavernous ICA	None	Excellent	Clinical, good
4	23/M	1 mo	Trauma	GDC 5 × 20*	8-mm horizontal ICA	Branch occlusion	Branch recanalized	Clinical, good
5	74/M	5 w	Transsphenoidal surgery	GDC T10 4 × 6*	6-mm cavernous ICA	None	Excellent	Clinical, good
6	36/M	9 mo	Trauma	4 GDCs	8-mm petrous ICA	None	Excellent	Angiography 3 mo, retreated; 6 mo, cured
7	63/M	1 mo	Transsphenoidal surgery	GDC	4-mm cavernous ICA	None	Excellent	Angiography 4 mo, cured
8	47/F	1 y	Transsphenoidal surgery	3 GDCs	10-mm cavernous ICA	None	Excellent	Angiography 12 and 17 mo, slight aneurysmal, neck filling
9	75/F	1 d	Cervical disectomy	GDC T10 4 × 8*	5-mm vertebral artery	None	Excellent	Angiography 2 d, cured
10	24/M	3 mo	Trauma	GDC T18 5 × 5	5-mm cavernous ICA	None	Excellent	Clinical, good
11	30/F	5 y	Trauma	6 GDCs	11-mm ACA	None	Excellent	Clinical, good

* Indicates the largest coil used to occlude the pseudoaneurysm.

Note.—CCF = carotid cavernous fistula; GDC = Guglielmi detachable coil; ICA = internal carotid artery; ACA = anterior cerebral artery.

weeks later when the patient reported a frontal headache, showed a pseudoaneurysm of the cavernous carotid artery. After the patient was transferred to our institution, a repeat angiogram showed that the cavernous pseudoaneurysm had undergone some moderate enlargement and now measured 6 mm (Fig 1A). A series of T10 GDCs were detached in the aneurysm, resulting in complete occlusion (Fig 1B). Clinical follow-up studies documented that the patient continued to do well.

Occlusion of an 8-mm High Petrous/Cavernous Carotid Pseudoaneurysm.—A 36-year-old race-car driver (case 6, see Table) was involved in a high-speed accident resulting in multiple injuries. Neurologically, he presented with a right-sided sixth cranial nerve palsy and complete ophthalmoplegia on the left, both of which improved. An angiogram revealed a left carotid pseudoaneurysm measuring 8 mm (Fig 2A). The patient was treated with a series of GDCs, which produced an excellent angiographic result. A 3-month follow-up angiogram showed some recanalization of the aneurysm, which was treated with additional GDC T18 and T10 coils. Six months after this retreatment, a follow-up angiogram showed complete occlusion of the aneurysm (Fig 2B). The patient continues to do well after the procedure.

Occlusion of an 8-mm Left Cavernous Pseudoaneurysm.—A 37-year-old man (case 3, see Table) sustained a gunshot wound to the face with a large-caliber handgun. A CT scan documented multiple facial fractures and soft-tissue injuries. After the trauma, the patient experienced decreased hearing in the left ear, and physical examination revealed a hemotympanum. The patient subsequently reported an acute decline in visual acuity, left ptosis, and ophthalmoplegia. An angiogram showed a direct left-sided cavernous carotid fistula (Fig 3A), which was treated with GDCs, resulting in complete occlusion. After the fistula was closed, a left-sided carotid pseudoaneurysm became more evident, measuring 8 mm (Fig 3B). This was also treated with GDCs, again with complete occlusion of the aneurysm (Fig 3C). On clinical follow-up the patient continues to do well.

Results

Data for all 11 patients in our study are summarized in the Table. In all, four women and seven men, 23 to 75 years old, were examined and treated. Delay between onset of signs and symptoms and treatment ranged from 1 day to 1 year. The pseudoaneurysms occurred in a variety of locations (seven in the cavernous carotid artery, one in the petrous carotid artery, two in the anterior cerebral artery, and one in the cervical vertebral artery) and ranged in size from 3 to 12 mm. All were classified as pseudoaneurysms because they had a definable pathogenesis related to vessel injury.

Three patients referred from outside institutions presented with inadvertent laceration of the cavernous carotid artery consequent to transsphenoidal surgery. Two of these three patients also sustained massive epistaxis. Two patients had residual pseudoaneurysms after treatment for direct carotid cavernous artery fistulas. Three patients had cavernous carotid pseudoaneurysms after head trauma stemming from rapid deceleration in motor vehicle accidents. All patients had cranial nerve palsies.

One patient incurred a vertebral artery pseudoaneurysm after anterior cervical disectomy. Two patients presented with a pseudoaneurysm of the anterior cerebral artery, one after a nail-gun injury and the other after a self-inflicted gunshot wound.

FIG 1. Case 5.

A, Initial angiogram shows a 6-mm left-sided pseudoaneurysm of the cavernous carotid artery.

B, Postembolization angiogram shows complete occlusion of the pseudoaneurysm after placement of GDCs.

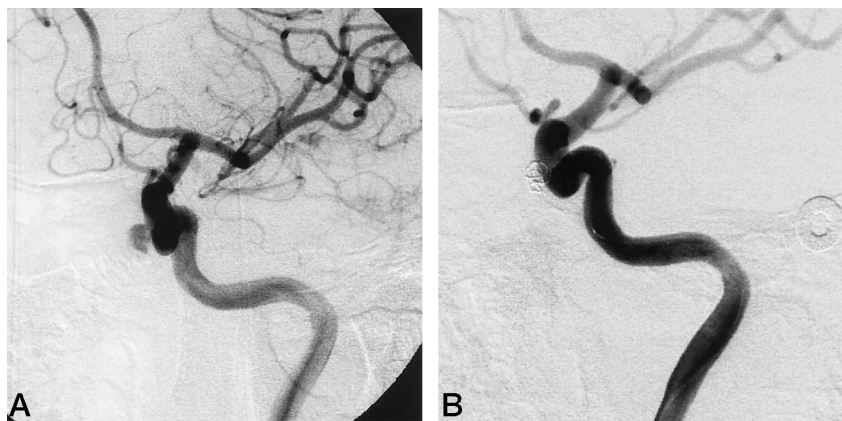


FIG 2. Case 6.

A, Cerebral angiogram shows an 8-mm pseudoaneurysm of the high petrous/low cavernous carotid artery.

B, Control angiogram 6 months after two treatments with additional GDCs shows no evidence of aneurysmal filling.

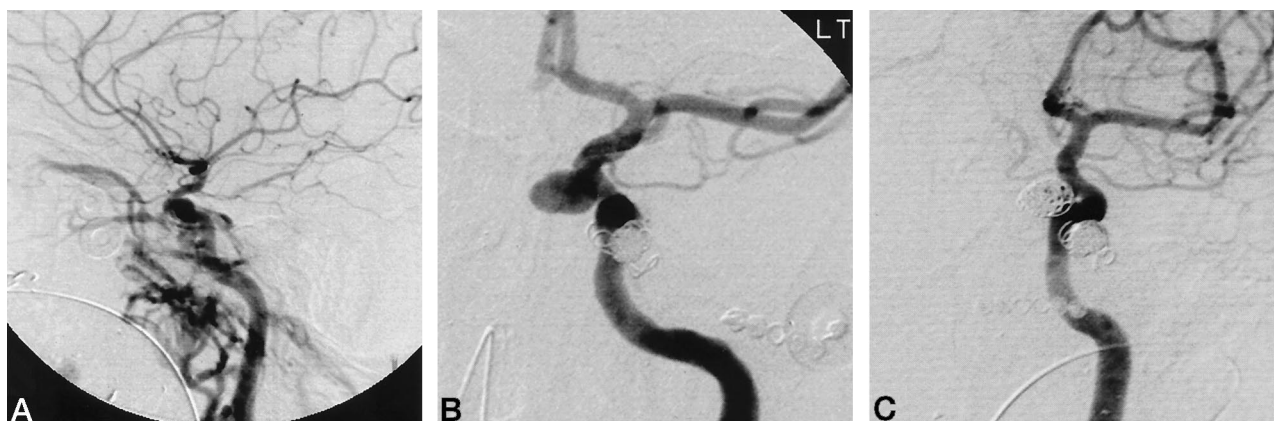
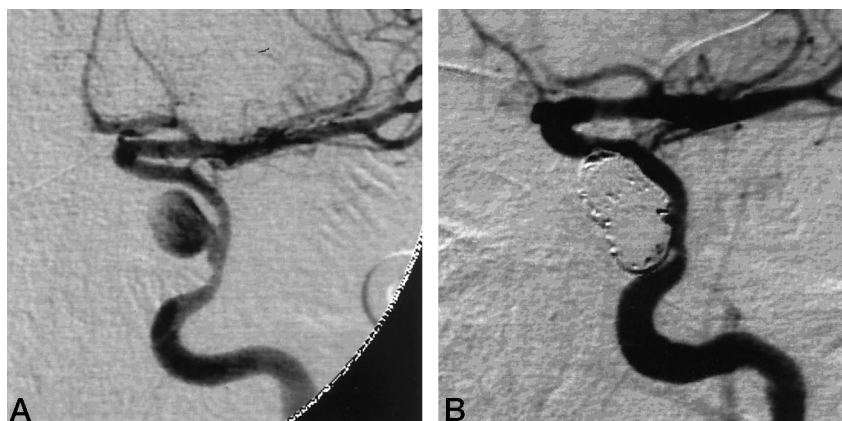


FIG 3. Case 3.

A, Cerebral angiogram shows a direct cavernous carotid fistula with drainage into the left cavernous sinus and superior ophthalmic vein.

B, After treatment of the direct cavernous carotid fistula with GDCs (note the coil mass at the site of the fistula), an 8-mm cavernous carotid pseudoaneurysm became more apparent.

C, The left cavernous pseudoaneurysm was treated with GDCs with an excellent angiographic result. Note the second coil mass at the site of the pseudoaneurysm.

The pseudoaneurysms were treated with GDC embolization, which resulted in angiographic occlusion and preservation of the parent vessel in eight of 11 cases. In case 6, in which the patient had an 8-mm high petrous pseudoaneurysm, a follow-up angiogram at 3 months showed some recanalization of the aneurysm. Retreatment consisted of placing additional GDCs, and another follow-up angiogram 3 months later showed occlusion of the aneurysm. In the other incompletely occluded aneurysm, case 8, in which the

patient had a 10-mm cavernous aneurysm, a follow-up angiogram at 1 year showed a small amount of filling of the aneurysmal neck. It was decided to defer treatment of this small neck remnant, and another follow-up angiogram 5 months later showed a minimal increase in filling of the neck remnant, which was still deemed too small for retreatment.

In case 2, in which the patient had an acute 3-mm pseudoaneurysm of a rightward callosomarginal branch of the anterior cerebral artery, the parent branch could

not be preserved and the aneurysm and the branch were occluded with coils without clinical sequelae.

In one case, a follow-up angiogram after 1 year showed some progressive narrowing of the carotid artery and some recanalization of the aneurysm. The carotid narrowing was present on the initial diagnostic angiogram and was related to direct arterial injury at the time of initial trauma. It was elected to perform carotid occlusion, which was accomplished without sequelae.

The only complication in this series occurred when treating a right cavernous pseudoaneurysm (case 4). At the end of the procedure, a single occlusion of a right frontal branch of the middle cerebral artery was noted. The patient was treated with systemic heparinization, and a repeat angiogram 1 day later showed that the vessel had recanalized. There were no clinical sequelae to this event.

Discussion

Pseudoaneurysms of head and neck or intracranial vessels have long been recognized as presenting difficult management problems. Pseudoaneurysms arise from a wide variety of conditions and events, including transsphenoidal surgery for tumor or sinus disease, penetrating or blunt trauma, primary and salvage radical neck surgery, mycotic aneurysms, vessel dissection, and diseases associated with congenital collagen deficiency.

In patients with posttraumatic pseudoaneurysms of the cavernous carotid artery, the proximity of the intracavernous internal carotid artery (ICA) to the sphenoidal sinus may account for the massive epistaxis reported in some cases. In an anatomic study performed by Renn and Rhoton (1), the carotid artery bulged into the sphenoidal sinus in 71% of cadaver specimens. The bony covering over the ICA was less than 1-mm thick in 66% of their specimens, and 4% of the specimens had no bony layer over the ICA, which instead was covered only by dura and sinus mucosa. Despite the multiplanar information available from CT and MR imaging studies, the potential for carotid injury persists when endoscopic or transsphenoidal surgical approaches are taken. A review of the otolaryngology literature shows that cavernous carotid pseudoaneurysms frequently present with massive epistaxis, and that half these hemorrhages are fatal (2, 3).

Manifestation of traumatic pseudoaneurysms may be delayed, with negative angiographic findings in the acute phase and an appearance only on follow-up examinations. In an article by Han et al (4), the latency period between injury and onset of massive epistaxis ranged from 1 week to 8 months. A large series by Chambers et al (5) showed the interval between injury and epistaxis to range from a few days to many years.

The cervical ICA can also be a site of pseudoaneurysm formation. In the carotid blowout syndrome, rupture or formation of a pseudoaneurysm occurs as a delayed complication of aggressive primary and

salvage radical neck surgery and radiation therapy. This complication carries an approximate mortality of 40% and major neurologic morbidity of 60%. Until recently, emergency surgical ligation of the common carotid artery has been the only therapeutic option. Chaloupka et al (6) describe the successful use of endovascular balloon occlusion of the carotid artery for management of this condition.

A number of techniques have been described for the management of pseudoaneurysms, including deconstructive procedures that sacrifice the carotid artery either by ligation or application of a clamp to the vessel. However, these techniques have limitations in that sacrifice of the parent vessel may not be tolerated, resulting in stroke. Additionally, proximal ligation of the vessel may allow collateral flow to fill the pseudoaneurysm, causing persistent symptoms. In one of the cases from the series by Han et al (4), massive fatal epistaxis recurred 2 days after surgical clamping of the cervical ICA.

Endovascular techniques have also been used to sacrifice the carotid artery in a controlled and selective fashion. For example, before performing permanent balloon occlusion, nondetachable balloon occlusion may be used to test the integrity of cerebral collateral circulation through the circle of Willis. Temporary balloon occlusion of the carotid artery has been performed in conjunction with a variety of clinical and other diagnostic test maneuvers to increase the positive predictive value of a negative examination. These include clinical testing of the patient's neurologic status during the test occlusion period and/or lowering of the systemic blood pressure with pharmacologic agents to unmask any hemodynamic instability that may produce symptoms when the patient is erect (7). Adjunctive tests include cerebral HMPAO single-photon emission computed tomography (SPECT), with injection of the radionuclide during the balloon test occlusion; transcranial Doppler sonographic monitoring during balloon test occlusion; and xenon CT during the period of test occlusion. The balloon test occlusion can predict with a high degree of accuracy which patients will tolerate permanent test occlusion. It has been reported that the cumulative stroke rate of abrupt carotid ligation before the advent of balloon test occlusion was 26%, whereas the stroke rate of patients who pass balloon test occlusion has been reported to be 3% (8).

Detachable balloon occlusion of the parent vessel offers the advantage of occlusion of the vessel immediately proximal to the pseudoaneurysm, reducing the chance that collateral pathways will reconstitute the aneurysm. Another advantage is the ability to effect the occlusion while the patient is awake and easily monitored for changes in the baseline neurologic examination. Balloon occlusion of the parent vessel has a low complication rate, as documented in a number of studies (7-9).

Endovascular occlusion of the parent artery with coils has also been described, achieving much the same result as balloon therapy (10, 11). Endovascular occlusion of a dissecting aneurysm of the vertebral

artery with coil occlusion of the vertebral artery has been reported by Halbach et al (12). However, there remain theoretical disadvantages to the use of coils in occlusion of parent vessels. Coils do not achieve an instantaneous occlusion the way balloons do, and slow-flowing blood across an incompletely occluded vessel could potentially be a source of emboli. Only small series have been published to date, and this issue may be resolved by further testing and some improved coil designs.

Endovascular techniques that preserve the parent artery (constructive techniques) have been described for use in the treatment of pseudoaneurysms. These involve the use of detachable balloons and coils. Treatment of the pseudoaneurysm itself in the acute phase with preservation of the parent vessel may be fraught with complications owing to the fragility of the wall of the pseudoaneurysm. Crow et al (13) described a case of massive epistaxis following balloon occlusion of an acute carotid pseudoaneurysm in which the balloon extruded through the wall of the pseudoaneurysm. Detachable coil embolization of acute pseudoaneurysms may be susceptible to the same risk of dislodgment as detachable balloons, by putting stress on the wall of an acute pseudoaneurysm.

Treatment of subacute pseudoaneurysms with detachable balloons with preservation of the parent artery has been described. Tantana et al (14) reported a case of a traumatic carotid-ophthalmic artery pseudoaneurysm treated 24 days after injury with a silicon detachable balloon, with good results (the patient remained asymptomatic at the 6-month follow-up). A large series of patients treated with balloon occlusion of intracranial aneurysms, some of which were pseudoaneurysms, was reported by Higashida et al (15).

The anatomic location and age of the pseudoaneurysm may play a part in determining the relative safety of endovascular treatment. Pseudoaneurysms that form in locations in which there is a bony confine, such as the cavernous or petrous carotid or the cervical vertebral artery surrounded by the foramina transversarium, may provide stability to a nest of coils placed in the pseudoaneurysm. Similarly, subacute pseudoaneurysms have walls that are more mature, containing fibroblasts and other elements to strengthen and encapsulate the wall. Additionally, pseudoaneurysms may contain mural thrombus, both acute and chronic, which may be somewhat friable in the acute and early subacute phases of aneurysmal formation and remodeling. A dislodged thrombus may have been the source of the branch occlusion in our case 4. With these factors in mind, we treated eight of the 11 pseudoaneurysms in the subacute phase. Each of the two cases treated within 1 day of onset had anatomic locations surrounded at least in part by bone: one was a cavernous carotid aneurysm and the other was a cervical vertebral aneurysm. Coil embolization may have a theoretical advantage over balloon embolization in this setting. Coils may absorb the hemodynamic stresses caused by pulsatile blood

flow rather than transmit the stress the way a rigid, HEMA-filled solid balloon filled with 2-hydroxyethyl-methacrylate (HEMA) might.

Conclusion

The results of this study demonstrate that selected pseudoaneurysms can be treated by GDC embolization in a safe and effective manner with a few caveats. We believe that the endovascular method of treatment is indicated in the subacute phase to take advantage of the natural pathophysiology of the developing pseudoaneurysm, in which continuous fibrotic encapsulation strengthens and stabilizes its wall. The other important consideration for treatment is the anatomic location of the aneurysm. Pseudoaneurysms occurring within the bony confines of the skull base or spine provide maximal stability for coils and help prevent their migration. Thus, acute and subacute aneurysms occurring in these locations provide another indication for safe treatment by GDC embolization.

References

1. Renn WH, Rhoton AL. **Microsurgical anatomy of the sellar region.** *J Neurosurg* 1975;43:288-298
2. Moore D, Budde RB, Hunter CR, et al. **Massive epistaxis from aneurysms of the carotid artery.** *Surg Neurol* 1979;11:115-117
3. Wang AN, Winfield JA, Gunduz G. **Traumatic internal carotid artery aneurysm with rupture into the sphenoid sinus.** *Surg Neurol* 1986;25:77-81
4. Han MH, Sung MW, Kee HC, et al. **Traumatic pseudoaneurysm of the intracavernous ICA presenting with massive epistaxis: imaging diagnosis and endovascular treatment.** *Laryngoscope* 1994; 104:370-377
5. Chambers EF, Rosenbaum AE, Norman D, et al. **Traumatic aneurysms of the cavernous internal carotid artery with secondary epistaxis.** *AJNR Am J Neuroradiol* 1981;2:405-409
6. Chaloupka JC, Putnam CM, Citardi MJ, Ross DA, Sasaki CT. **Endovascular therapy for the carotid blowout syndrome in head and neck patients: diagnostic and managerial considerations.** *AJNR Am J Neuroradiol* 1996;17:843-852
7. Standard SC, Ahuja A, Guterma LR, et al. **Balloon test occlusion of the internal carotid artery with hypotensive challenge.** *AJNR Am J Neuroradiol* 1995;16:1453-1458
8. Mathias JM, Barr JD, Jungreis CA, et al. **Temporary balloon test occlusion of the internal carotid artery: experience in 500 cases.** *AJNR Am J Neuroradiol* 1995;16:749-754
9. Fox AJ, Vinuela F, Pelz DM, et al. **Use of detachable balloons for proximal artery occlusion in the treatment of unclippable cerebral aneurysms.** *J Neurosurg* 1987;66:40-46
10. Towi F, Leiberman A, Hertzanu Y, Golcman L. **Pseudoaneurysm of the internal carotid artery secondary to tonsillectomy.** *Int J Pediatr Otorhinolaryngol* 1987;13:69-75
11. Marks MP, Chee H, Liddell RP, Steinberg GK, Panahian N, Lane B. **A mechanically detachable coil for the treatment of aneurysms and occlusion of blood vessels.** *AJNR Am J Neuroradiol* 1994;15: 821-827
12. Halbach VV, Higashida RT, Dowd CF, et al. **Endovascular treatment of vertebral artery dissections and pseudoaneurysms.** *J Neurosurg* 1993;79:183-191
13. Crow WN, Scott BA, Guinto FC, et al. **Massive epistaxis due to pseudoaneurysm treated with detachable balloons.** *Arch Otolaryngol Head Neck Surg* 1992;118:321-324
14. Tantana S, Pilla TJ, Awwad EE, Smith KR. **Balloon embolization of a traumatic carotid: ophthalmic pseudoaneurysm with control of the epistaxis and preservation of the internal carotid artery.** *AJNR Am J Neuroradiol* 1987;8:923-924
15. Higashida RT, Halbach VV, Tsai FY, et al. **Intracranial aneurysms: interventional neurovascular treatment with detachable balloons: results in 215 cases.** *Radiology* 1991;178:663-670